
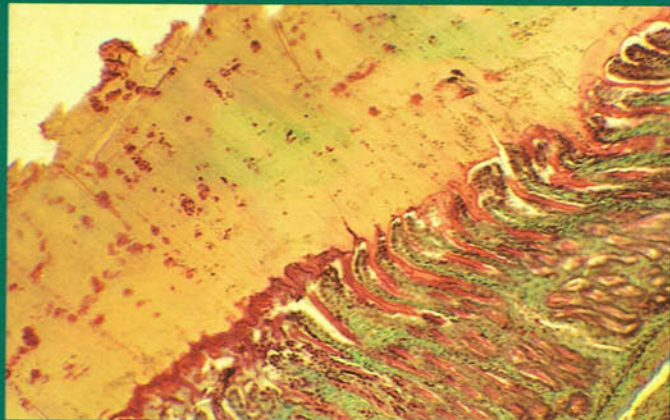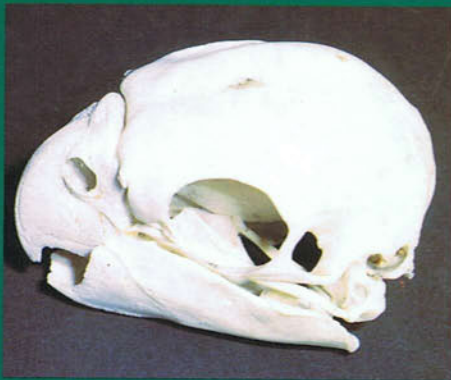

A Colour Atlas of
AVIAN ANATOMY

J. McLelland



A Colour Atlas of
Avian Anatomy

John McLelland
BVMS, MVSc, PhD, MRCVS
Reader in Veterinary Anatomy
Department of Preclinical Veterinary Sciences
University of Edinburgh
Scotland

Foreword by: Dr Julian J. Baumel

Wolfe Publishing Ltd

Copyright © John McLelland, 1990
Published by Wolfe Publishing Ltd, 1990
Printed by BPCC Hazell Books Ltd, Aylesbury, England
ISBN 0 7234 1575 7

All rights reserved. No reproduction, copy or transmission of this publication may be made without written permission.

No part of this publication may be reproduced, copied or transmitted save with written permission or in accordance with the provisions of the Copyright Act 1956 (as amended), or under the terms of any licence permitting limited copying issued by the Copyright Licensing Agency, 33-34 Alfred Place, London, WC1E 7DP.

Any person who does any unauthorised act in relation to this publication may be liable to criminal prosecution and civil claims for damages.

A CIP catalogue record for this book is available from the British Library.

This book is one of the titles in the series of Wolfe Atlases, a series that brings together the world's largest systematic published collection of diagnostic colour photographs.

For a full list of Atlases in the series, plus forthcoming titles and details of our surgical, dental and veterinary Atlases, please write to Wolfe Publishing Ltd, 2-16 Torrington Place, London WC1E 7LT, England.

Contents

Foreword	6
Preface	7
Acknowledgements	8
External features and integument	9
Skeleton	33
Digestive system	47
Urogenital system	66
Peritoneum and peritoneal cavities	85
Thorax and neck	89
Respiratory system	95
Central nervous system	120
Radiographic anatomy	121
Further reading	123
Index	124

Foreword

The focus and expertise of many of us whose research deals with avian anatomy is rather narrow. Relatively few individuals are widely knowledgeable generalists in avian anatomy.

The author of this book is one of the latter who not only has done much original research on the structure of birds, but has in his background the experience gained as the author of a number of critically acclaimed books on avian anatomy. Furthermore, as one of the principals of the International Committee on Avian Anatomical Nomenclature (ICAAAN), Dr McLelland is responsible for the development of a standardized terminology for the anatomical parts of birds.

Most anatomical illustrations are drawings, usually highly schematic. Photographic atlases have the advantage of portraying not idealized interpretations, but images of the actual structures themselves. Some photographic anatomical atlases are disappointing, their illustrations lacking definition and perspective, certainly not the case in this book. The author himself has produced an outstanding series of colour photographs that overcomes the intrinsic difficulties of photographing anatomical material. He has presented a balanced array of illustrations that not only introduce the structure of birds to novices, but are also so distinctive and fresh that they are instructive and enlightening to those of us who deal with avian morphology routinely. This atlas is indeed a worthy accomplishment and an important contribution to avian science.

Dr Julian J. Baumel,
Professor of Anatomy,
School of Medicine,
Creighton University,
Omaha, Nebraska
General Chairman of ICAAN

Preface

There is considerable interest today in birds whether as food producers, as models for biological research, or simply as objects of pleasure in aviaries and in the wild. This colour atlas provides an attractive and easily assimilated introduction to how birds are constructed. The book is aimed primarily at those engaged in university studies, veterinary practice, meat inspection and research, but it is also hoped that it will be of interest to ornithologists and bird-watchers. The book is concerned principally with the economically important species but where their anatomy significantly differs, the more common cage birds are dealt with. The choice of material is determined by the author's experience over the years in research and in university teaching at both undergraduate and postgraduate levels, and reflects the needs of veterinary surgeons as well as covering topics of general biological interest. Most of the 309 photographs are of fresh, unfixed material: 49 have been taken with the aid of a dissecting microscope. Light micrographs and scanning electron micrographs have been included when they enhance understanding. Scale bars are used only when they are thought to be of positive value. The photographs are accompanied by a short text which aims both to identify the various features and also to explain their function. For additional information the reader is directed to the 'Further reading' list at the end of the book.

The book is planned basically around certain body systems including the integument and skeleton, and the digestive, urogenital and respiratory tracts. Lymphoid tissue, blood vessels and nerves are dealt with as they occur in association with these systems. In some instances a straight topographical approach is taken, as in the description of the peritoneum and peritoneal cavities.

The names in the text of the common birds are as follows: duck, domestic forms of *Anas platyrhynchos*; goose, domestic forms of *Anser anser*; chicken, domestic forms of *Gallus gallus*; turkey, domestic forms of *Meleagris gallopavo*; quail, domestic forms of *Coturnix*; pigeon, domestic forms of *Columba livia*; Budgerigar, *Melopsittacus undulatus*; Canary, *Serinus canaria*.

Acknowledgements

I am very grateful to the following for allowing me to use their photographs: Dr M.A. Abdalla of the Department of Anatomy, Faculty of Veterinary Science, University of Khartoum, Sudan for **287**; Dr E.M. Abdel-Magied of the Department of Anatomy, Faculty of Veterinary Science, University of Khartoum, Sudan for **232**; Dr G.H.A. Borst for **302**; Mr J.E. Cooper and the Royal College of Surgeons of England and Dr J. Samour and the Zoological Society of London for **184**; Professor A.S. King and the Department of Veterinary Preclinical Sciences, University of Liverpool for **129, 130, 164, 170, 171, 183, 186, 201, 288**; Dr P.E. Lake for **202, 203**; Dr A.M. Lucas for **288, 289, 290, 304**; Dr J.N. Maina of the Department of Veterinary Anatomy, University of Nairobi, Kenya for **285**; Dr M.D. Purton of the Department of Veterinary Anatomy, University of Glasgow for **11, 18, 229, 266, 267, 297, 300**; Mr C.J. Randall of the Ministry of Agriculture, Fisheries and Food, Lasswade, Penicuik for **114, 143, 162, 166**; Dr S.E. Solomon of the Department of Veterinary Anatomy, University of Glasgow for **167, 172, 173, 176, 177, 178**; Dr M.K. Vidyadaran of the Faculty of Veterinary Medicine and Animal Science, Universiti Pertanian Malaysia, Serdang, Selangor, Malaysia for **282**.

I would like to thank the following publishers for allowing me to reproduce work in which they hold the copyright: Academic Press, London; Birkhauser Verlag, Basel; Cambridge University Press; Elsevier Science Publishers B.V., Amsterdam. I am greatly indebted to Mr and Mrs E. Denby for enabling me to take the photograph for **25** and to Fenton Barns (Scotland) Ltd, North Berwick for permission to take the photographs for **4, 22, 23** and **24**.


Almost two-thirds of the photography was performed by Fiona Manson and I am greatly indebted to her for the endless time and trouble she spent on the project. Other photographs were taken by Colin MacFarlane, Adnan Mahdi, Stephen Mitchell, Derek Penman, Kenneth Thomson and Colin Warwick to whom I express my sincere thanks. The photographs with the dissecting microscope and the remaining photomicrographs were taken by me with the skilled assistance of Gordon Goodall. I am also indebted to John Strathearn and Ian Warwick for their help in obtaining specimens.

Finally, I would like to thank the staff of Wolfe Publishing Limited for their assistance in producing this book.

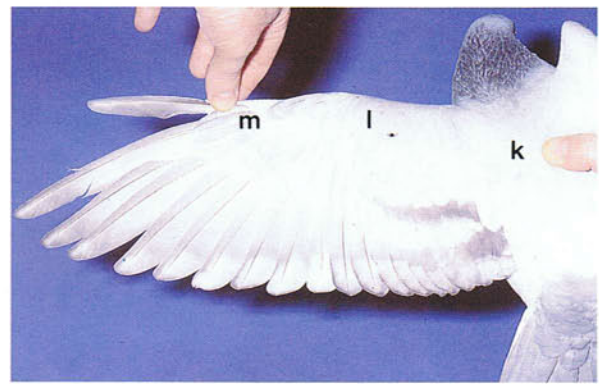
External features and integument

1-4 Regions of the body. (a) Cranium; (b) face; (c) neck; (d) back; (e) rump; (f) tail; (g) side; (h) breast; (i) belly; (j) undertail or crissum; (k) arm; (l) forearm; (m) hand; (n) thigh; (o) leg; (p) foot. (1)

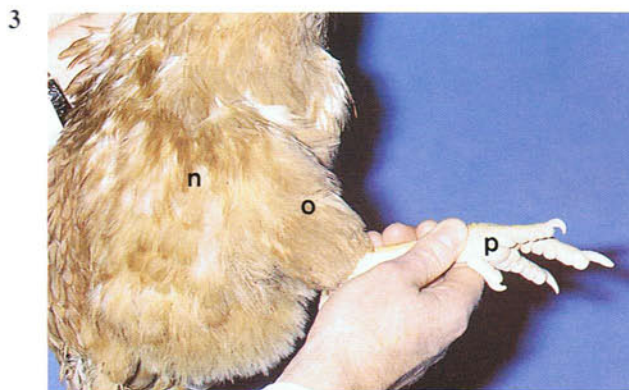
Oral region; (2) nasal region; (3) orbital region; (4) ear region; (5) forehead; (6) crown; (7) occiput; (8) chin; (9) throat; (10) cheek; (11) nape of neck; (12) jugulum.



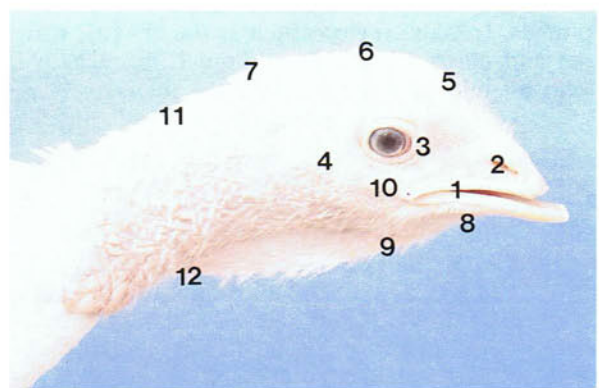
1 Adult male duck.



2 Wing of an adult pigeon.

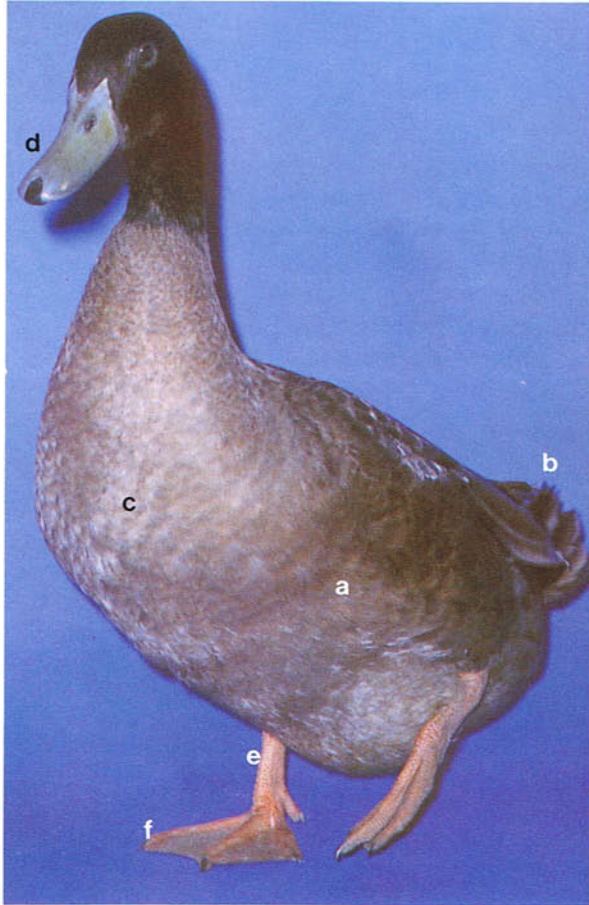


3 Leg of an adult chicken.



4 Head of an adult female turkey.

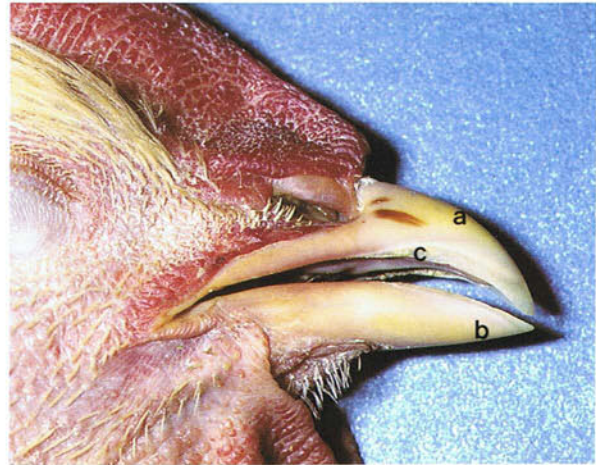5



5 External features of an adult male duck. The overall shape of the body is modified by the externally visible plumage, the contour feathers. The main types of contour feather are the flight feathers of the wing (a) and tail (b), and the general contour feathers (c) of the head, trunk and limbs. The contour feathers overlie the other feather types including the semiplumes, down feathers, bristles and filoplumes. In some regions such as the bill (d), scales (e) and claws (f) the skin is much more heavily keratinized than elsewhere and is without feathers.

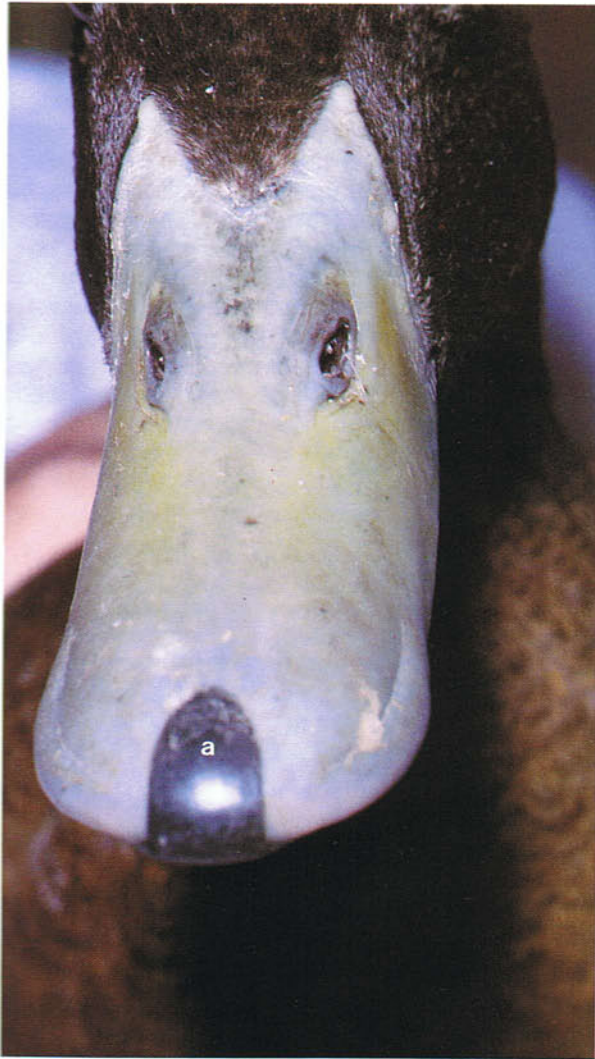7-10 Bill of a duck. Whilst the keratin covering most of the bill in the duck is soft and leathery, at the rostral end there is a hardy horny plate, the nail (a), supported by a thickened region of bone (b). With the mouth closed the upper nail lies almost at right angles to the lower nail. Running through each nail are numerous canals which open on the occlusal surface of the nail. The canals contain dermal papillae carrying mechanoreceptor nerve endings. On the bone below each nail are pits (arrow) which also contain dermis with sensory nerve end-

6



6 Beak of an adult chicken. The beak or bill includes parts of the skeleton of the upper and lower jaws and the hard horny sheaths or rhamphothecae covering them. The median dorsal border of the upper or maxillary rhamphotheca is the culmen (a). The median ventral border of the lower or mandibular rhamphotheca is the gonys (b). The cutting edges of the rhamphothecae are the tomia (c). The maxillary rhamphotheca is perforated by the paired nostrils.

ings. The upper and lower nails and their associated dermis form complex sensory organs, the upper and lower bill tip organs, which are important in the sensory discrimination of food. A well-developed bill tip organ is also present in parrots. Along the edges of the rhamphothecae in the duck are blade-like lamellae (c), one series on the inner margin of the upper bill and two series on the outer margin of the lower bill, which with the bristles (d) of the tongue are used for straining food.



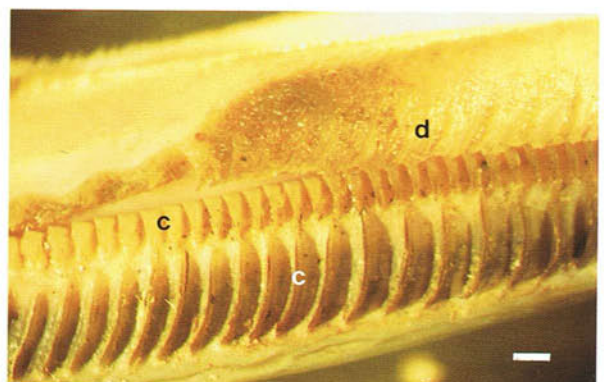
7 Upper horny bill of an adult duck.



8 Lower horny bill of an adult duck.



9 Bony part of the upper bill of an adult duck.



10 Lamellae of the lower bill of an adult duck.
(Scale, 1 mm)

11-14 Beaks. In the budgerigar the upper beak is stout, sharp-tipped and strongly curved and closes over and hides most of the small, blunt lower beak. The tips of the upper and lower beaks are composed of much harder horn than elsewhere. The sharp, pointed upper beak of psittacines may have to be blunted to prevent damage to the owner. At the base of the upper beak in the budgerigar is the swollen, sensitive cere (arrow). In young birds of both sexes the cere is a greyish-blue colour but after 3 months it usually turns blue in the cock (11) and light brown in the hen (12). However, in some coloured varieties of budgerigar, such as, lutino mutations, the appearance of the cere in the male and female is very similar and therefore sexing is not easy. Budgerigars up to the age of 3 months are sometimes called 'barheads', because the plumage

of the crown and forehead as far as the cere is crossed by distinct dark bands similar to those on the back of the head of the birds in the photographs. These marks on the crown and forehead are lost after the first moult. In the pigeon (13) there is also a cere (arrow) at the base of the beak but unlike that of the budgerigar it is white and lies behind the nostrils. The beak of the canary (14) has a conical shape typical of seed-eating passerine species. Aviculturists classify cage birds into hardbills which include canaries, budgerigars and most parrots, and softbills which include mynahs, starlings and thrushes. The beak plays an important part in prehension and in the physical preparation of food, and in some species such as parrots it is even used as an aid to locomotion.

11



11 Beak of a male budgerigar.

12



12 Beak of a female budgerigar.

13



13 Beak of a pigeon.

14



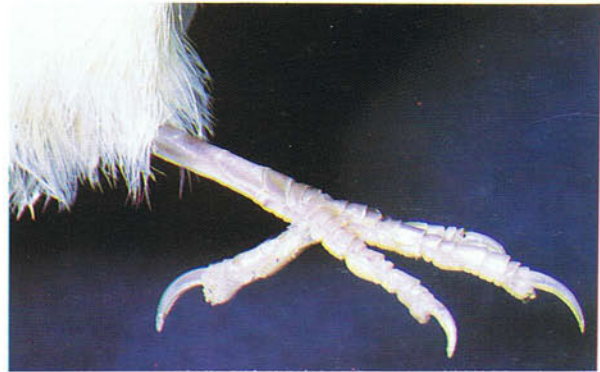14 Beak of a canary.

15 Egg tooth of a day-old chicken. The egg tooth (arrow) is a conical protuberance of hard keratin which develops before hatching and assists the chick in pipping or breaking out of the shell. After hatching it is lost within 1-2 days. The shape of the beak in chicks of different species is remarkably similar, despite the fact that the adult beak shows such a wide interspecific variation in its appearance.



15

16-18 Feet. The foot of most avian species like that of the canary and duck has four toes, three toes pointing forwards and one toe (digit I) pointing backwards. This arrangement in the canary is an adaptation for perching. In ducks the three forward-pointing toes are webbed for swimming. The foot of the budgerigar and parrots has two toes (digits II and III) pointing forwards and two toes (digits I and IV) pointing backwards and is an adaptation for climbing and grasping. The terminal phalanges are enclosed by the claws which, in caged birds, are sometimes not subjected to the normal wear and may therefore have to be clipped. Clipping the claw is also carried out to obtain a blood sample.

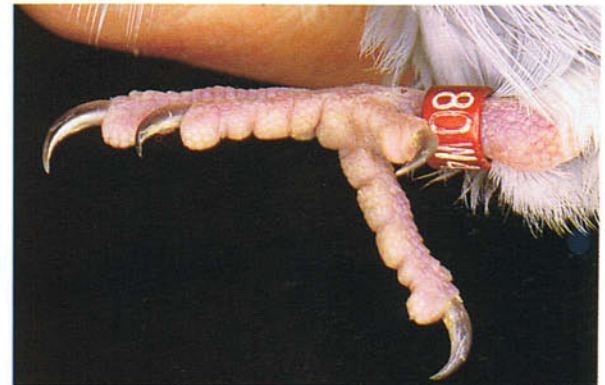

16

16 Foot of a canary.



17



18

18 Foot of a budgerigar.

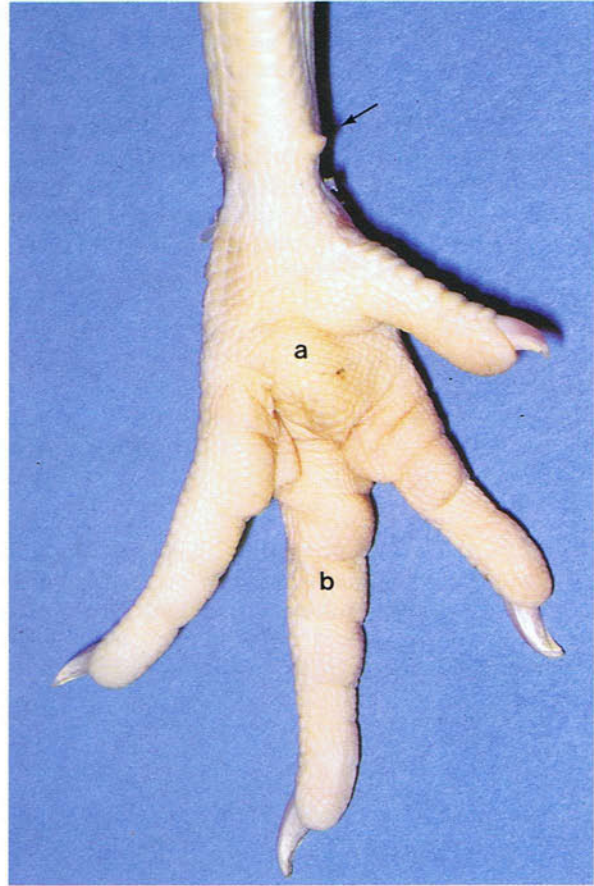
17 Foot of a duck.

19

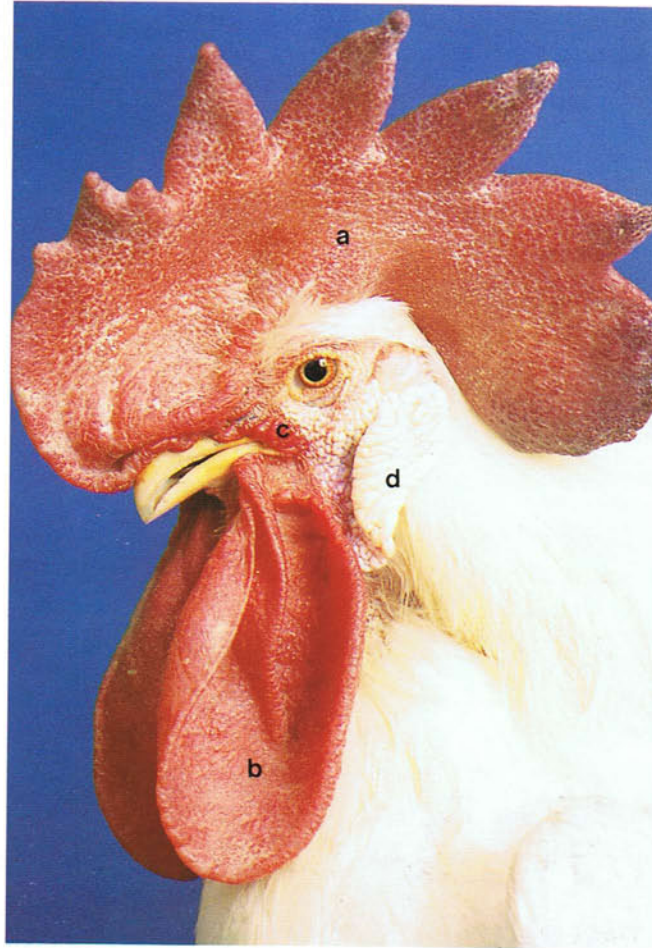


19 Foot of an adult male chicken. Dorsal view. The chicken has a typical avian foot with three toes pointing forwards and one toe pointing backwards. On the caudomedial surface of the tarsometatarsal region of the male chicken, pheasant, grouse and turkey is a well-developed heavily keratinized spur (arrow) with a bony base (see **101**). The spur grows by about 1 cm every year until a maximum length of approximately 6 cm is reached. A cock's spur should be kept trimmed to a length of about 13 mm to avoid damage to the hens during mating. The spur is usually very small or absent in females (**20**).

20



20 Foot of an adult female chicken. Plantar view. The joints of the foot are supported on their plantar surfaces by elevated pads consisting of thickened skin covering a core of subcutaneous adipose tissue. In the chicken there is a single metatarsal pad (a) at the metatarsophalangeal joints and several digital pads (b) on each of the main digits. The spur (arrow) in the female is very reduced. In the slaughter plant the feet are cut off anywhere in the tarsometatarsal region, although in some countries they are removed at the hock joint.



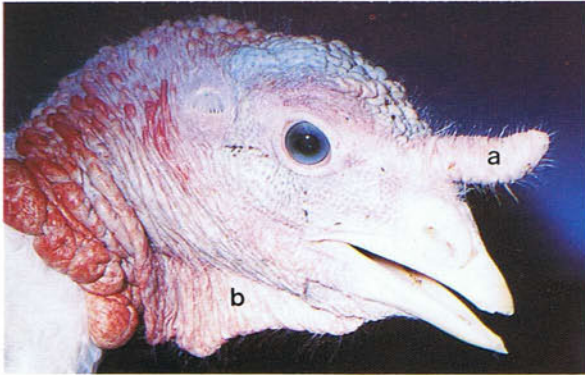
21 Ornamental appendages on the head of an adult male chicken. Ornamental appendages are especially well-developed in male birds and include the comb (a), wattles (b) and ricti (c). They are distensible structures characterized by a very thickened and vascular dermis containing numerous arteriovenous anastomoses. The colour of the comb may be used to ascertain the well-being of a bird. A bright red, full comb is a clear indication of onset of lay in a pullet. In the poultry slaughter plant the

comb reflex is used to determine if a bird is conscious or not. Dubbing or removal of the comb in day-old chicks is sometimes carried out to avoid traumatization or frostbite. The wattles may also be cropped in chicks to avoid frostbite. The edges of the wattles are sometimes used as a site for intradermal injections. The lobes (d) hang down below the external ear openings and are either red or white depending upon their vascularity.

22-24 Ornamental appendages on the head of the adult male turkey. The snood or frontal process (a) of the adult male turkey is extensible like the comb of the chicken, its size varying with the emotional state of the bird. Unlike the comb, however, the dermis of the snood has much smooth muscle but no erectile tissue. Removal of the snood or desnooding is carried out in chicks to prevent traumatization. A dewlap (b) arises from the region of the

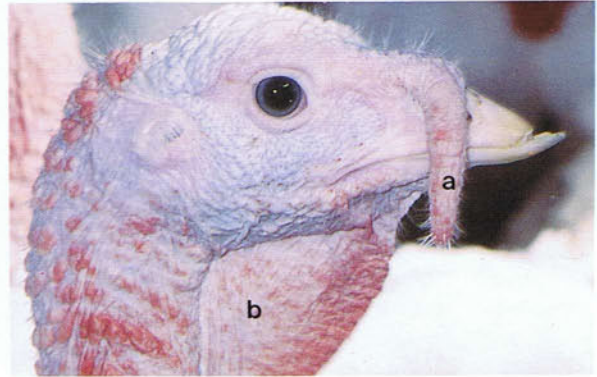
throat. The head (c) and upper neck (d) skin of the turkey is carunculate. In intensively raised turkeys and chickens, part of the upper beak is usually cut off as in the photographs to prevent feather pecking and cannibalism. Because the beak is richly innervated, it should not be trimmed more than one-third of the distance from the tip to the nostrils.

22



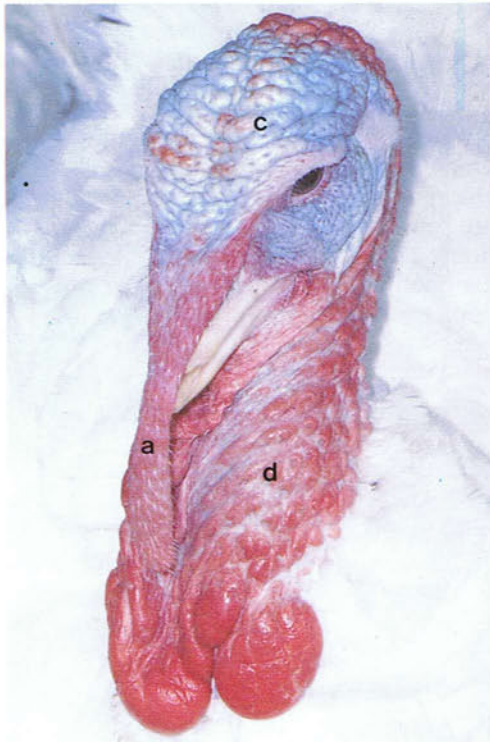
22 Head of an adult male turkey.

23



23 Head of an adult male turkey.

24



24 Head of an adult male turkey.

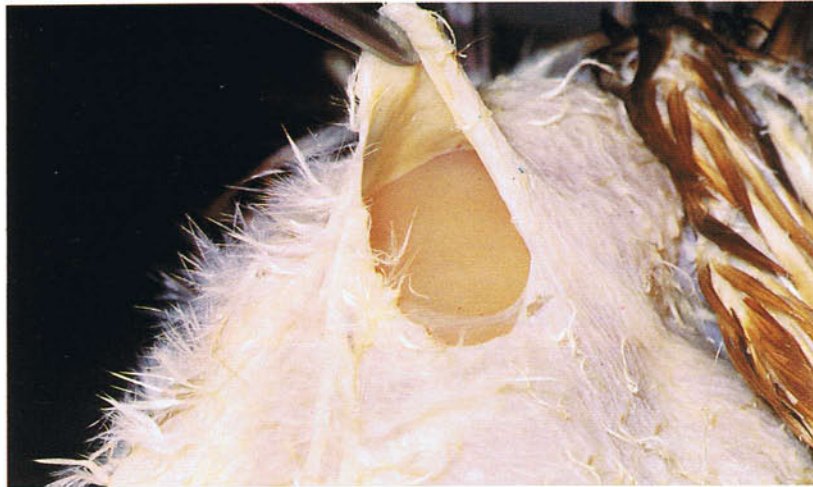25



25 Prevention of cannibalism in a pheasant. Methods other than debeaking are sometimes used to prevent cannibalism. In pheasants, for example, a plas-

tic 'bit' which extends below the palate from one nostril to the other may be used. The size of the 'bit' is adjusted as the bird grows.

26

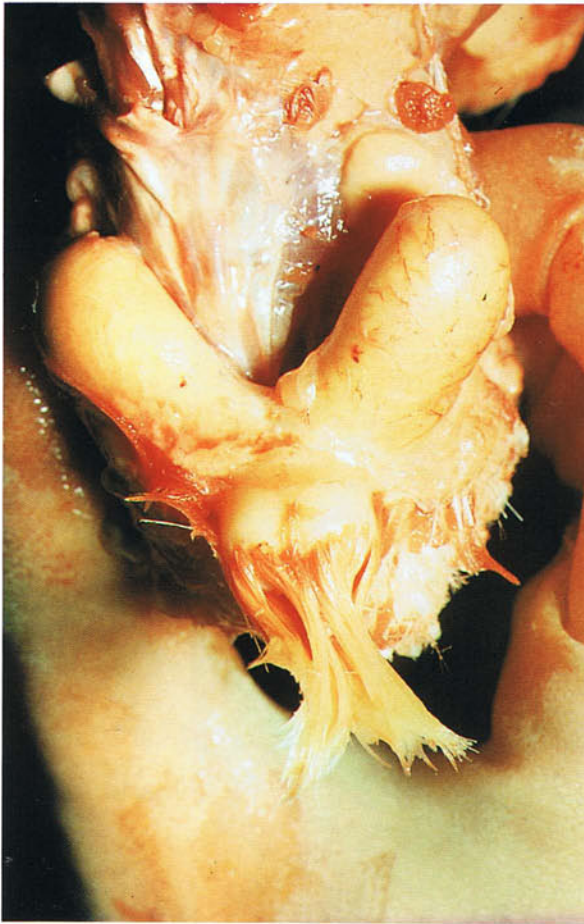

26 Skin of the breast region of an adult chicken. Except in obviously horny sites the skin of birds is thin, dry and white to yellowish-pink in colour. It also appears to be relatively avascular compared to the skin of mammals, because it does not bleed as profusely if cut. However, because the skin is only loosely attached to the underlying musculature, any bleeding which does occur can extend under the skin for considerable distances and result in unsightly bruises. In the poultry slaughter plant these blemished areas have to be trimmed away from the carcass. The subcutaneous layer contains fat which may be abundant, and striated muscle which acts to regulate the tension of the skin. Because the skin is relatively inelastic, subcutaneous injections are often accompanied by leakage of the injection fluid

through the puncture point of the needle. The best sites for subcutaneous injections appear to be the dorsal side of the base of the neck, the breast region and the groin.

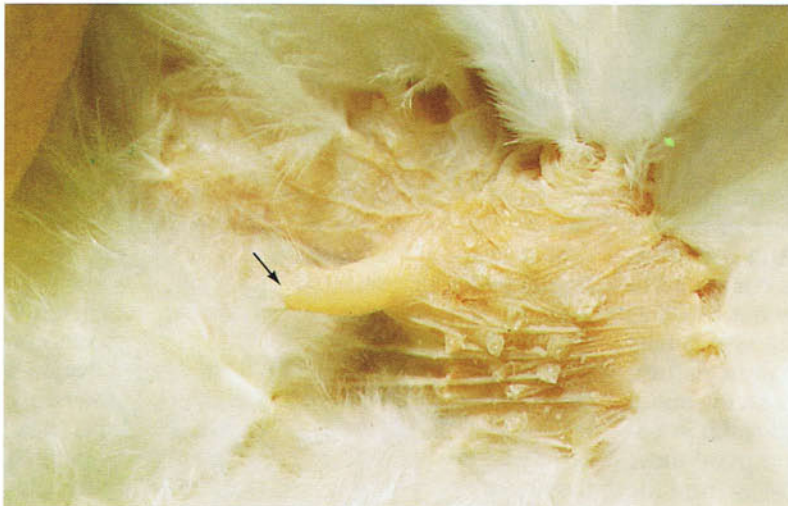In most species the skin in the breast region is modified during brooding to form an incubation (brood) patch or patches. Here the dermis becomes thickened and very vascular and the feathers are lost. At these areas the body heat of the bird is transferred to the incubating eggs. Incubation patches may occur only in one sex (generally the female) but in some species, including the pigeon, they develop in both sexes. They are absent in ducks and geese: they keep their eggs warm in the nest by covering them with plucked down feathers.

27



27 Uropygial gland of an adult duck. The bilobed uropygial gland or preen gland is the main skin gland of birds (there are no sweat glands and only a few sparsely distributed sebaceous glands) and lies dorsal to the caudal vertebrae near the tip of the tail (see also 267). Its holocrine sebaceous secretion, sebum, is smeared over the feathers during preening, and by forming a film of fat helps to keep the feathers waterproof and to prevent their keratin drying out and becoming brittle. Sebum also inhibits the growth of micro-organisms so that skin infections in birds are relatively rare. In addition to the preen gland, sebum is also secreted by the epidermal cells of the skin. The uropygial gland is well-developed in the duck and budgerigar but is absent in many parrots and in some strains of domestic pigeons.

28



28 Uropygial gland papilla in an adult chicken. The ducts of the uropygial gland open on a median nipple-like papilla (arrow) which is situated dorsally near the tip of the tail.


29 and 30 Contour feathers. The contour feathers give the body its form and can be divided into general feathers of the head, trunk and limbs, and flight feathers. The shaft of a contour feather is composed of the calamus or quill (a) which is implanted in the feather follicle, and the rachis (b). On either side of the rachis is a row of fine branches, the barbs (c), which together form a vane (d). Arising from the barbs are branches, the barbules. The barbules in the distal part of the general contour feather and over most of the flight feather are hooked together

so that each vane is flat and firm. In the proximal parts of the feathers the barbules are not hooked together so that the vanes are fluffy. Contour feathers form an almost continuous insulating layer and help to maintain the high body temperature of 105-107°F (40-41°C). They are also important in flight, in display during fighting and courtship, and as nest material. In waterbirds contour feathers trap air and enable the bird to float by maintaining buoyancy.

29 General contour feather of an adult chicken.



29




30

30 Flight feather of an adult chicken.

31 and 32 Calamus and feather follicle. At the tip of the calamus is an opening, the proximal umbilicus (a). The proximal part of the calamus lies in a tubular invagination of the skin called the follicle (b). Projecting for a short distance through the proximal umbilicus is the dermis at the base of the follicle, which becomes continuous in the cavity of the calamus with a small mound of pulp called the dermal papilla. Covering this very vascular papilla are live epidermal cells which after moulting give rise, along with the cells at the base of the follicle,

to the next feather. The calamus is hollow and translucent and is divided into chambers by epidermal partitions, the pulp caps (arrow). Attaching at each end by elastic tendons to the sides of the follicles of the contour and other feather types, are smooth muscle bundles which are responsible for feather fluffing to conserve heat. Because the muscles often form extensive parallelogram-like networks, wide groups of feathers can be acted on at the same time.

31



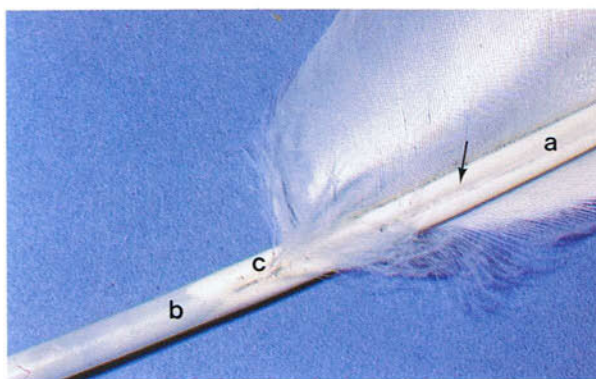
31 Calamus of a contour feather of an adult chicken.

32



32 Embedded part of a contour feather of an adult chicken.

33

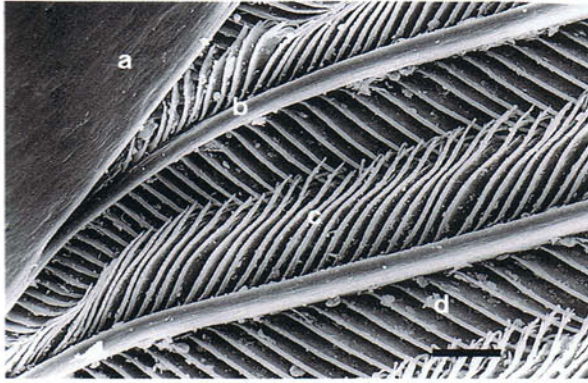


33 Undersurface of the flight feather of an adult chicken. At the junction of the rachis (a) and calamus (b) a groove (arrow) on the surface of the shaft terminates in an opening (c) called the distal umbilicus. The distal umbilicus communicates with the cavity of the calamus. There is often a small after feather (53) attached to the rim of the distal umbilicus.

34 and 35 Vane of a flight feather. The rachis (a), gives off on each side at about 45° to the main shaft a series of stiff branches, the barbs (b). Arising from the barbs at about 45° are finer branches, the barbules (c,d). The barbules of adjacent barbs cross each other at 90°. The distal barbules (c) are directed towards the free tip of the feather and

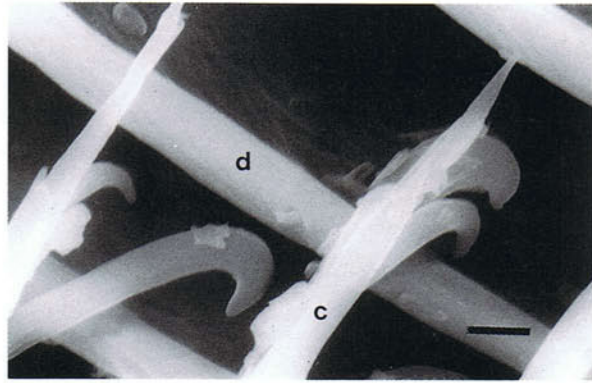
carry hooks. They interlock with the proximal barbules (d) which are directed towards the attached end of the feather. In this manner a firm and flat vane is formed. If the barbules are unhooked when the vane is split, the bird re-engages them during preening by pulling the vane through its beak in a direction parallel to the barbs.

34



34 Scanning electron micrograph of the vane of a chicken flight feather. (Scale, 100 μm .)

35

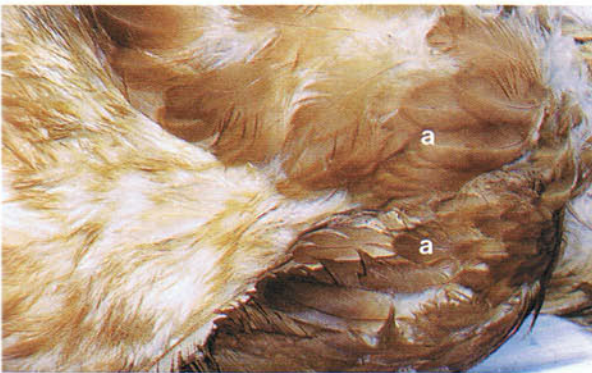


35 Scanning electron micrograph of the vane of a chicken flight feather. (Scale, 5 μm .)

36 and 37 Pterylosis. Contour feathers are not evenly distributed over the body but are arranged in tracts called pterylae which are separated by relatively bare spaces or apteria. The arrangement of the pterylae is characteristic for each species. Within the apteria are usually down feathers and semiplumes. Figure 36 shows two pterylae (a) in

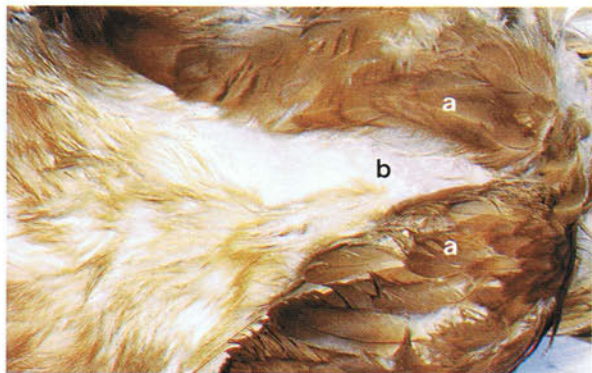
the breast region, the feathers of which in 37 have been pushed aside to reveal an apterium (b). Within the dermis of apteria are smooth muscle bundles which tense the skin. Whenever possible surgical incisions should be made in apteria rather than in pterylae.

36



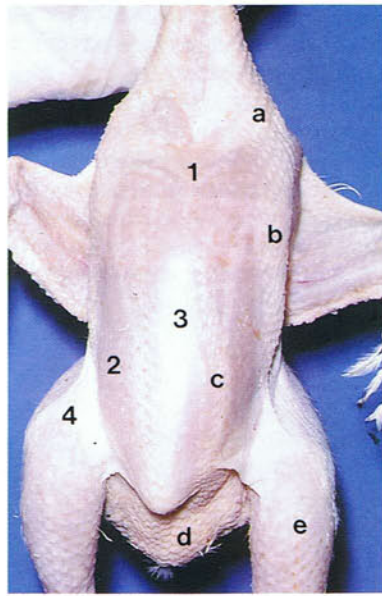
36 Pterylosis of an adult chicken.

37



37 Pterylosis of an adult chicken.

38

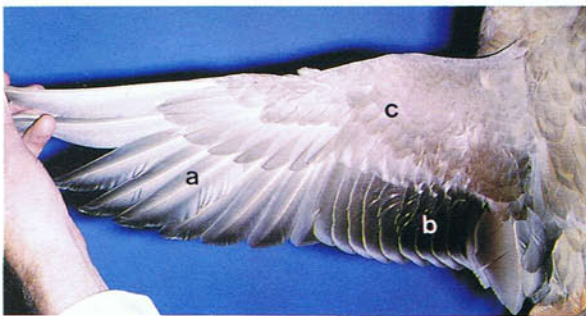


38 Pterylosis of a plucked 8-week-old chicken. Ventral view. In the chicken there are about 70 named pterylae or tracts: (a) ventral cervical tract; (b) pectoral tract; (c) sternal tract; (d) abdominal tract; (e) crural tract. (1) Ventral cervical apterium; (2) pectoral apterium; (3) sternal apterium; (4) crural apterium.

39 and 40 Wing feathers of an adult duck. The feathers of the wing consist of flight feathers or remiges and coverts or tectrices. The remiges are either primary feathers (a) attaching to the metacarpal and phalangeal bones or secondary feathers (b) attaching to the ulna. In the duck there are 10 well-developed primary remiges which are numbered in a medial to lateral direction and 18 secondary remiges which are numbered in a lateral to medial direction. All the remiges overlap in the same way, the trailing edge of one feather being overlain by the leading edge of the next feather. Because the bases of the primary and secondary feathers are interconnected by the elastic interremigial ligament, the unfolding of the remiges is coordinated. All the secondary feathers and the inner primaries are relatively movable. The outer

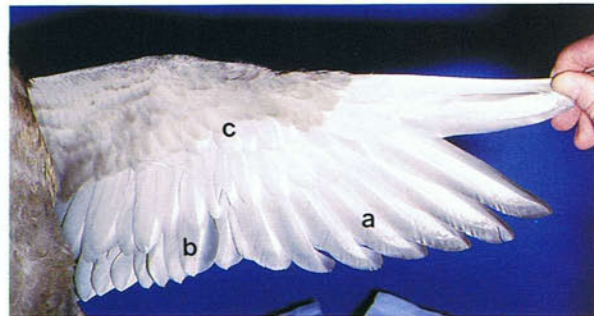
primaries, in contrast, are more firmly fixed. In many species a gap or diastema is present in the secondaries. The flight feathers are covered proximally by rows of wing coverts (c). To prevent escape in parrots and other large cage birds or to reduce the mobility of an aggressive cock during the breeding period, trimming of the flight feathers in one wing is recommended. Usually all the primary and secondary feathers are cut except the outermost two and the innermost three. For cosmetic reasons the cut is made just below the level of the coverts, so that the trimmed ends of the feathers are not seen. With one wing trimmed in this way the bird is unbalanced and cannot maintain height. Because the feathers will be replaced at the next moult, trimming has to be done annually.

39



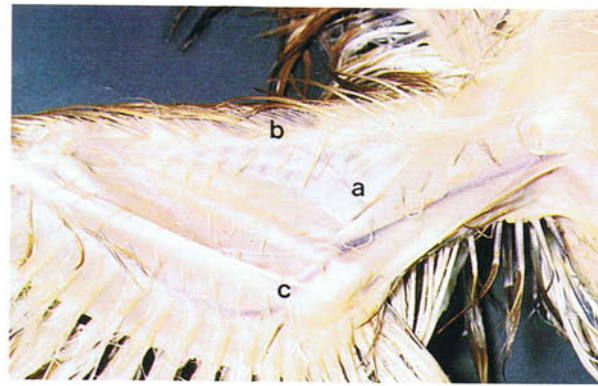
39 Wing feathers of an adult duck. Dorsal view.

40



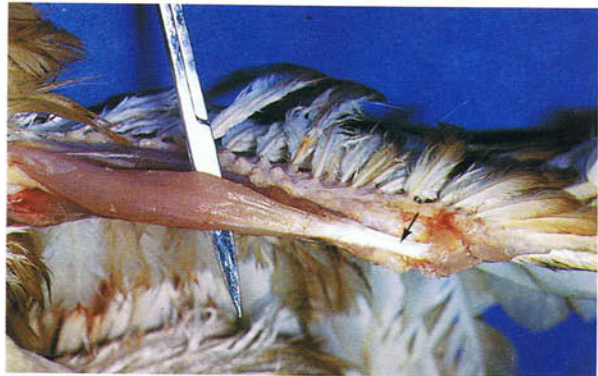40 Wing feathers of an adult duck. Ventral view.

41 Leading edge of a chicken wing. Ventral view. The triangular fold of skin that forms the leading edge of the wing between the shoulder and carpal joints is the propatagium (a). In its cranial border is the elastic propatagial ligament (b). The propatagium serves to increase the surface area of the wing and is acted on by a number of muscles. Removal of a triangular portion of the propatagium has sometimes been carried out to make cage birds flightless. In the ringing of ducks wing clips may be attached to the propatagium. The ulnar vein (c) is frequently used for intravenous injections. Other veins which can be used for injections are shown in 100, 229 and 230.



41

42 Extensor carpi radialis tendon of an adult chicken. The short tendon (arrow) of the extensor carpi radialis muscle stretches across the cranial surface of the carpal joint and is sometimes cut in one wing to prevent a bird from flying.



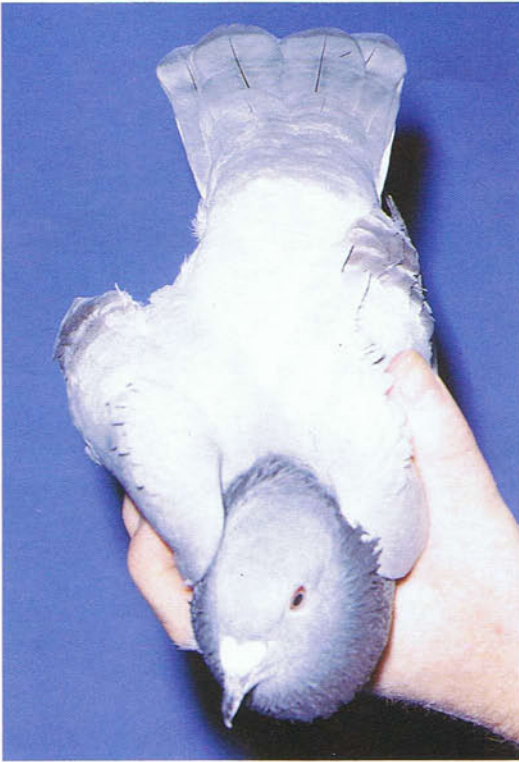42

43 Alula or bastard wing of a budgerigar: (a) feathers of alula; (b) primary flight feathers; (c) secondary flight feathers; (d) coverts. The alular digit in the budgerigar carries four feathers (between two and seven in birds generally) which form the alula. The alula when pulled forward gives rise to a slot which ensures that a smooth stream of air is present on the upper surface of the wing for lift when the bird's speed falls too low or the angle of attack is raised above 20°.



43

44




44 Flight feathers of the tail of an adult pigeon. The flight feathers of the tail, the rectrices, are always bilaterally paired. In the pigeon there are six feathers on each side. The rectrices are covered dorsally and ventrally by small tail coverts. Because of the free nature of the caudal vertebrae (see 79), the tail is very movable and assists the wing in steering and braking, as well as being important when depressed and spread at low speeds as an additional wing area.

45



45 Semiplume of an adult chicken. The vane is fluffy and the rachis is longer than the longest barb. Semiplumes occur along the margins of the contour feather tracts and singly within the tracts. They are hidden by the contour feathers and assist in insulating the body.

46



46 Structure of a semiplume of an adult chicken. Originating from the long rachis (a) are barbs (b), each barb giving rise to barbules (c). The barbules are not hooked together so that the vane is fluffy. (Scale, 5 mm)

47



47 Adult down feather of a chicken. The vane is fluffy and the rachis is either absent or shorter than the longest barb. Adult down feathers may be restricted to apteria, as in chickens, evenly distributed over the body as in ducks and parrots, or sparsely distributed in apteria or entirely absent as in pigeons and passerines. Down feathers have a thermoregulatory function and in waterbirds they assist contour feathers in trapping air and maintaining buoy-


ancy. Another type of down feather which occurs in some species, including parrots and pigeons (but not chickens), is the powder down feather which liberates a white waxy powder of keratin granules. The granules probably play a part in water-proofing the contour feathers. Because of their abundance in ducks, down and other fine feathers are removed in the poultry slaughter plant by a waxing process.

48 Natal down of a day-old chick. In newly-hatched chickens and ducks the down forms a dense layer over the whole body, but in pigeons and passerines it is restricted to the contour feather tracts. Natal down feathers differ from adult down feathers in generally lacking barbules on the tips of the central barbs.



48

49

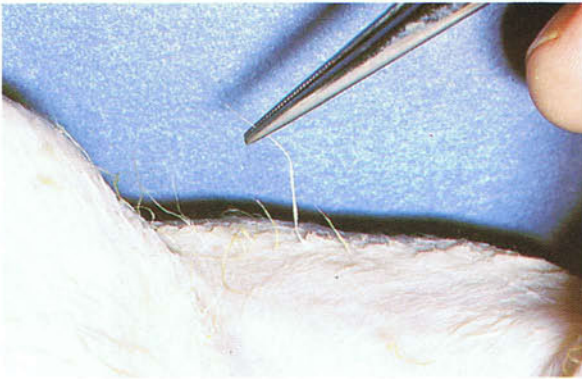

49 Bristle of an adult chicken. Bristle feathers typically consist of a stiff rachis and a few barbs at their proximal end. The feather in the photograph is a particular type of bristle called a semibristle in which the barbs arise from most of the length of the rachis. Bristles occur almost exclusively in the head and neck and include the so-called 'eye-lashes' (60) and the narial bristles around the nostrils. Because the follicles of the bristles are surrounded by numerous sensory Herbst corpuscles, it has been suggested that bristles are tactile sensory structures analogous to the whiskers of cats. (Scale, 1 mm)


50 and 51 Filoplumes. Following plucking, hair-like feathers called filoplumes usually remain on the carcass. They are characterized by a slender

stalk and a short tuft of barbs or barbules at their tip.

50



50 Filoplume of an adult chicken.



51

51 Filoplume of an adult chicken. (Scale, 1 mm)

52



52 Filoplume of an adult chicken. Filoplumes (arrow) never occur alone but always accompany other feathers which are generally semiplumes and contour feathers. Unlike other feather types they are not associated with smooth muscle bundles in the dermis. Within and around the walls of the filoplume follicles are numerous nerve endings; it has been suggested that the filoplumes are responsible for a proprioceptive sensory input which ensures that the feathers they are associated with are correctly positioned. In the poultry slaughter plant the filoplumes are left on the carcass after the birds have passed through the plucking machine; therefore they have to be removed by a process of singeing.

53 and 54 Afterfeather. The afterfeather (arrow) is a small feather attaching to the underside of a contour feather or semiplume at the rim of the distal umbilicus. Afterfeathers range from a downy tuft to a highly organized feather with well-developed

vanes similar to the distal part of contour feathers. In the afterfeather illustrated here the barbules are not hooked together so that the vane is entirely fluffy. It is likely that afterfeathers have a thermal insulatory role.

53



53 General contour feather and afterfeather of an adult chicken.

54



54 Afterfeather of 53 enlarged.



55 Wing feathers of an adult budgerigar. Feather colour and moulting. In the budgerigar there are 10 primary remiges (a) and 11 secondary remiges (b). Feather colours are either pigmentary or structural or a combination of both. Colours which are pigmentary in origin are due to pigments in the feathers, the principle ones being melanin, carotenoids and porphyrins. Colours which are structural in origin are due to the form of the feather surface and may originate from interference which produces iridescence as in starlings, or the scattering of light which results in non-iridescent colours such as the blue of the budgerigar. Green is an example of a colour resulting from both pigment and structure and is a combination of yellow carotenoids and Tyndall blue scattering. The colour pattern of feathers frequently shows sexual dimorphism and in many species the male is more highly coloured than the female. This does not apply, however, to the

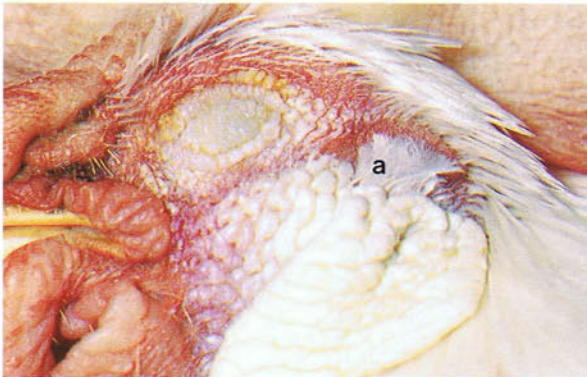
majority of small cage birds which are not sexually dimorphic. Variations in colour patterning may also be related to the season of the year or the age of the bird.

Moulting of feathers usually occurs once a year and generally after the breeding season in summer or autumn. Passerines typically moult sometime between May and December, the moult lasting between 5 and 8 weeks. Psittacine species can moult throughout the year, some birds appearing to moult continuously. The annual moult of adult pigeons is usually in August or September. In the chicken there is normally a complete moult in the autumn. The replacement of flight feathers in most species is carried out in a certain sequence, so that the bird retains its ability to fly. In ducks, however, all the large flight feathers are lost simultaneously, so that flight for a period is impossible.

56-59 Ear coverts and the ear. There is no auricle or ear flap in birds so that the external ear opening is flush with the surface of the head. It is covered by a circle of contour feathers, the ear coverts. The coverts (a) on the rostroventral rim of the opening are long and directed dorsocaudally. Those (b) on the remainder of the rim are short and vertically orientated, so that they form a funnel. The rostral feathers impinge on the tips of the vertical feathers and are arranged like a screen keeping out foreign objects. The passage of sound, however, is not obstructed because the barbs of the ear coverts are further apart than in other contour feathers. In the chicken the opening of the external ear (c) is circular and about 5 mm in diameter. From the

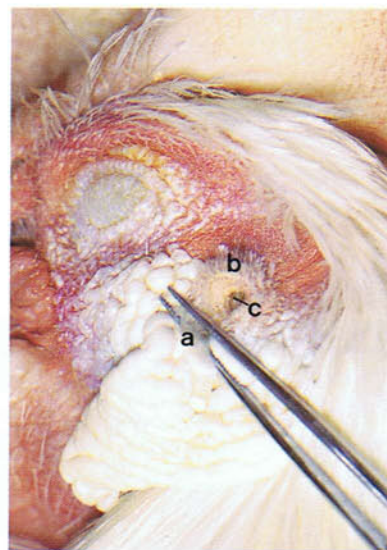
opening the external ear canal (d) extends downwards and inwards to the tympanic membrane (e) which forms the internal boundary of the external ear. The walls of the external ear canal contain holocrine glands. The tympanic membrane stretches across the rostradorsal part of the tympanic cavity (f). Vibrations of the tympanic membrane are transmitted to the inner ear by the bony columella, the only ear ossicle. The medial footplate of the columella is implanted in the vestibular window (1). The cochlear window (2) is closed by a thin membrane. Opening on the floor of the tympanic cavity is the pharyngo-tympanic tube which connects the middle ear to the pharynx via the infundibular cleft (see 102).

56



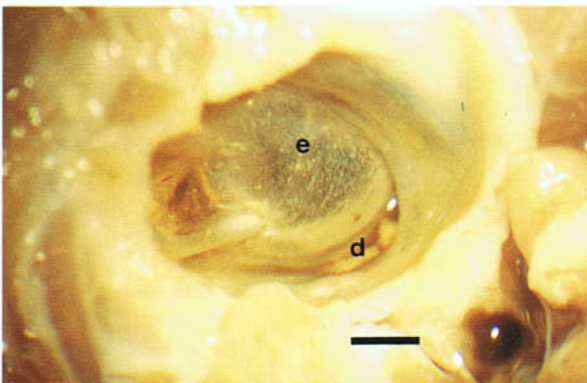
56 Ear coverts of an adult chicken.

57



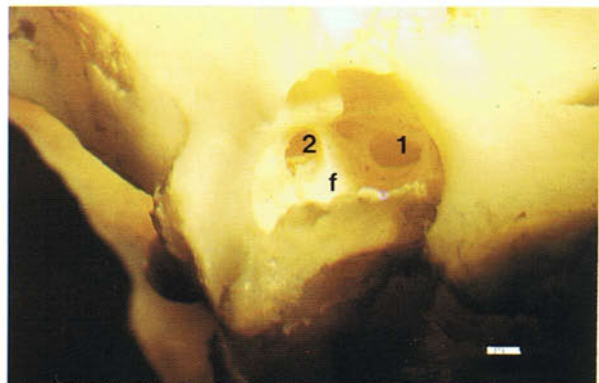
57 Ear coverts of an adult chicken displaced rostrally.

58



58 External ear canal and tympanic membrane of a 10-week-old chicken. Fixed preparation. (Scale, 1 mm)

59

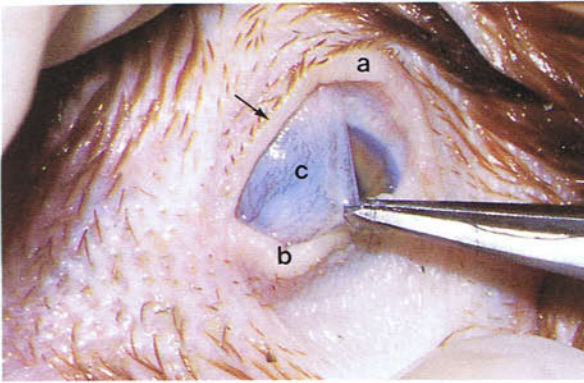


59 Right tympanic cavity of an adult duck. (Scale, 1 mm)

60 and 61 Eyelids and eyeball. The upper eyelid (a) is relatively immobile and only closes on sleep. The lower lid (b) is much thinner and more movable. With the eyelids open only a very small part of the eye is visible, so that a true indication of the enormous size of the eyeball shown in **61** is not given. The large size of the avian eye is related to its high visual capacity. In altricial species, including budgerigars and passeriforms, the eyelids are closed for a short time after hatching. The small

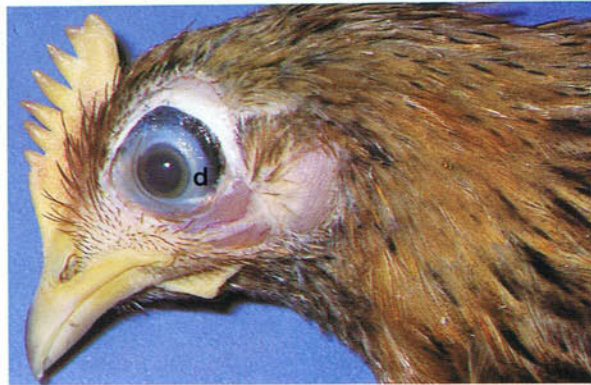feathers (arrow in **60**) at the margins of the lids are bristles. The transparent nictitating membrane or third eyelid (c) lies on the nasal side of the orbit and is moved across the eye in blinking by two striated muscles. Its sweeping movement helps to distribute the secretion of the gland of the membrane. During the electroplectic fit following stunning in the poultry slaughter plant, this corneal reflex disappears. The position of the ring of bony scleral ossicles (d) is seen in **61** (see also **65**).

60



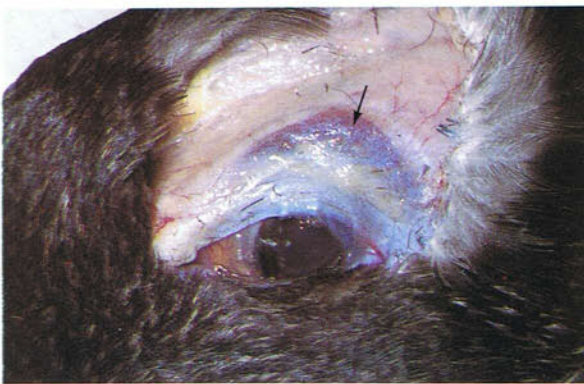60 Eyelids of an adult chicken.

61



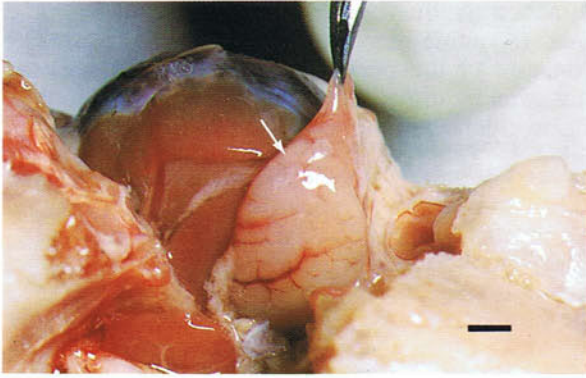
61 Eyeball of an adult chicken.

62



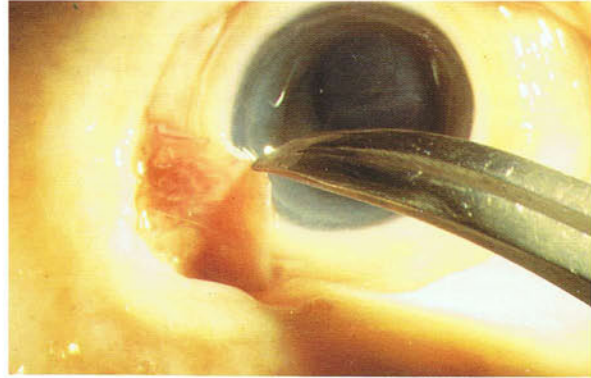
62 Nasal gland of an adult duck. The nasal gland (arrow) lies dorsal to the orbit and has an osmoregulatory function in marine species which enables these birds to drink sea water, a 3 per cent saline solution. The gland opens by ducts into the rostral part of the nasal cavity. Within the gland a counter-current system exists between the blood and the secretory cells. The gland is also osmoregulatory in some desert species and in terrestrial carnivores feeding on a very salty diet. It is also present, but non-functional, in many other terrestrial species, including the chicken.

63



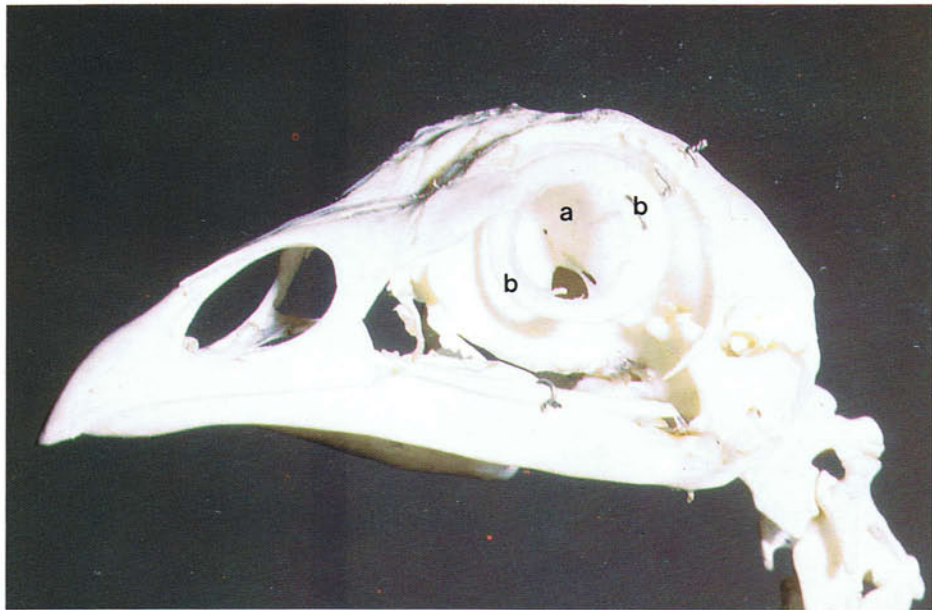
63 Gland of the left nictitating membrane of an adult duck. Caudal view. This large gland (arrow) lies on the caudomedial aspect of the eyeball. Its secretion flows onto the surface of the eye below the nictitating membrane. Within this gland and the nasal gland are numerous plasma cells which help to protect the eye against infection. (Scale, 3 mm)

64



64 Right lacrimal gland of an adult duck. The lacrimal gland is much smaller than the gland of the nictitating membrane and lies at the lateral canthus attached to the rim of the orbit. It drains into the conjunctival sac. The secretion of both the lacrimal gland and the gland of the nictitating membrane passes via two ostia at the medial commissure of the eyelids into the nasolacrimal duct which opens into the nasal cavity below the middle nasal concha (see 237).

65



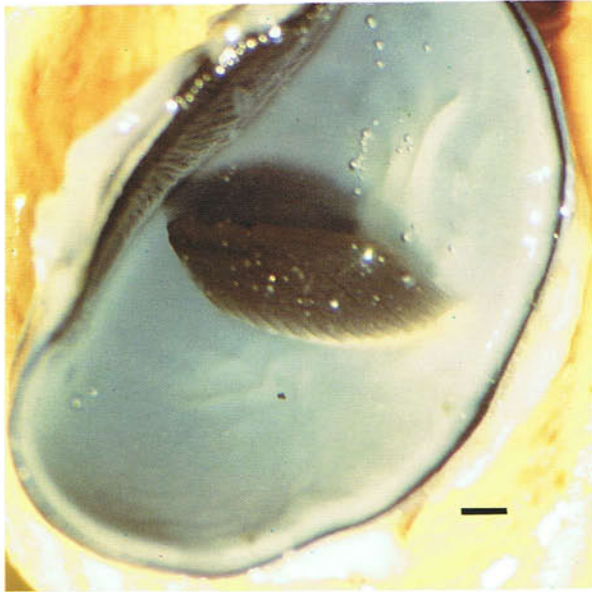
65 Bony orbit and scleral ossicles of an adult chicken. The bony orbit is exceptionally large and is incomplete. The eyeball almost totally fills the orbit, so that eye movements in birds are small. This is made up for by the great mobility of the head and very flexible neck. Because of the great size of the eyeballs, the right and left orbits are

separated by a very thin interorbital septum (a). The sclera in the region of the cornea is reinforced by a number of small bones, the scleral ossicles (b), which strengthen the eyeball and give attachment to the striated ciliary muscles of accommodation (see also 61). The remainder of the sclera is toughened by hyaline cartilage.

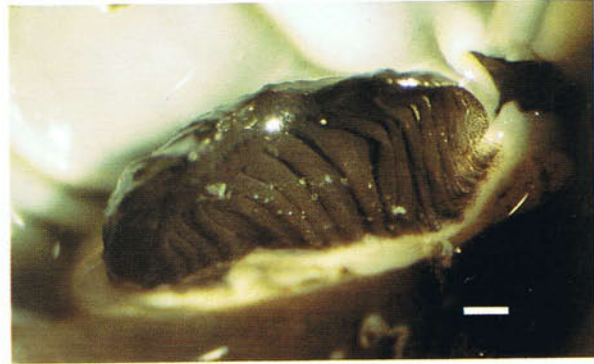66 and 67 Pecten of the chicken eye. The pecten is an extremely vascular pleated structure which projects from the retina into the vitreous body. Its base rests on the optic disc while distally the pleats are held together by a bridge which is firmly

attached to the vitreous body. Its black colour is due to numerous melanin pigment cells. The function of the pecten appears to be to provide nutrition by diffusion through the vitreous body to the avascular retina.

66



66 Pecten of the eye of a day-old-chicken. Fixed preparation. (Scale, 1 mm)



67

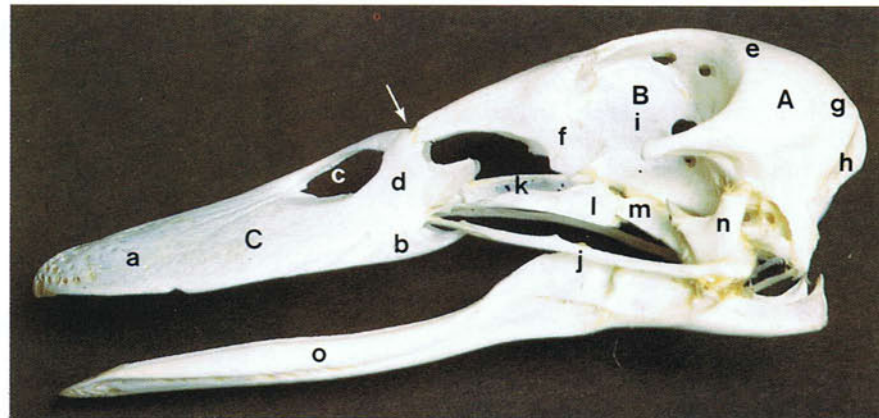
67 Pecten of the eye of an adult chicken. Fixed preparation (Scale, 1 mm)

Skeleton

68 Skeleton of an adult chicken. Compared with mammals the skeleton of birds is lighter and has a higher calcium phosphate composition. Its characteristic features include fusion of most of the trunk vertebrae, extreme mobility of the cervical vertebral chain, fusion of the pelvic girdle to the vertebral column and the absence of a pelvic symphysis, a prominent sternum, a strong pectoral girdle, and simplification of the skeleton of the limbs by the fusion or elimination of bones.



68



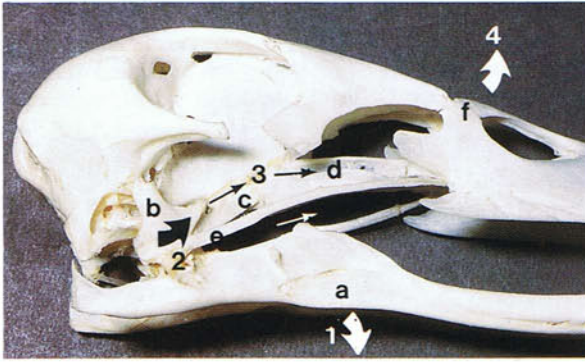
69

69 Skull of an adult duck. Lateral view. Characteristic features of the avian skull include the vaulted bulbous brain case (A), the large bony orbits (B), and the beak-shaped pyramidal face (C). The boundaries of individual bones are usually difficult to identify because the sutures between many of them are lost soon after hatching: (a) premaxilla; (b) maxilla; (c) bony external naris; (d) nasal bone; (e) frontal bone;

(f) lacrimal bone; (g) parietal bone; (h) occipital bone; (i) ethmoid bone (interorbital septum); (j) jugal arch; (k) vomer bone; (l) palatine bone; (m) pterygoid bone; (n) quadrate bone; (o) mandible.

To increase the size of the gape, the upper jaw is raised at the junction (arrow) of the cranium with the premaxillary and nasal bones where the bone is thin and flexible and the interorbital septum is absent.

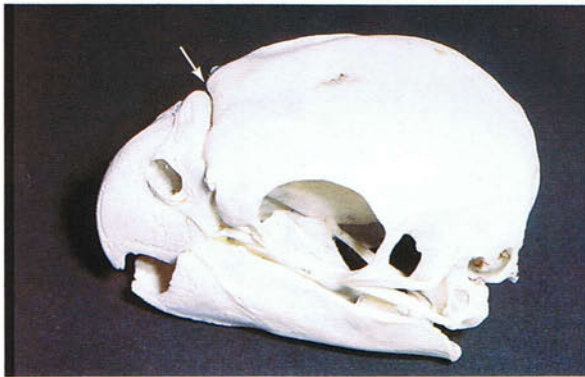70



70 Cranial kinesis in the skull of an adult duck. Lateral view. Cranial kinesis is movement of the upper jaw in relation to the brain case. Because the quadrate bones articulate with the brain case,

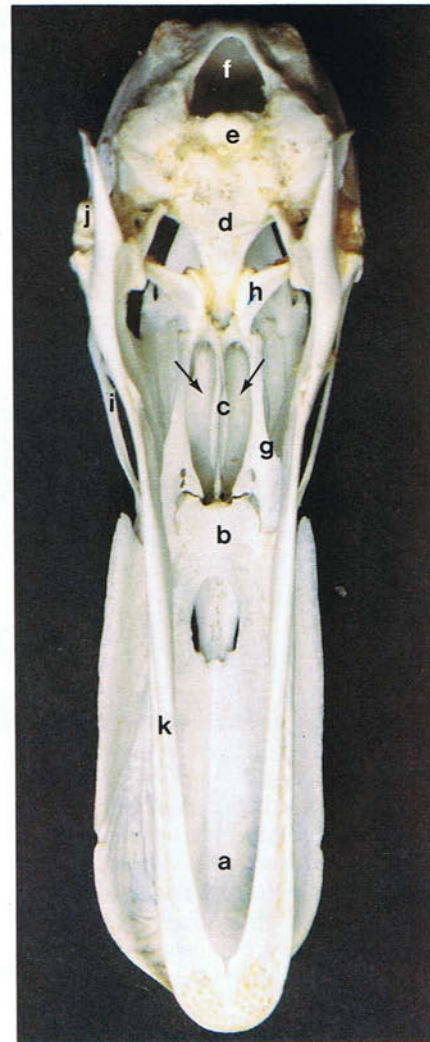
pterygoid bones, jugal arches, and mandible they are pivoting points in cranial kinesis. The particular type of cranial kinesis which occurs in chickens, ducks and parrots is known as prokinesis. In the process of raising the upper jaw, depression (1) of the mandible (a) rotates (2) the quadrate bones (b) rostrally and pushes (3) the pterygoid (c) and palatine (d) bones and the jugal arches (e) forward. This results in the upper jaw swinging forward and upwards (4) at the craniofacial elastic zone (f) where the bone is thin and flexible. Conversely caudal rotation of the quadrates lowers the upper jaw. In many species, including pigeons, the elevation of the upper jaw occurs rostral to the junction of the jaw and brain case and is known as rynchokinesis. In contrast to prokinesis, it involves only the rostral part of the upper jaw.

71



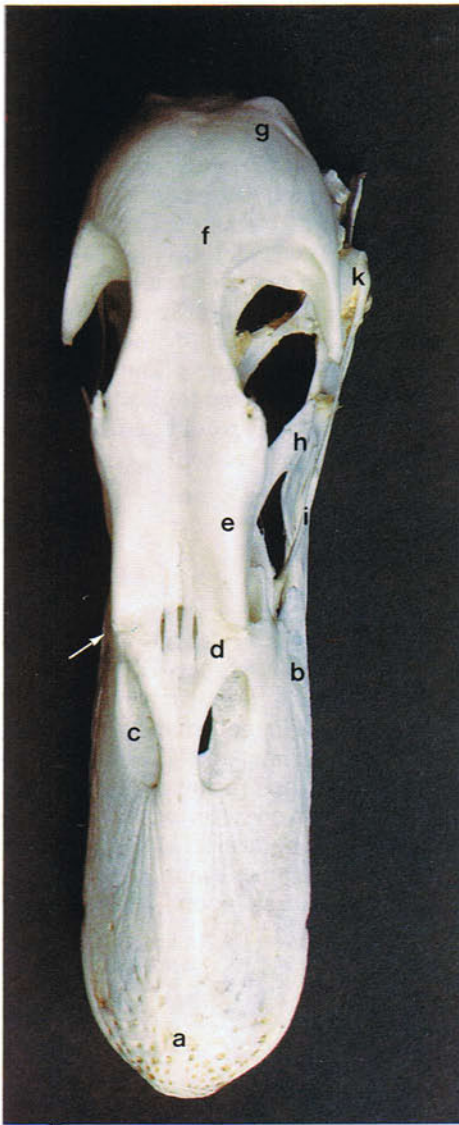
71 Skull of a parakeet. In psittacine species, including the budgerigar, prokinesis is highly developed, the craniofacial elastic zone between the nasal and frontal bones being converted into a synovial hinge joint (arrow).

72 Skull of an adult duck. Ventral view: (a) premaxilla; (b) maxilla; (c) vomer; (d) sphenoid bone; (e) occipital bone; (f) foramen magnum; (g) palatine bone; (h) pterygoid bone; (i) jugal arch; (j) quadrate bone; (k) mandible. The internal nares (arrows) lie between the palatine bones and the vomer.



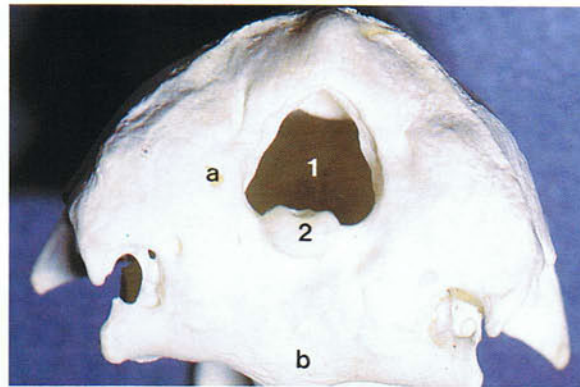
72

73



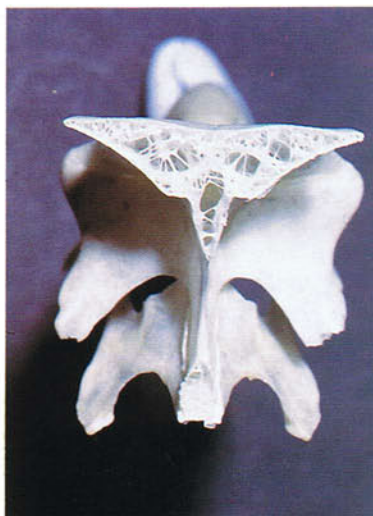73 Skull of an adult duck. Dorsal view: (a) premaxilla; (b) maxilla; (c) bony external naris; (d) nasal bone; (e) prefrontal bone; (f) frontal bone; (g) parietal bone; (h) lacrimal bone; (i) jugal arch; (j) pterygoid bone; (k) quadrate bone. The craniofacial elastic zone (arrow) lies between the cranium and the nasal and premaxillary bones.

74

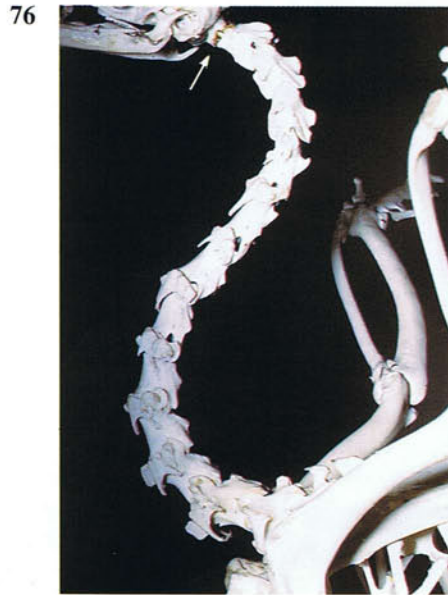


74 Skull of an adult duck. Caudal view: (a) occipital bone; (b) sphenoid bone. The occipital bone encloses the foramen magnum (1). A characteristic feature of the avian skull is the single occipital condyle (2), which makes the atlanto-occipital joint a much more mobile articulation than in mammals and allows considerable rotation of the head.

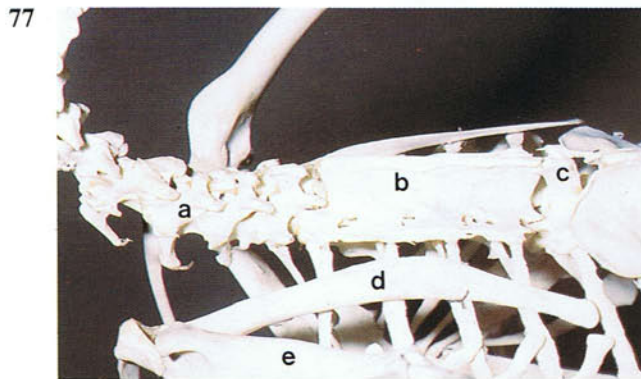
75



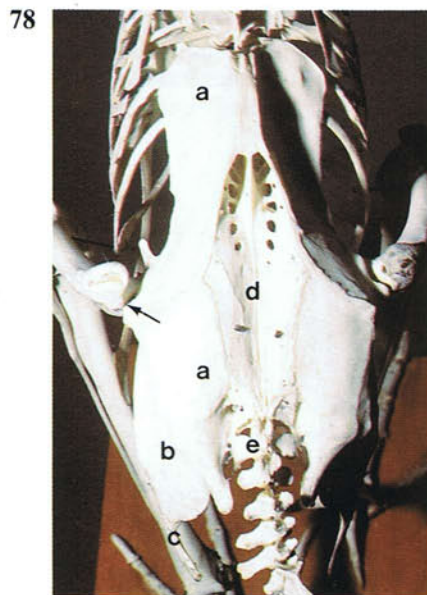
75 Pneumatization of the skull. Some of the skull bones, like the frontal bone of the passeriform species in the photograph, are formed by two thin plates of compact bone joined together by a network of delicate spicules enclosing air spaces continuous with the tympanic and nasal cavities. Pneumatization and the concomitant reduction of the weight of the skull is probably an adaptation for flight.



76 The S-shaped cervical region of the vertebral column of an adult chicken. Left lateral view. Unlike in mammals the number of cervical vertebrae varies with the length of the neck. In the chicken there are usually 16 vertebrae. The joints between the vertebrae are synovial and the articular surfaces of the bodies are saddle-shaped, so that this region of the vertebral column is extremely flexible. The small ring-shaped atlas (arrow) articulates with a single occipital condyle, so that the atlanto-occipital joint is exceptionally mobile. The great flexibility of the vertebral column and the mobility of the atlanto-occipital joint allows the beak to be used for a wide variety of tasks, which in mammals would be carried out by the forelimbs.

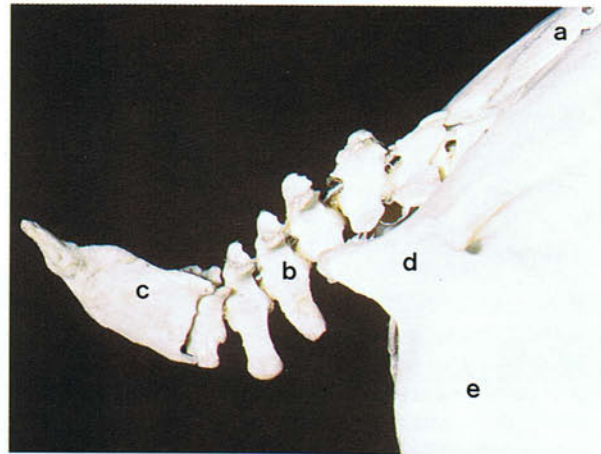


77 Cervical and thoracic vertebrae of an adult chicken. Left lateral view: (a) cervical vertebrae; (b) notarium; (c) fourth thoracic vertebra; (d) scapula; (e) humerus. The notarium is formed by the last cervical vertebra and the first three thoracic vertebrae, the fusion between the vertebrae in the chicken starting at about 4 months of age. The notarium along with the synsacrum gives the spine great rigidity. The vertebrae in the duck and goose remain freely movable.

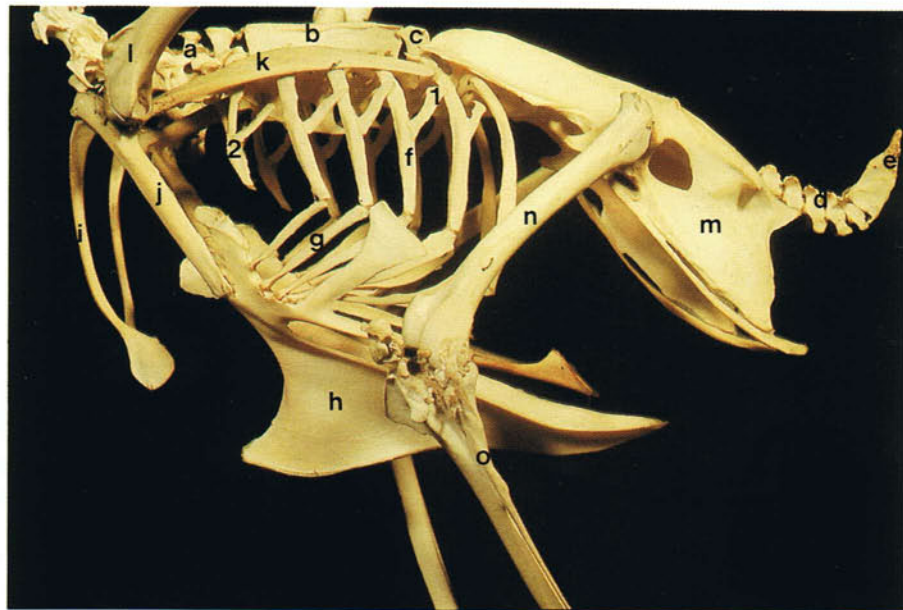


78 Synsacrum and pelvis of an adult chicken. Dorsal view: (a) ilium; (b) ischium; (c) pubis; (d) synsacrum; (e) free caudal vertebrae. The synsacrum consists of fused thoracic, lumbar, sacral and caudal vertebrae, the fusion in the chicken starting at about 7 weeks. The synsacrum is itself fused to the ilium. The antitrochanteric process (arrow) of the pelvic bone is covered by cartilage and articulates with the neck and trochanter of the femur. The joint acts to limit abduction of the limb.

79 Caudal part of the vertebral column of an adult chicken. Right lateral view: (a) synsacrum; (b) free caudal vertebrae; (c) pygostyle; (d) ilium; (e) ischium. In the chicken there are six free caudal vertebrae which permit movement of the tail. The pygostyle consists of between four and six fused caudal vertebrae and provides attachment for the innermost tail feathers.



79



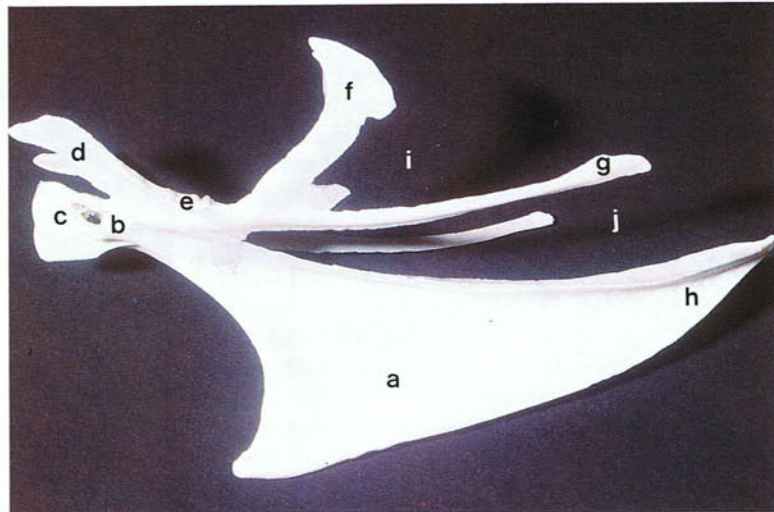
80

80 Trunk skeleton of an adult chicken. Lateral view: (a) cervical vertebrae; (b) notarium; (c) fourth thoracic vertebra; (d) free caudal vertebrae; (e) pygostyle; (f) vertebral rib; (g) sternal rib; (h) sternum; (i) clavicle; (j) coracoid bone; (k) scapula; (l) humerus; (m) pelvis; (n) femur; (o) tibia and fibula. In the chicken there are five or six pairs of ribs, each rib consisting of a vertebral part which has a double articulation with the vertebral column and a sternal part which articulates with the sternum. The uncinat processes (1) of the vertebral ribs provide attachments for muscles and ligaments and strengthen the thoracic wall. The bony sternal

ribs correspond to the costal cartilages of mammals and provide support for the thorax during the downstroke of the wing. The vertebral and sternal ribs articulate at a movable cartilaginous joint. The last few cervical vertebrae articulate with floating ribs (2) which lack a sternal component. The articulations between the thoracic ribs and the vertebral column and between the thoracic and sternal ribs allow the size of the thoracic cage to be changed during inspiration and expiration. The resulting changes in pressure in the body cavity and air sacs allow air to be moved into and out of the lower respiratory system.

81 Sternum of an adult chicken.

Left lateral view: (a) keel (carina); (b) articular facet for coracoid bone; (c) rostrum; (d) cranio-lateral process; (e) articular facets for ribs; (f) thoracic process; (g) caudolateral process; (h) median trabecula; (i) lateral notch; (j) medial notch. The well-developed keel is characteristic of all 'carinates'. In 'ratites' such as the ostrich on the other hand, the keel is flat and raft-like. The keel provides attachments for the strong flight muscles and is especially prominent in good fliers. The lateral and medial notches are closed in life by fibrous membranes and with the thoracic and caudolateral processes strengthen the body wall. In the young bird the caudal part of the median trabecula is cartilaginous and flexible. In the pigeon the caudolateral process arises separate from the thoracic process and

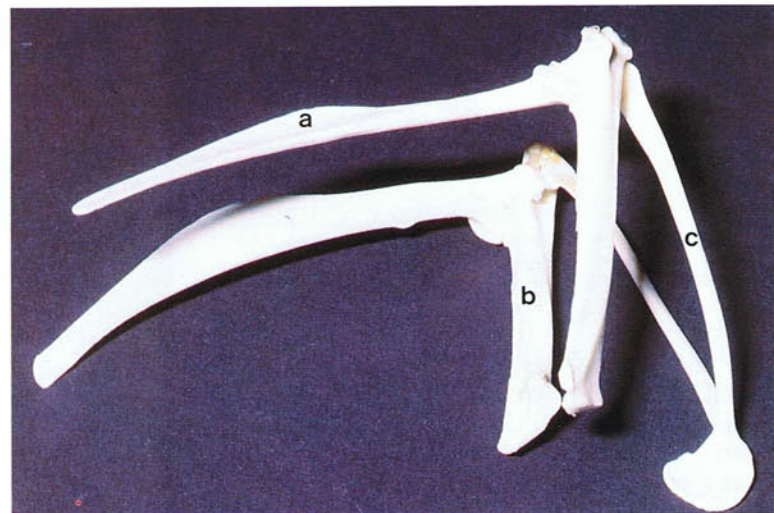


81

fuses caudally with the median trabecula. The thoracic process is absent in the duck and goose. The cranial part of the sternum in the Whooper Swan (*Cygnus cygnus*) is excavated to form a cavity in which the coils of the enormously long trachea lie.

82 Right and left thoracic girdles of an adult chicken.

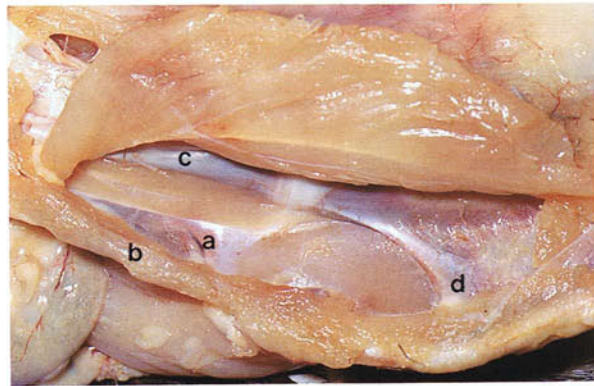
Right ventrolateral view. In birds the thoracic girdle consists of the scapula, clavicle and coracoid bones. The blade-like scapula (a) is relatively immobile and is firmly held to the ribs by muscle and ligaments. Cranially it articulates with the clavicle, coracoid bone and humerus. The extremely large coracoid (b) extends between the sternum and the shoulder joint. It



82

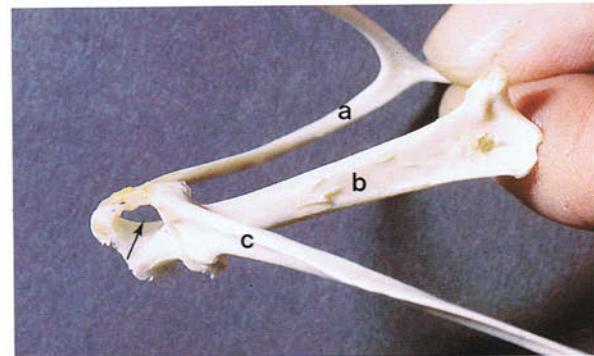
acts to hold the wings away from the sternum during flight, and with the ribs prevents the thorax collapsing during the downstroke of the wing. The right and left clavicles (c) fuse ventrally to form the furcula (wishbone). They are absent or very reduced in some species of parrot. The furcula acts as a spring holding the shoulder joints the optimum distance apart during wing movement.

83 Left sternocoracoclavicular membrane of an adult chicken. This tough, fibrous sheet (a) extends between the clavicle (b), coracoid (c) and sternum (d) and anchors the three bones together.

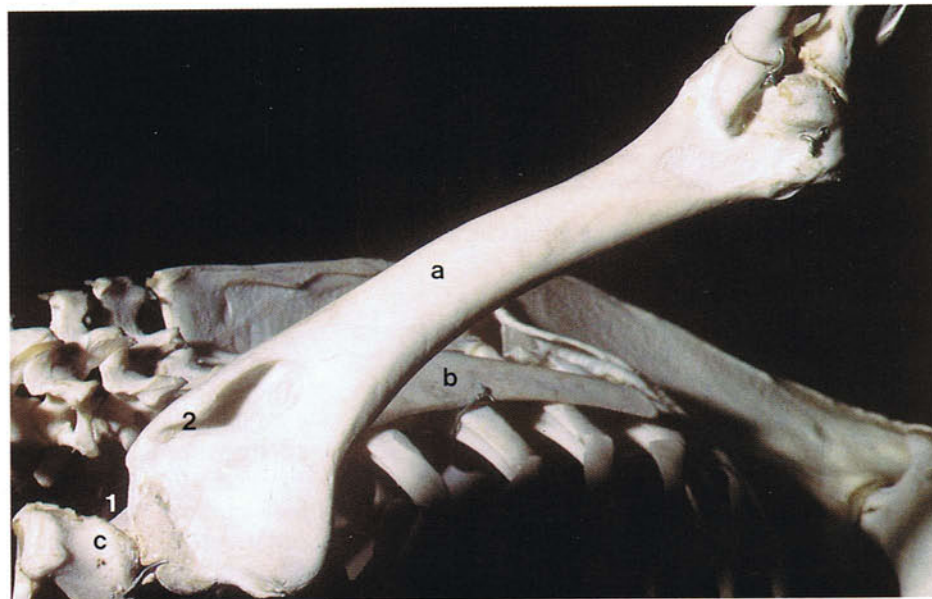


83

84 Triosseal canal of an adult chicken. Where the clavicle (a), coracoid (b) and scapula (c) meet medial to the shoulder joint is a space (arrow), the triosseal canal. Through the canal runs the tendon of the supracoracoid muscle which raises the humerus and causes the upstroke of the wing.



84



85

85 Left humerus of an adult chicken with the wing rotated away from the trunk. The shoulder joint (1) is formed between the humerus (a), scapula (b) and coracoid bone (c). Movements of the humerus include elevation, depression, protraction and retraction. There is also movement around the axis of the wing including dorsal rotation which elevates the leading edge of

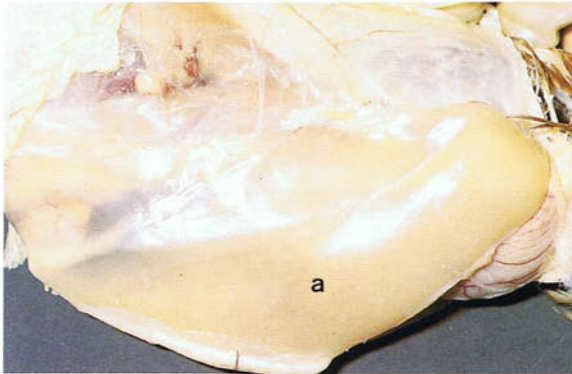the wing and ventral rotation which depresses the leading edge of the wing. The pectoral muscle, which is the main depressor of the humerus and therefore of the wing, attaches to the pectoral crest (2). When the wing is folded the humerus lies against the thoracic cage parallel to the scapula.

86-88 Breast (flight) muscles of an adult chicken.

On each side there are two flight muscles, a superficial pectoral muscle (a) and a deep supracoracoid muscle (b). The pectoral muscle extends from the keel of the sternum, the clavicle and the sternocoracoclavicular membrane to the pectoral crest of the humerus (see 85) and is the main depressor of the wing. The supracoracoid muscle extends from the keel of the sternum through the triosseal canal (arrow) (see also 84) to the dorsal surface of the humerus and is the main elevator of the wing. In adult turkeys and broiler breeders the supracoracoid muscle is the site of Oregon muscle disease (deep pectoral myopathy). The condition arises after sudden excessive activity and the accumulation of interstitial fluid in the muscle. Because the fascial

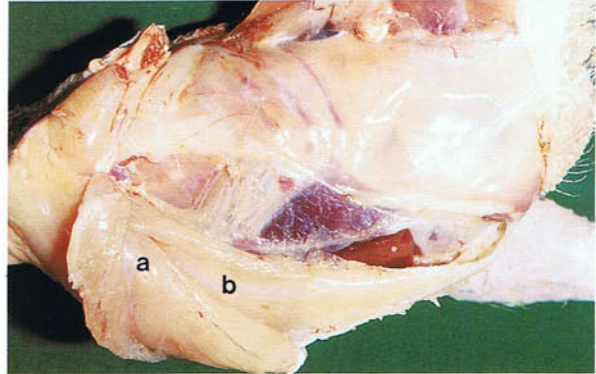
coat of the muscle prevents it from expanding, the accumulating interstitial fluid presses on the blood vessels causing foci of necrosis to develop. The breast muscles of the chicken and other species with a rapid jump take off contain more white muscle fibres than red fibres; because white fibres have relatively small amounts of myoglobin, the breast muscles in these species are pale. White muscles are characterized by being powerful but they are not suited for sustained activity. The breast muscles can be used for intramuscular injections. However, the needle should be inserted into the caudal part of the muscle rather than the cranial part where the blood supply is well-developed and there is a greater chance of injecting into a vein.

86



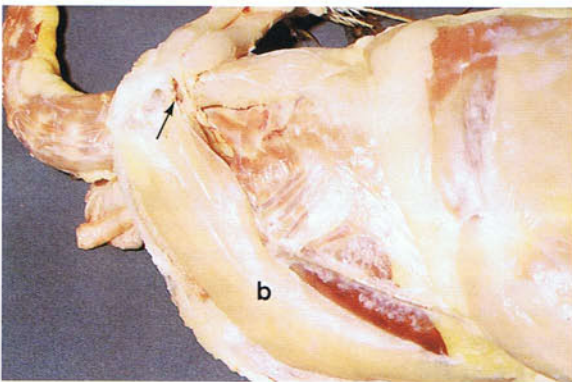
86 Right pectoral muscle of an adult chicken.

87



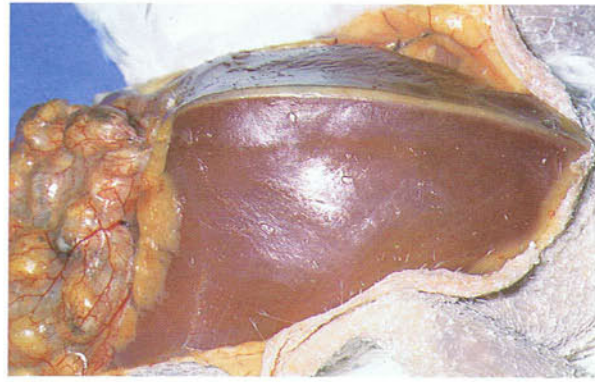
87 Left supracoracoid muscle of an adult chicken with the pectoral muscle reflected.

88



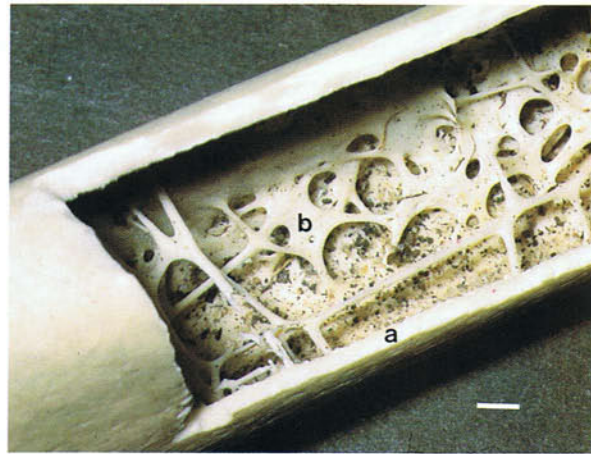
88 Left supracoracoid muscle of an adult chicken.

89 Breast muscles of an adult pigeon. Ventral view. The breast muscles in the pigeon are red because they contain predominantly red fibres. Red muscle fibres use fat rather than glycogen as an energy source. Consequently they are more efficient than white fibres, because fat yields more energy than does carbohydrate per unit weight. Muscles which are used for sustained activity, therefore, like the breast muscles of good fliers, contain a high proportion of red fibres.



89

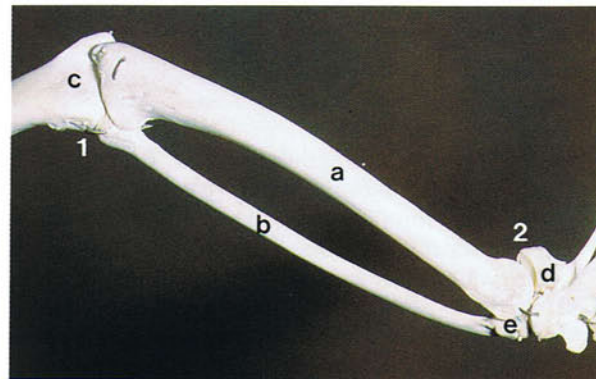
90 Gross anatomy of an avian long bone. As shown in this section of the humerus of a large seabird the cortex (a) is exceptionally thin and the medullary cavity (b) contains a network of trabeculae which increases the strength of the bone. The thin and brittle nature of the outer shell makes the bone unsuitable for plating in the treatment of fractures, while intramedullary pinning would have the effect of destroying the internal strutting. Many of the bones of the post-cranial skeleton are pneumatized by diverticula of the air sacs which invade the medullary cavity of the long bones and the medullary spaces of the spongy bones where they replace the bone marrow. In female birds, prior to the laying season, a cancellous type of bone, medullary bone, is laid down in the medullary cavity of the long bones under the influence of oestrogens and androgens. During the egg laying cycle this bone is alternately undergoing formation and destruction and, along with the diet, acts as a source of calcium for the



90

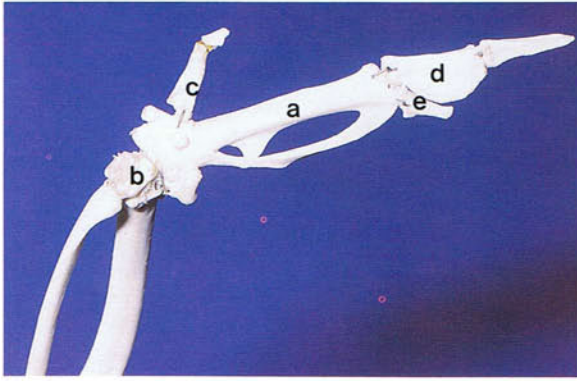
manufacture of the egg shell. The presence of medullary bone increases the weight of the chicken skeleton before laying by approximately 20 per cent. (Scale, 2 mm)

91 Left forearm bones of an adult chicken with the wing rotated away from the trunk. In the chicken the ulna (a) is stouter than the radius (b), the two bones being bowed along their length so that they are protected against bending forces in the plane of the wing. Attaching to the ulna by ligaments are the roots of the secondary flight feathers (see 39). When the wing is folded the ulna and radius lie close to the thorax and parallel to the humerus. The elbow joint (1) is formed by the condyles of the humerus (c) and the proximal ends of the radius and ulna. Movements at the joint are principally flexion and extension in the plane of the wing surface, with some rotation about the long axis of the forearm. At the carpal joint (2) the ulna and radius articulate with the ulnar (d) and radial (e) carpal bones.



91

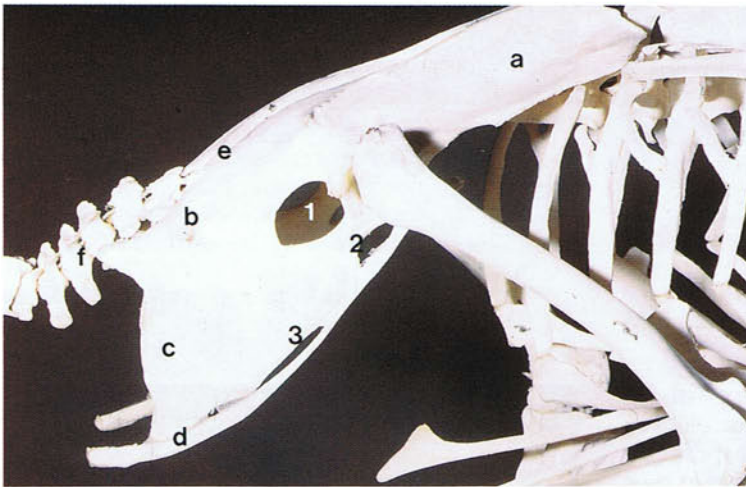
92



92 Left manus of an adult chicken with the wing rotated away from the trunk. By the second or third week after hatching the distal row of carpal bones has fused with the metacarpus to form the carpometacarpus (a). The carpometacarpus articulates at the wrist with the radial and ulnar carpal bones (b). The three digits are the alular digit (c) with two phalanges, the major digit (d) with two phalanges, and the minor digit (e) with one phalanx. Attaching to the carpometacarpus and the phalanges of the major and minor digits are

the primary flight feathers (see 39). The alular digit forms the skeleton of the bastard wing (see 43) which during slow flight is extended away from the wing to form a slot preventing stalling. Amputation or surgical pinioning of the wing to prevent escape in waterfowl and other ornamental birds is performed by cutting off the manus of one wing through the proximal part of the carpometacarpus, so that the bird is off-balance when trying to fly. The optimum age for the operation is in the down chick stage. Surgical pinioning is illegal in birds kept for agricultural purposes. Movements at the wrist joint are mainly flexion and extension in the plane of the wing surface and are coupled to movements of the elbow joint. Thus, during flexion of the elbow joint the wrist is flexed while extension of the elbow joint causes the wrist to be extended. Movements of the digits include flexion, extension, elevation and depression. Extension of the major and minor digits has the effect of spreading the primary flight feathers, while flexion has the effect of folding the primary feathers.

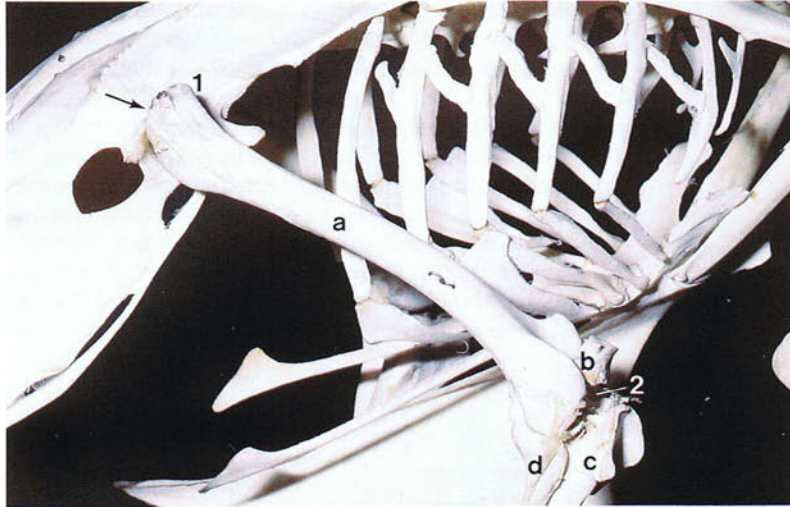
93



93 Pelvic girdle of an adult chicken. Right lateral view. (a) Preacetabular ilium; (b) postacetabular ilium; (c) ischium; (d) pubis; (e) caudal part of the synsacrum; (f) free caudal vertebrae. (1) Ilioischadic foramen; (2) obturator foramen; (3) ischiopubic fenestra. The avian pelvic girdle consists on each side of partly fused ilium, ischium and pubis, the ilium being also joined to the synsacral part of the vertebral column (see 78). Except in a very few species the pelvic girdle is incomplete ventrally. The ilioischadic foramen transmits the ischiadic nerve. The large size and arched shape of the pelvic girdle and its fusion

with the vertebral column are adaptations for supporting the trunk in the bipedal standing position. Aviculturists sometimes try to sex birds by assessing the distance between the pubic bones, the supposition being that the bones are further apart in females than in males. However, it is generally accepted that the test is subjective and unreliable. The space between the pelvic bones is also used to establish whether a pullet is in lay or not. In the so-called 'finger' test, two fingers comfortably inserted between the bones is an indication of a laying hen, while three fingers is an indication of a bird heavily into lay.

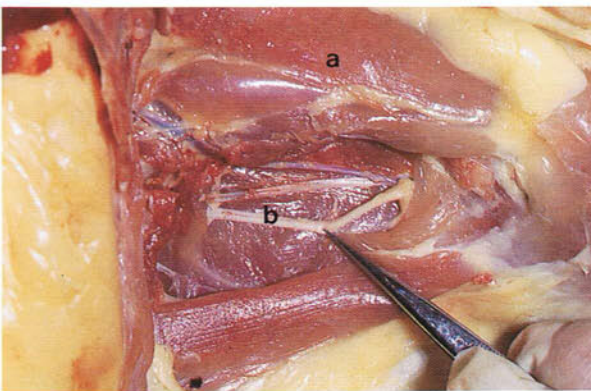
94



94 Right femur of an adult chicken. Lateral view. The distal end of the femur (a) slopes cranio-laterally bringing much of the hind limb close to the centre of gravity of the body. Within the single joint cavity of the hip joint (1) are two articulations, one formed between the head of the femur and the acetabulum of the pelvic bone as in mammals, and one formed between the femoral trochanter (arrow) and the antitrochanter of the ilium (see 78). Movements of the thigh include protraction, retraction, abduction, adduction and

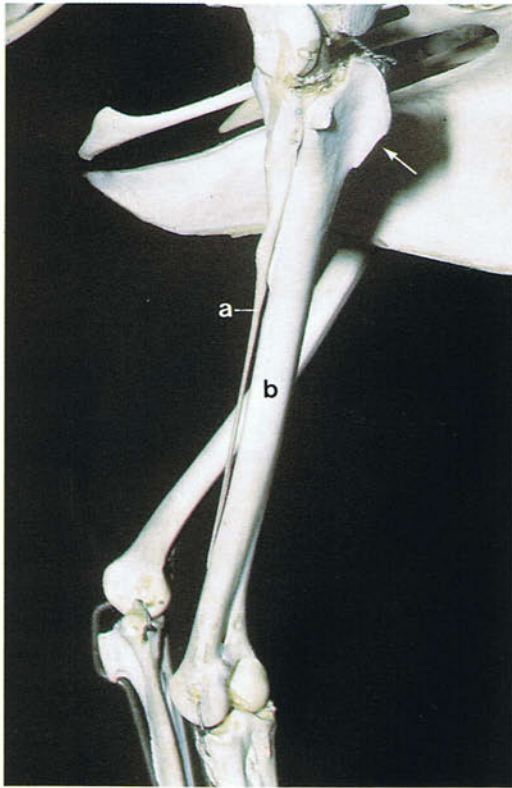
rotation. As well as rotating the limb, the rotatory muscles are responsible during locomotion for bringing the body over the supporting leg when the opposite leg is in the air, which results in the waddling type of gait typical of birds with short legs such as ducks. The knee joint (2) is formed between the distal end of the femur, the patella (b), and the proximal ends of the tibiotarsus (c) and fibula (d). Its main movements are flexion and extension.

95



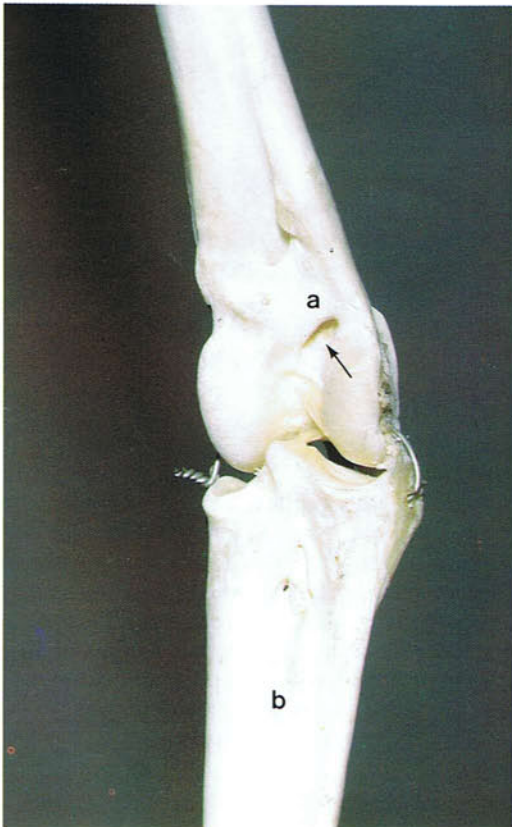95 Ischiadic nerve of a chicken. In this photograph the position of the femur is indicated by the muscle mass (a) which covers its medial surface. The ischiadic nerve (b) lies behind the femur and below two muscles on the medial aspect of the limb which have been removed. Marek's disease is a condition of poultry in which there is a proliferation of lymphoid tissue and a special predilection for peripheral nerves which become irregularly thickened. The ischiadic nerve is one of the nerves which is usually examined post-mortem. Other nerves which are inspected are shown in 193, 194, 196, 230, 231, 233 and 269. While intramuscular injections can be made into the thigh muscles, there is a danger that the ischiadic nerve may be damaged. Furthermore, substances injected into the hindlimb may pass through the renal portal system (see 195) before entering the systemic circulation.

96



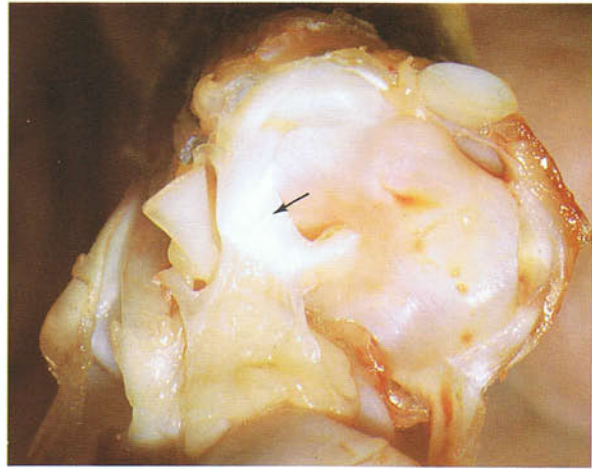96 Right crural bones of an adult chicken. Lateral view. This part of the limb is frequently referred to as the 'drumstick' and consists of the splint-like fibula (a) and the tibia which has fused with the proximal row of tarsal bones to form the tibiotarsus (b). However, the proximal row of tarsal bones remains free for the first few months after hatching. The cranial cnemial crest (arrow) provides an attachment for the main extensor muscle of the knee joint. Unlike the other long bones, the tibiotarsus and femur are good sources of bone marrow.

97



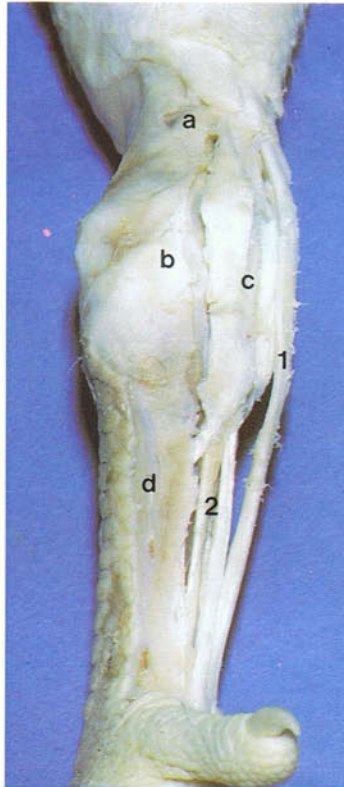
97 Right tarsal (hock) region of an adult chicken. Dorsal view. The articulation is an intertarsal joint between the tibiotarsus (a) and the tarsometatarsus (b). The main movements are flexion and extension. On the cranial surface of the distal part of the tibiotarsus is the extensor canal (arrow) through which the tendons of the extensor muscles of the toes pass.

98 Left hock joint of an adult chicken opened to show the tarsometatarsal articular surfaces. In the lateral part of the joint is a cartilaginous meniscus (arrow) which lessens the incongruence of the articular surfaces. A medial meniscus is absent in the chicken. The hock joint is routinely examined in the poultry slaughter plant.



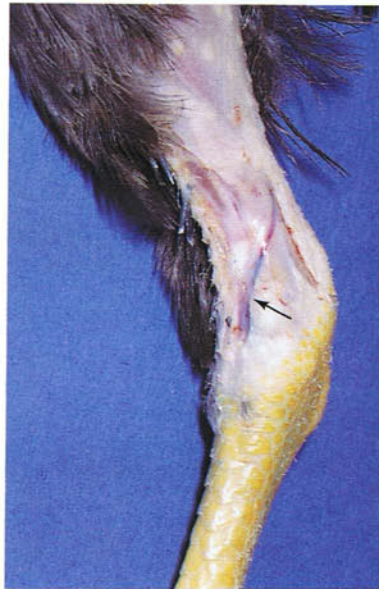98

99 Tibial cartilage of an adult chicken. Fixed preparation: (a) tibiotarsus; (b) hock joint; (c) tibial cartilage; (d) tarsometatarsus. The tibial cartilage is a fibrocartilaginous block on the caudal aspect of the hock joint. Passing over it are the tendons of the gastrocnemius and superficial digital flexor muscles (1) while the tendons of the deep digital flexors (2) travel through canals in the cartilage. In the chicken and turkey ossification may develop in many of the tendons of the wing and hindlimb. Bone formation in the chicken starts after about 90 days and occurs especially in the tarsometatarsal region and on the caudal tibiotarsus, dorsal carpometacarpus and caudal antebrachium.



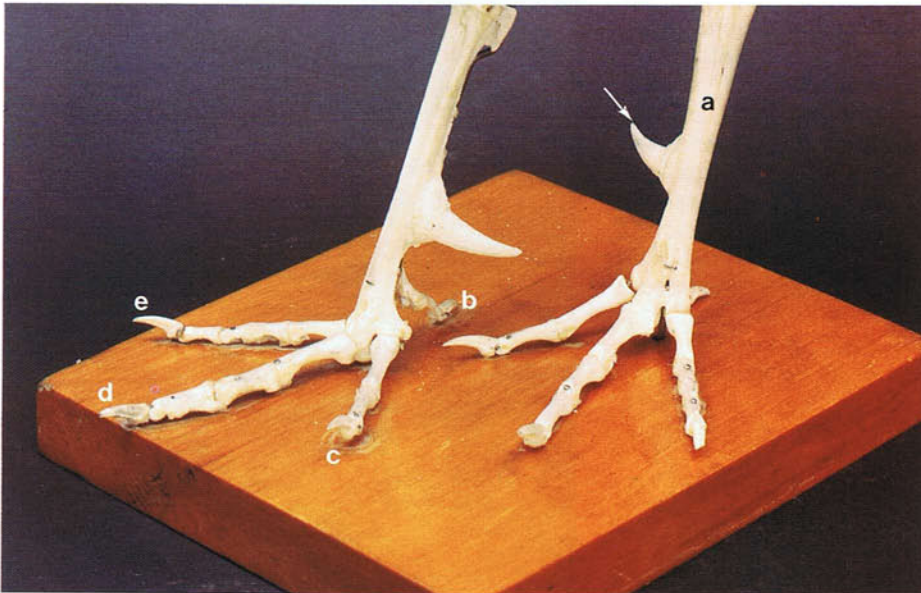
99

100



100 Caudal tibial vein of a 10-week-old chicken. The caudal tibial vein (arrow) crosses the medial aspect of the tarsal joint where it is easily accessible. Except in the smallest species it can be used for intravenous injections.

101



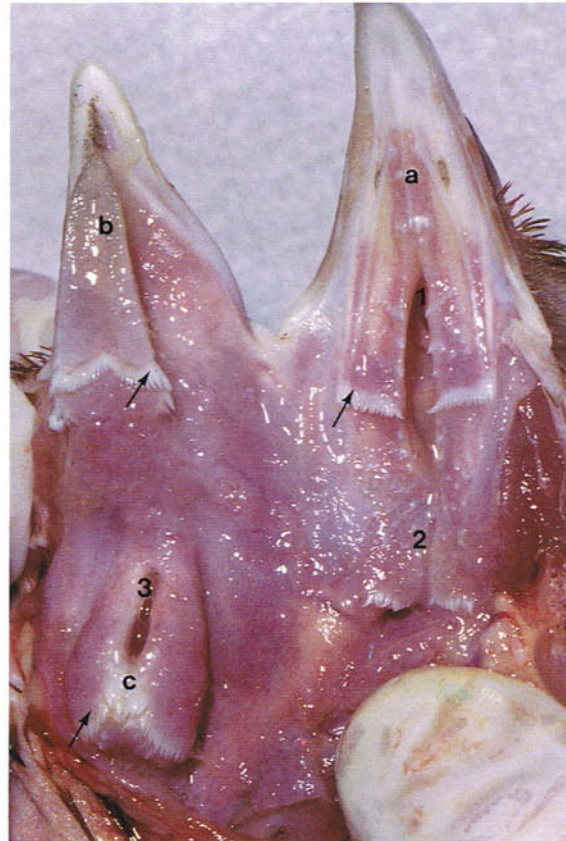101 Feet of an adult chicken: (a) tarsometatarsal bone; (b-e) digits I-IV. The tarsometatarsus is formed by the fusion of the distal row of tarsal bones and the metatarsal bones of digits II, III and IV. Evidence for this is visible at its distal extremity which has three articular trochleae. A bony process (arrow) arises from the distal part of the medial surface in males and many females and is the core of the spur (see 19). A small movable metatarsal I remains separate and is attached to the tarsometatarsus by ligaments. Digits I-IV have two, three, four and five phalanges

respectively. This seems to be a general phalangeal formula for birds. The most distal phalanx forms the bony core of the keratinized claw. When a bird crouches during perching, flexion of the hock joint tenses the digital flexor tendons which cross the caudal surface of the joint and passively clamps the digits around the perch. On rising the hock is extended which removes the tension from the flexor tendons, so that the digits can be extended. This mechanism should be remembered when attempting to undo the grasp of a large bird.

Digestive system

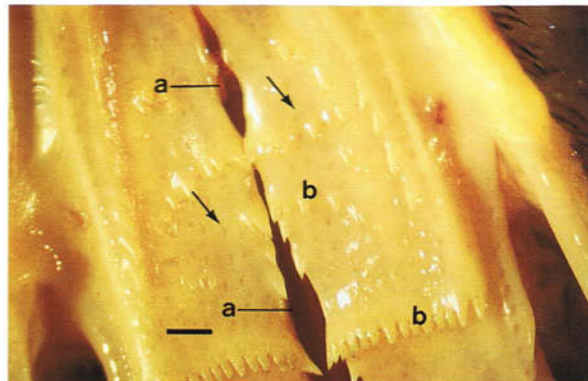
102 Oral cavity and pharynx of an adult chicken.

Because a soft palate and oropharyngeal isthmus are absent, the oral and pharyngeal cavities together form a common cavity which is often referred to as the 'oropharynx'. On the palate (a) is the choana (1), the median fissure opening into the nasal cavities. The infundibular cleft (2) is the common opening of the auditory tubes. The tongue (b) in the chicken, turkey and pigeon cannot be protruded and is mainly an organ of swallowing. The laryngeal mound (c) has on its rostral surface the glottis (3) which is the entrance to the larynx. Many backward-pointing, thickly keratinized papillae (arrows) are distributed on the roof of the oropharynx, on the tongue and on the laryngeal mound. The opening of the mouth is generally called the gape. Swallowing is achieved by rapid rostrocaudal movements of the tongue and the laryngeal mound assisted by much sticky saliva and the caudally-directed papillae which propel the food backwards and prevent its regurgitation. During this process the choana, infundibular cleft and glottis are reflexly closed. The method of drinking varies with the species. In the chicken water is propelled into the mouth by rostrocaudal movements of the tongue. The head is then raised and the water passes into the oesophagus mainly by gravity. In the pigeon, in contrast, the beak is immersed in the water throughout and the head is not raised.



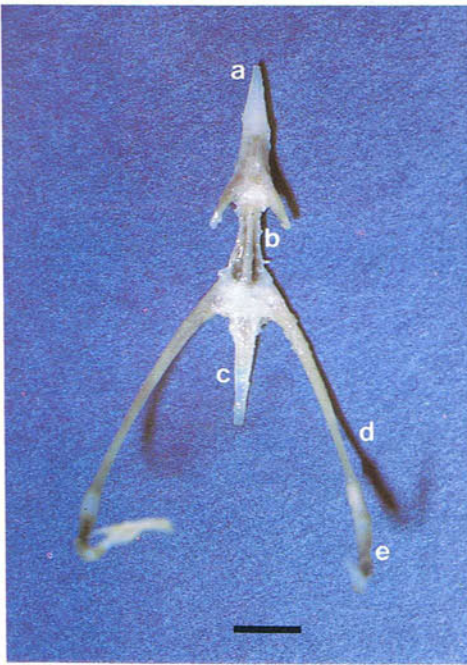
102

103 Palate of an adult chicken. Ventral view: (a) choana; (b) papillae. The numerous openings of the mucus-secreting salivary glands which form an almost continuous layer in the walls of the oropharynx are indicated by arrows. (Scale, 1 mm)



103

104

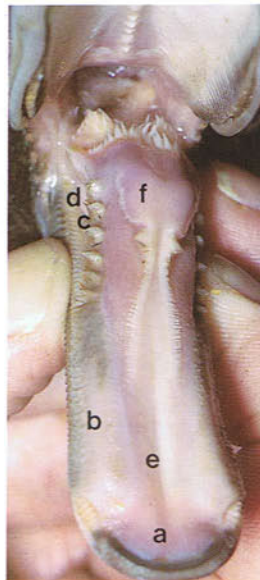

104 Hyoid apparatus of an adult chicken. Dorsal view: (a) entoglossal bone; (b) rostral basibranchial bone; (c) caudal basibranchial bone; (d) ceratobranchial bone; (e) epibranchial bone. The entoglossal bone lies in the body of the tongue and the rostral basibranchial bone in the base of the tongue. The hyoid apparatus and its associated musculature are responsible for tongue movements. Except in parrots, there are no true intrinsic muscles in the tongue. (Scale, 5 mm)

105-108 Tongue of a duck. The tongues of ducks, geese and swans are adapted along with the lamellae of the bill either for straining minute organisms from water or for cropping grass and weeds. The fleshy tongue of the domestic duck is a straining organ. Its rostral part has a scoop-like process (a) and the lateral margin has a double row of overlapp-

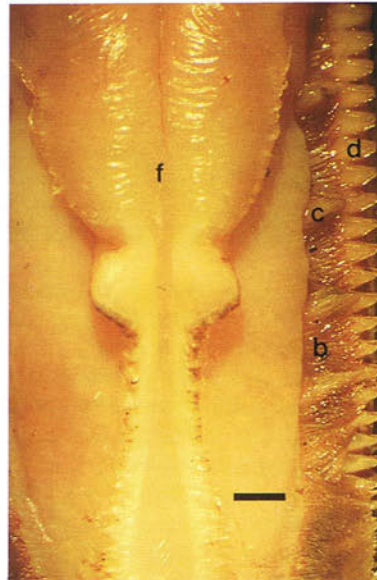
ing bristles (b) which are interspersed caudally with tooth-like processes (c). The bristles interdigitate with a double row of lamellae (d) on the bill. On the dorsal surface of the tongue is a shallow median groove (e) rostrally and a fleshy cushion or eminence (f) at the root.

105




105 Tongue of an adult duck. Dorsal view.

106



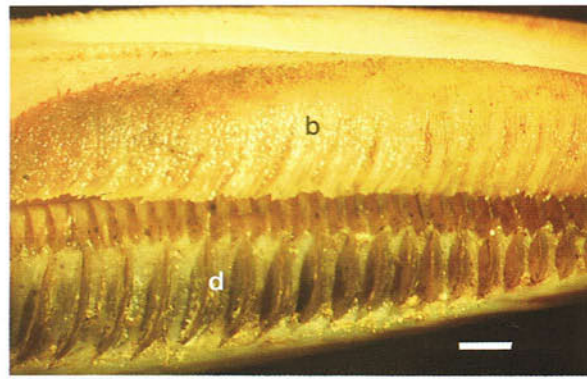
106 Tongue of an adult duck. Dorsal view. (Scale, 2 mm)

107



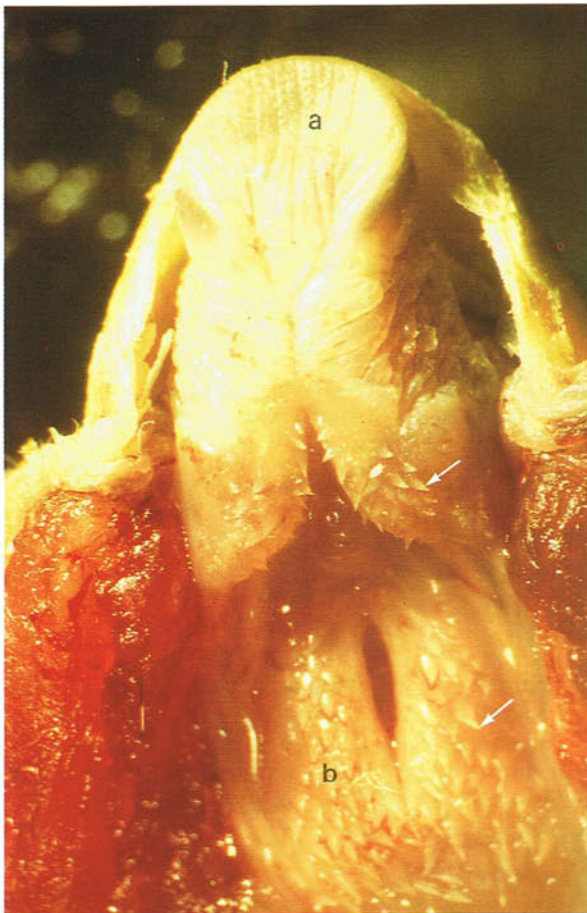107 Tongue of an adult duck. Lateral view.

108



108 Tongue of an adult duck. Lateral view. (Scale, 2 mm)

109



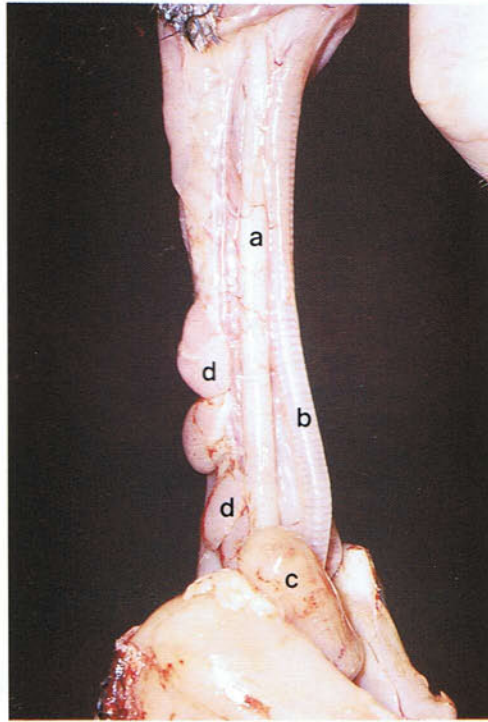
109 Floor of the oropharynx of an adult budgerigar. In this and other psittacine species the tongue (a) is short, blunt and fleshy and is capable of manipulating seed and nuts rather like a finger. As in the chicken there are numerous caudally-directed papillae (arrows) on the tongue and laryngeal mound (b) which help propel the food backwards into the oesophagus.

110



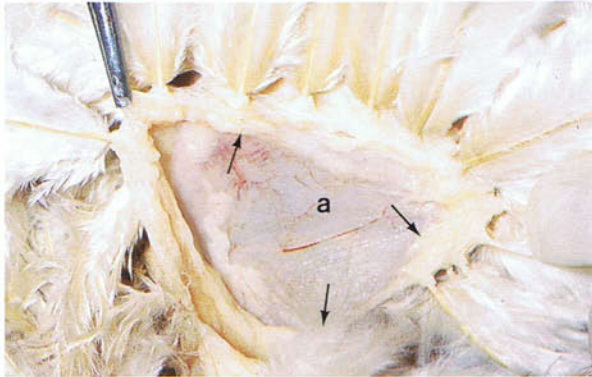
110 Roof of the oropharynx of an adult budgerigar. Ventral view. The single median slit on the palate is the choana (a) in the middle of which is the single opening of the combined auditory tubes. The rostral part of the palate has fleshy, vascular cushions (b) which are used with the tongue to hold food.

111



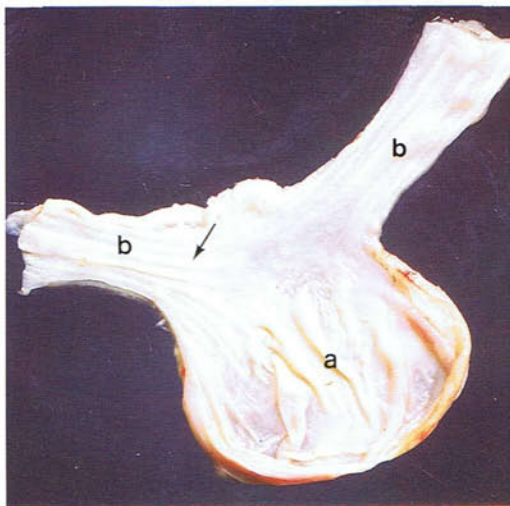
111 Neck of an 8-week-old chicken. Ventral view. The thin-walled oesophagus (a) lies for most of its course in the neck immediately below the skin and to the right of the trachea (b). At the thoracic inlet it enlarges ventrally to form the crop (c). (d) Lobes of thymus.

112



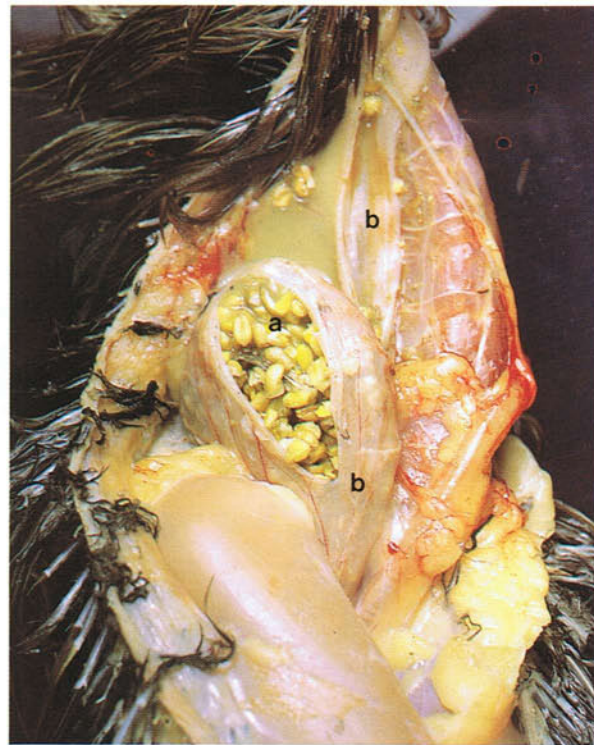
112 The relationship between the crop and skin in an adult chicken. An area of skin on the right side of the thoracic inlet has been removed to show its close attachment (arrows) to the crop (a). Part of this attachment is to two sheets of striated muscle which appear to form sling-like supports for the diverticulum. When full the crop can easily be palpated in the live bird.

113



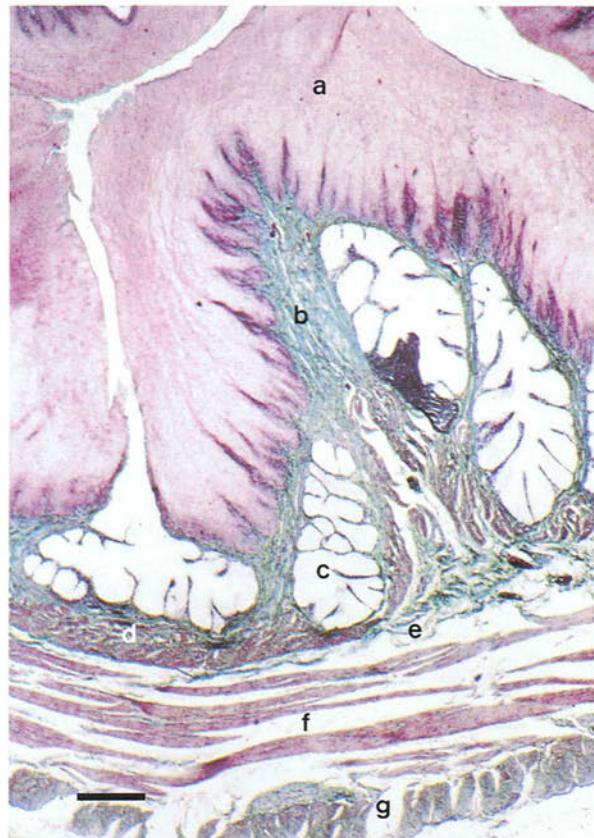
113 Interior of the oesophagus and crop of an adult chicken. The crop (a) is a ventral diverticulum of the oesophagus (b), which it divides into cervical and thoracic parts. Because the internal surface of the oesophagus is longitudinally folded (arrow), it is relatively distensible.

114 Full crop of an adult chicken. Ventral view. The function of the crop (a) is to store food when the gizzard compartment of the stomach is full, the food in the crop undergoing softening and swelling in preparation for chemical digestion in the stomach and intestines. When the gizzard is empty food bypasses the crop and travels directly to the stomach, the entrance to the crop being closed off. In the evisceration of poultry in the slaughter plant the oesophagus (b) is cut below the crop so that to avoid contamination of the carcass by food the bird is not fed for 2 to 8 hours before death.



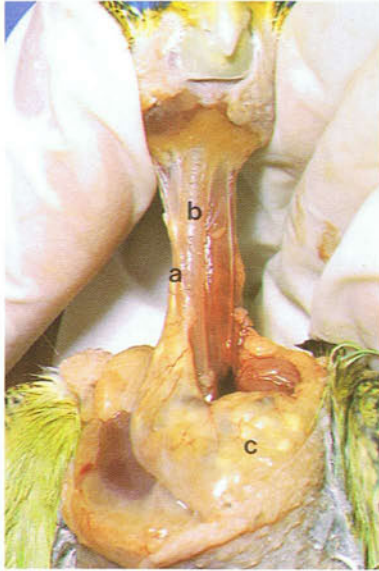
114

115 Light micrograph of a section through the entire wall of the oesophagus of a chicken. Masson's trichrome: (a) partly keratinized stratified squamous epithelium; (b) lamina propria; (c) mucous glands; (d) muscularis mucosae; (e) submucosa; (f) inner circular muscle layer; (g) outer longitudinal muscle layer. The structure of the crop resembles that of the oesophagus, except that the mucous glands are restricted to an area close to the oesophagus. (Scale, 250 μ m)

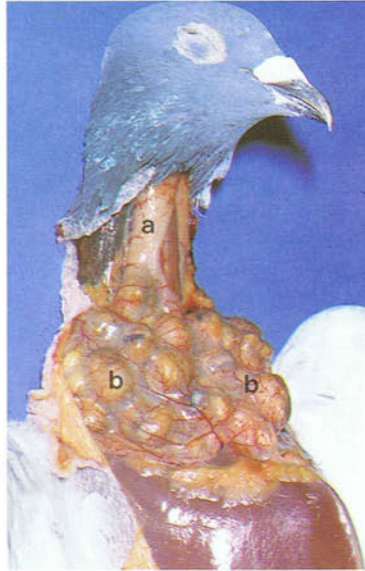


115

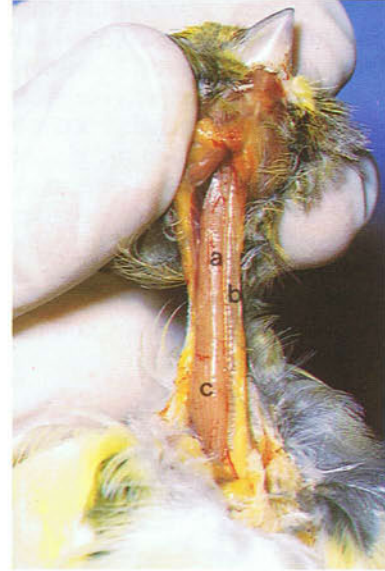116



117



118

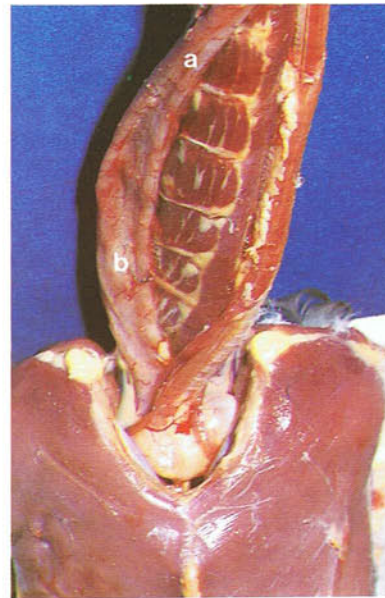

116 Oesophagus and crop of an adult budgerigar.

Ventral view. The cervical oesophagus (a) lies mainly to the right of the trachea (b); at the thoracic inlet it expands to form the crop (c), which, as in other psittacine species, is stretched transversely across the neck. Seed from the crop (or proventriculus) is regurgitated by budgerigars to feed their young. Food may also be regurgitated by the male as part of courtship behaviour. Regurgitation can even occur when a budgerigar is alone, in response either to its own image reflected in a mirror, or to a toy, or to the appearance of the owner.

117 Highly developed crop of an adult pigeon. Ventral view. As in the chicken the crop is a ventral diverticulum of the oesophagus (a), but unlike in the chicken it is divided into two large lateral sacs (b). The crop in both sexes of adult pigeon produces 'crop milk' which is regurgitated and fed to the young during the first few days after hatching. The 'milk' is a desquamation of fat-laden cells of the proliferated stratified squamous epithelium lining the crop and its manufacture is controlled by the pituitary hormone prolactin. While it resembles mammalian milk, it has no carbohydrates or calcium.

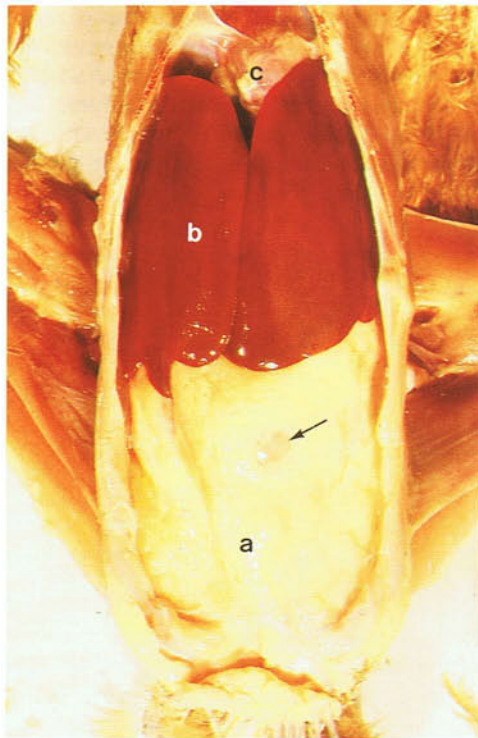
118 Crop of an adult canary. Ventral view. The oesophagus (a) lies to the right of the trachea (b), and close to the thoracic inlet. It forms a spindle-shaped swelling which represents the crop (c).



119

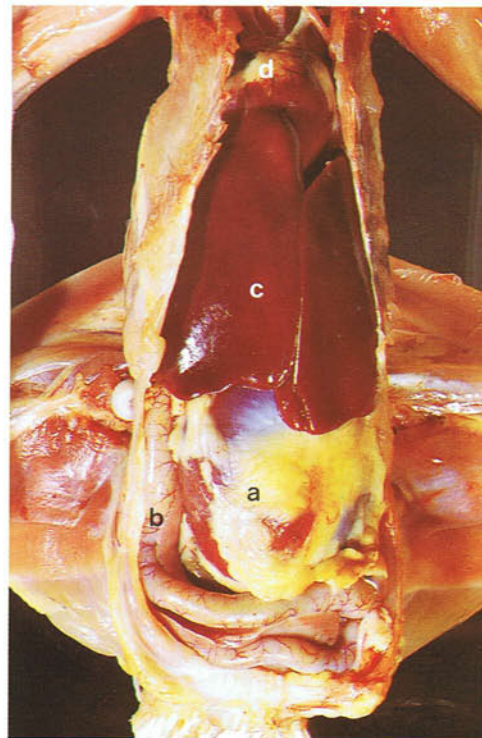
119 Oesophagus and crop of an adult duck. Ventral view. The oesophagus (a) close to the thoracic inlet, forms a relatively indistinct spindle-shaped widening (b) which represents the crop. In the duck the wall of the terminal part of the thoracic oesophagus contains an aggregated lymphoid nodule which is commonly referred to as the 'oesophageal tonsil'.

120



120 Ventral view of the thorax and abdomen of an adult chicken with the sternum and abdominal wall removed. Few viscera are visible because the abdominal contents are covered ventrally by a double-layered fat-laden fold of peritoneum, the posthepatic septum (a). The only organs which are not covered are the right and left lobes of the liver (b) and the heart (c). Part of the gizzard (arrow) can be seen suspended in the posthepatic septum. Note that in birds no diaphragm separates the thorax from the abdomen.

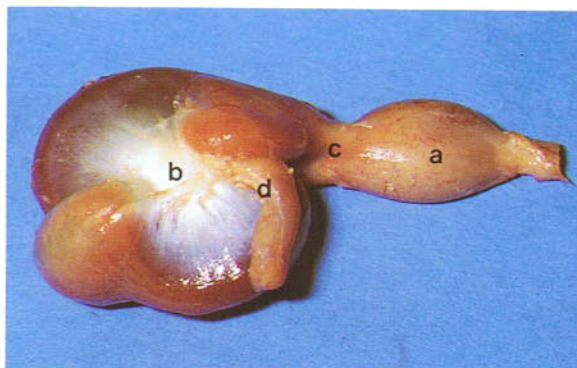
121



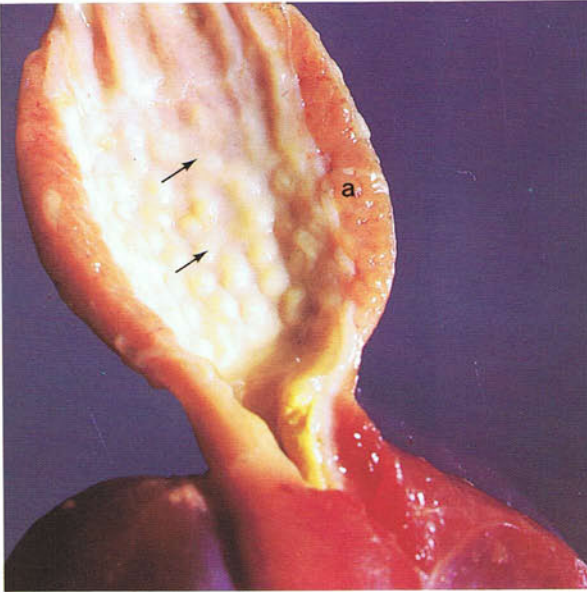
121 Ventral view of the thoracoabdominal cavity of the adult chicken shown in 120, but with the posthepatic septum removed. On the left side of the abdomen lies the gizzard (a) and on the right side lies the narrow U-shaped loop of the duodenum (b). In all species this is the most ventrally-situated part of the intestinal tract. Although the gizzard is usually covered by a fat-laden posthepatic septum, it can still be palpated, except in the smallest species, in the live bird. The heart (d) is clearly visible above the liver (c).

122 Stomach of an 8-week-old chicken. Right lateral view. The stomach consists mainly of a cranial glandular compartment or proventriculus (a), and a caudal muscular compartment or gizzard (b). Between the two compartments is the intermediate zone which in the domestic birds is marked on the outside by a constriction, the isthmus (c). The pyloric part of the stomach (d) arises from the right face of the gizzard and connects the gizzard with the duodenum. The stomach of the chicken, like that of the other domestic birds, is characteristic of species which feed on relatively indigestible types of food that have to be physically broken down prior to chemical digestion. Typically in these birds the gizzard is highly developed with a very thick muscular coat, and the proventriculus and gizzard are clearly set off from one another.

122

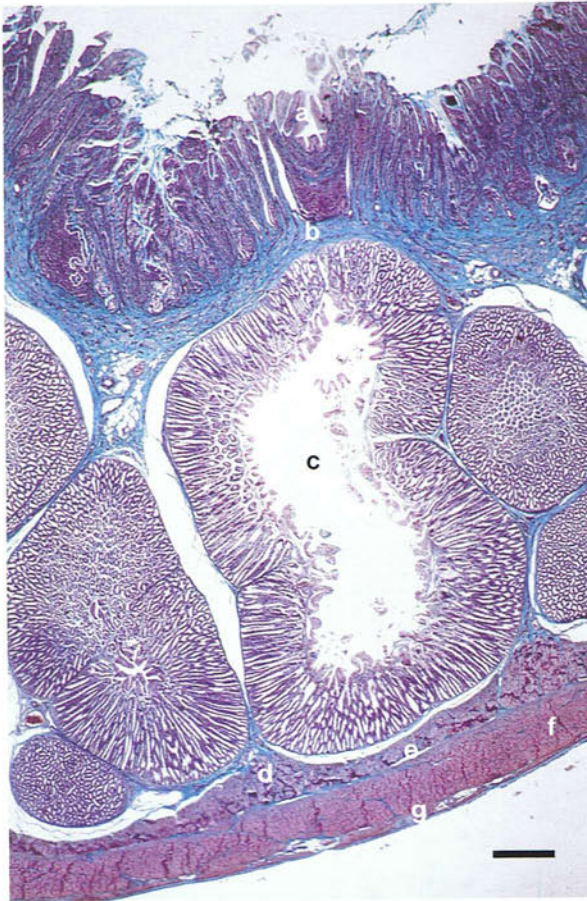

123



123 Interior of the proventriculus of an adult chicken. Projecting into the lumen are well-developed papillae (arrows) at the tops of which open the compound gastric glands. The glands form a thick layer (a) in the wall of the proventriculus. Gastric proteolysis occurs principally in the gizzard where the pH is low (1.5-2.5).

124

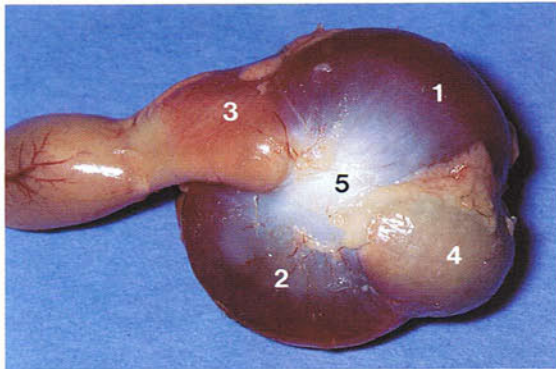


124 Light micrograph of a section through the entire wall of the proventriculus of a chicken. Masson's trichrome: (a) columnar mucus-secreting epithelium; (b) lamina propria; (c) multilobular glands of the lamina propria; (d) muscularis mucosae; (e) submucosa; (f) inner circular muscle layer; (g) outer longitudinal muscle layer. The muscularis mucosae surround the glands of the lamina propria. The glands consist mainly of closely-packed alveoli radiating out from a central cavity. The central cavity is drained by a secondary duct, all the secondary ducts of a gland uniting to form a primary duct which opens into the lumen of the organ. The glandular epithelium of the alveoli is lined mainly by one type of cell, the oxynticopeptic cell, which secretes both pepsin and hydrochloric acid. (Scale, 500 μ m)

125 and 126 Gizzard of a chicken. Most of the wall of the gizzard is made up of smooth muscle rich in myoglobin and arranged into four semi-autonomous masses. These are the dark-coloured caudodorsal (1) and cranioventral (2) thick muscles, and the lighter-coloured craniodorsal (3) and caudoventral

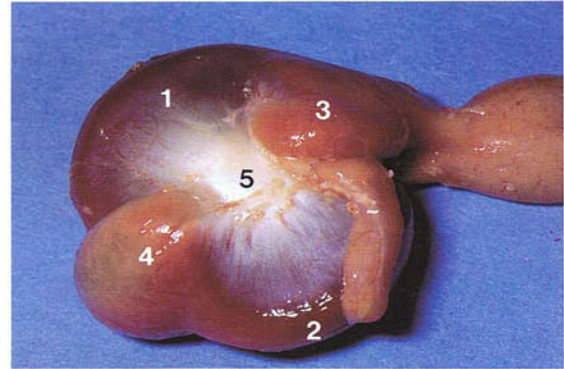
(4) thin muscles. The muscles attach to the right and left tendinous centres (5) in the lateral walls of the gizzard. Because the muscles are asymmetrically arranged, rotatory as well as crushing movements are set up when the gizzard contracts.

125



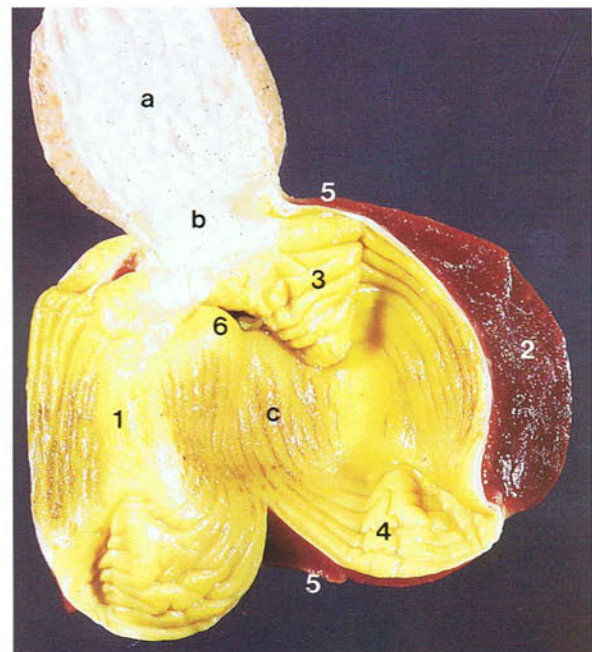
125 Gizzard of an 8-week-old chicken. Left lateral view.

126



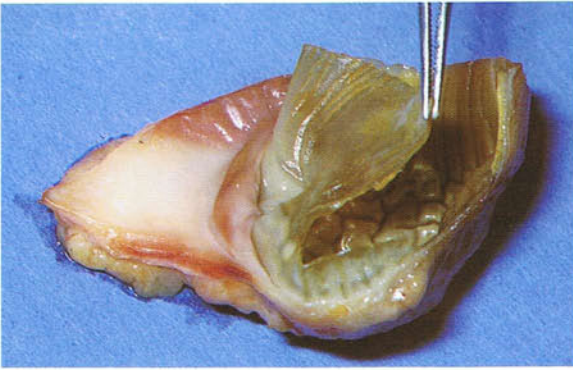126 Gizzard of an 8-week-old chicken. Right lateral view.

127 Interior of the stomach of an adult chicken. Separating the proventriculus (a) and gizzard (c) is the intermediate zone (b) which is characterized by a histological structure intermediate to that of the proventriculus and gizzard. Compound glands are absent here and the internal surface is relatively smooth. The bulk of the gizzard is formed by the body (1), in the walls of which are the thick muscles (2). At either end of the gizzard are the cranial (3) and caudal (4) blind sacs, in the walls of which are the craniodorsal and caudoventral thin muscles (5). The entrance (6) to the pyloric part of the stomach and the duodenum lies in the cranial part of the gizzard. Lining the inner surface of the gizzard is a hardened membrane, the cuticle (sometimes called the koilin layer), which is a carbohydrate-protein complex secreted by the gizzard glands. The membrane is especially well-developed in birds, such as the domestic species, which feed on relatively hard items of food. In these birds it is asymmetrically developed, being thickest opposite the thick muscles of the body of the gizzard and thinnest opposite the thin muscles of the cranial and caudal blind sacs. Its green or yellow colour is due to bile regurgitated from the duodenum via the pylorus.



127

128

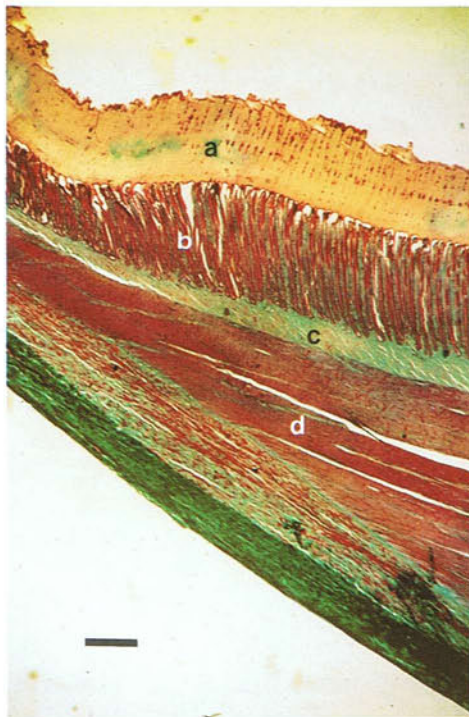


128 Gizzard cuticle of an adult chicken. The cuticle is a secretion of the mucosa and can therefore be easily stripped away from the organ. In the poultry slaughter plant the cuticle has to be removed by machine before the gizzard is added to the giblets.

129 and 130 Histological structure of the chicken gizzard: (a) cuticle; (b) glands in the mucous membrane; (c) submucosa; (d) muscle. The cuticle is a carbohydrate-protein complex secreted by the mucosal glands and the surface epithelium. It is composed of vertical rods (arrows) and horizontal matrix. The vertical rods are secreted by the muco-

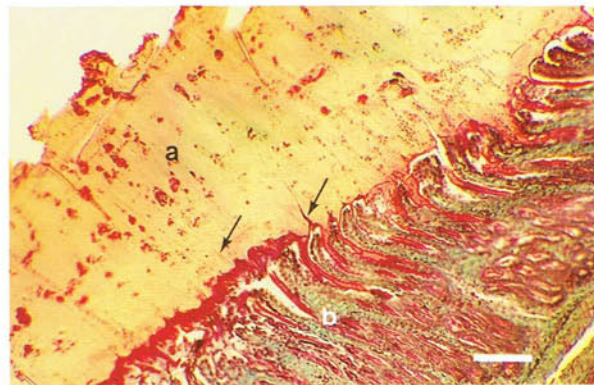
sal glands, the secretion hardening within the lumen as a thickening perpendicular to the surface. The horizontal matrix between the rods is a secretion of the surface epithelium which hardens after spreading around the rods. Within the horizontal matrix are trapped desquamated cells of the surface epithelium.

129



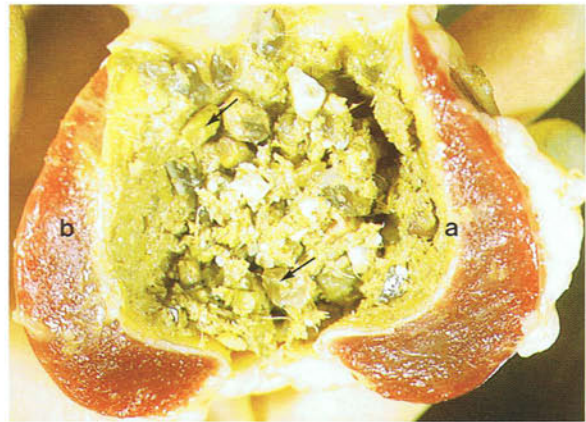129 Light micrograph of a section through the entire wall of the gizzard of a chicken. Masson's trichrome. (Scale, 250 μ m)

130



130 Light micrograph of the inner layers of the gizzard of a chicken. Masson's trichrome. (Scale, 100 μ m)

131 Gizzard contents in an adult chicken. Large amounts of grit (arrows) are mixed up with the food. Grit is also ingested by the other domestic species, because like the chicken they feed on relatively coarse material which must be reduced before chemical digestion. The need to take in grit has led to problems in the Mute Swan (*Cygnus olor*) which frequently mistakes the small lead weights used by anglers to sink their fishing lines as a form of grit and ingests them. The weights are slowly eroded in the gizzard and the resulting lead salts absorbed in the small intestine to cause lead poisoning. In this photograph the three factors which are important in the physical phase of gastric digestion in the domestic birds are shown. They are the grit in the lumen, the hardened cuticle lining (a), and the massively developed semiautonomous muscles (b).

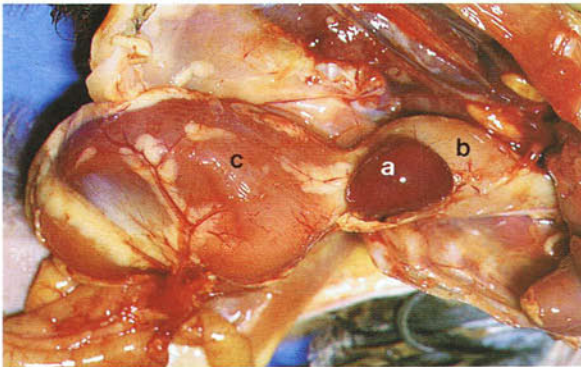


131

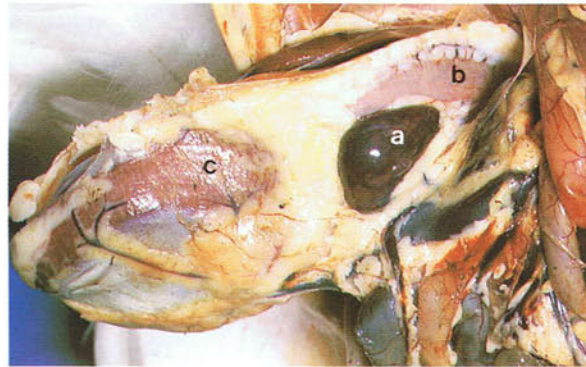
132-134 Spleens. In all birds the dark-red spleen (a) lies on the right side of the junction between the proventriculus (b) and gizzard (c). The shape varies from spherical in the chicken, to triangular in the

duck, to elongated in the pigeon and canary. While having a similar function to that of mammals, the spleen does not appear to be important in storing blood.

132



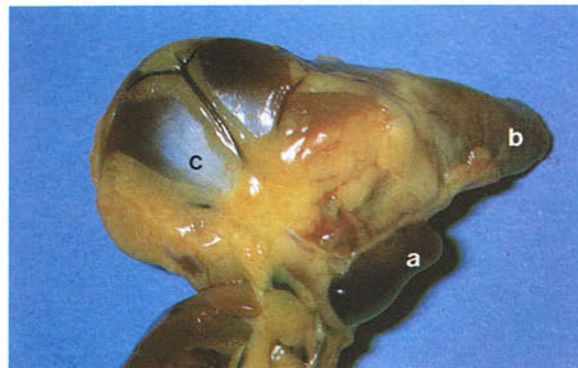132 Spleen of a 6-week-old chicken.



133

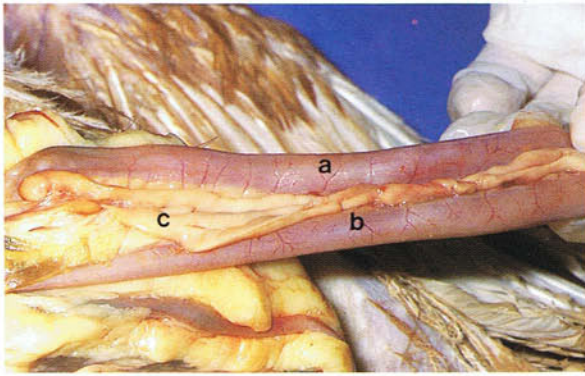
133 Spleen of an adult duck.

134



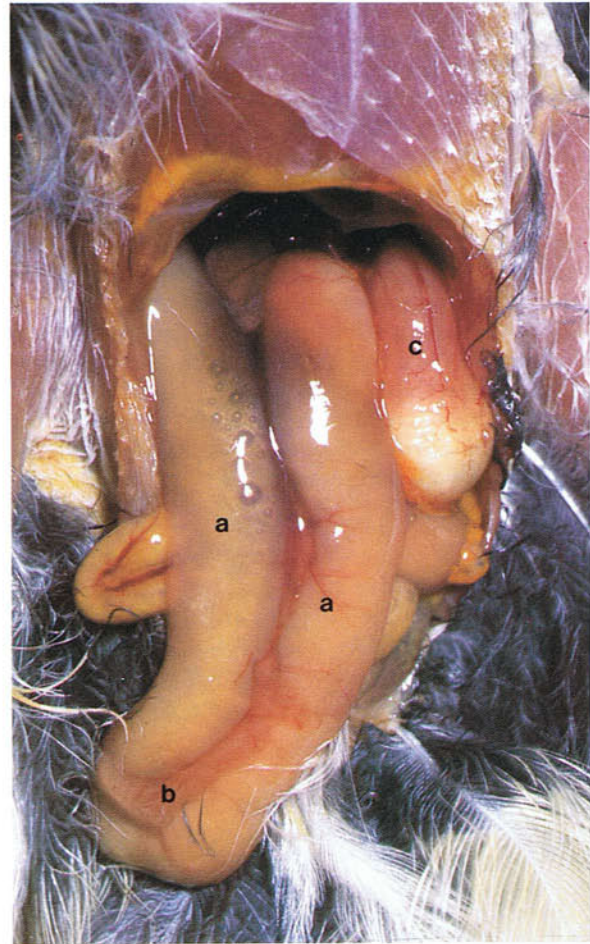
134 Spleen of an adult pigeon.

135



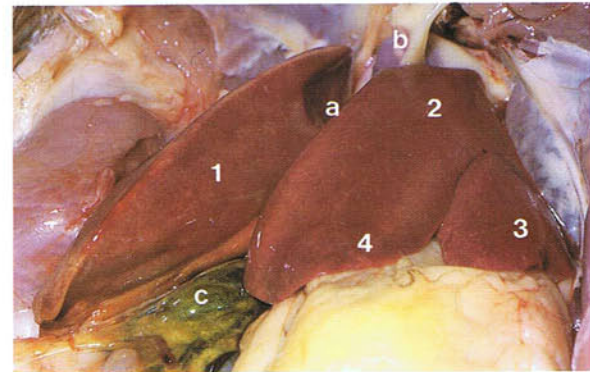
135 Duodenum and pancreas of an adult chicken. Ventral view. The duodenum is arranged as a narrow U-shaped loop with descending (a) and ascending (b) parts, the two parts being held closely together by mesentery. The duodenal loop encloses the pancreas (c). It is always the most ventral part of the intestinal tract (see 121). Within the pale red or yellow pancreas of the chicken dorsal, ventral, third and splenic lobes have been identified.

136 Duodenal loop of an adult canary. Ventral view. As in other avian species the duodenal loop (a) is the most ventrally situated part of the intestinal tract and encloses the pancreas (b). Compared with the narrow duodenal loop of the chicken, however, that of the canary is extremely broad. See also the gizzard (c).



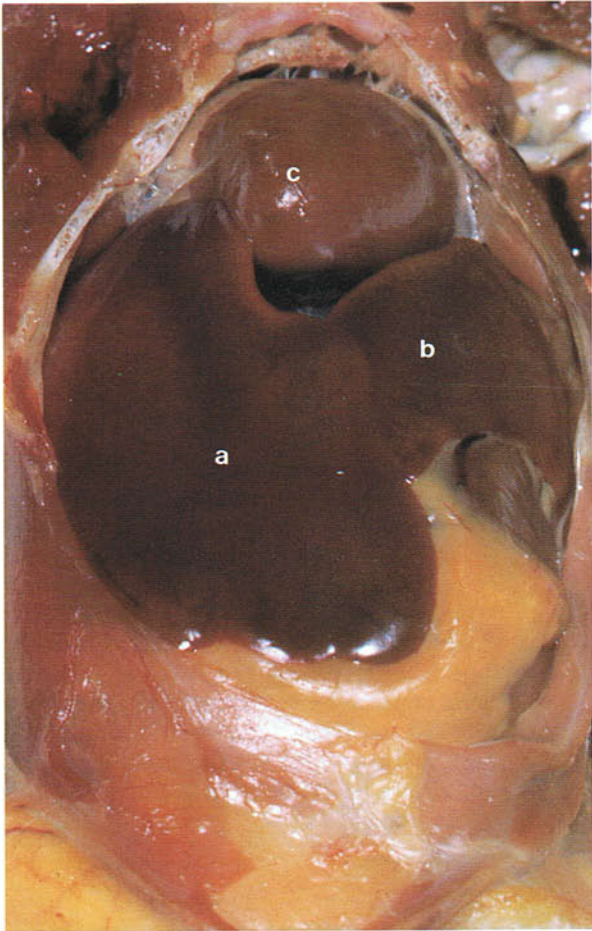
136

137 Liver of a 5-week-old chicken. Ventral view. In birds the liver (a) lies in the cranial part of the thoracoabdominal cavity, its cranioventral portions surrounding the apex of the heart. It consists of right (1) and left (2) lobes, the two lobes in the chicken being almost equal in size. The left lobe in the chicken and turkey is subdivided into lateral (3) and medial (4) parts. In large birds it may be possible to palpate the liver beyond the edge of the sternum. The edges of the liver are normally thin and sharp but if the liver is enlarged they may become rounded. The colour of the liver depends on the nutritional state of the bird and, while it is frequently red-brown as in the photograph, it may be light brown or, if the bird is on a high-fat diet, yellow. The caudal vena cava (b) passes through the cranial part of the right lobe and receives the hepatic veins. The gall bladder (c) lies on the visceral surface of the right lobe. In the poultry slaughter plant the gall bladder is frequently cut by accident during post-mortem processing and this is a common cause of carcass contamination. The liver, but not the gall bladder, forms part of the giblets.



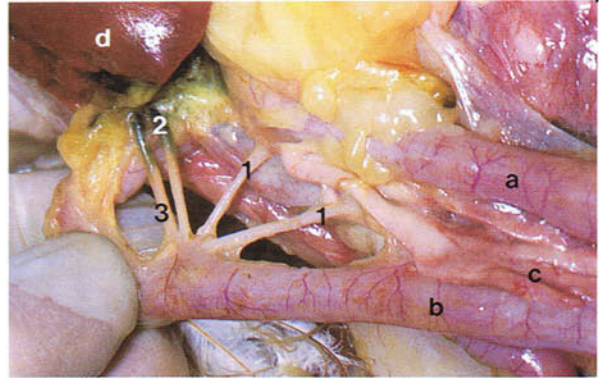
137

138



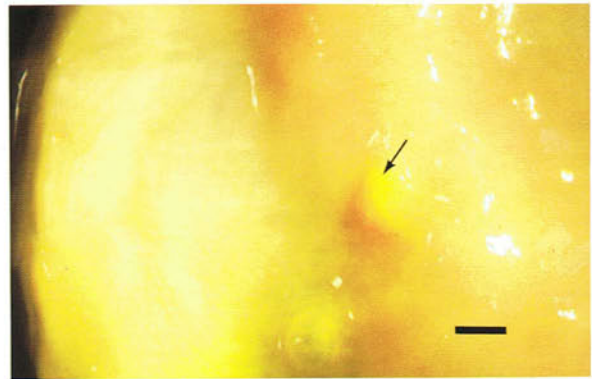
138 Liver of an adult pigeon. Ventral view. In this species, as in the duck and goose, the right liver lobe (a) is very much larger than the left (b), and the left lobe is not subdivided. A gall bladder is absent in the pigeon and budgerigar. It is present, however, in some species of parrot. Heart (c).

140 Mucous membrane lining the distal part of the duodenum of an adult chicken. The papilla on which the pancreatic and bile ducts open is indicated by an arrow. (Scale, 2 mm)



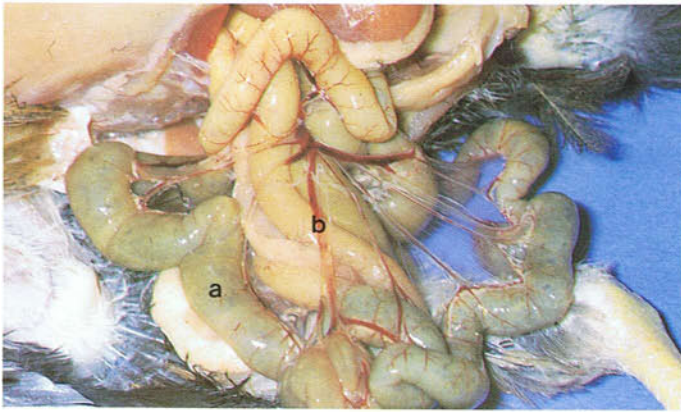
139

139 Pancreatic and bile ducts of an adult chicken. The pancreatic (1) and bile (2,3) ducts open into the distal part of the ascending limb of the duodenum (b). In the chicken the common hepatoenteric duct (2) drains the right and left lobes of the liver and is formed by the union of the right and left hepatic ducts on the visceral surface of the right lobe. The right hepatic duct gives off a branch which enters the gall bladder. The gall bladder is drained by the cysticoenteric duct (3). In the pigeon, which has no gall bladder, there are two hepatoenteric ducts, the right duct opening into the middle of the ascending limb of the duodenum and the better developed left duct opening into the proximal part of the descending limb. See also descending limb of the duodenal loop (a), pancreas (c), liver (d).



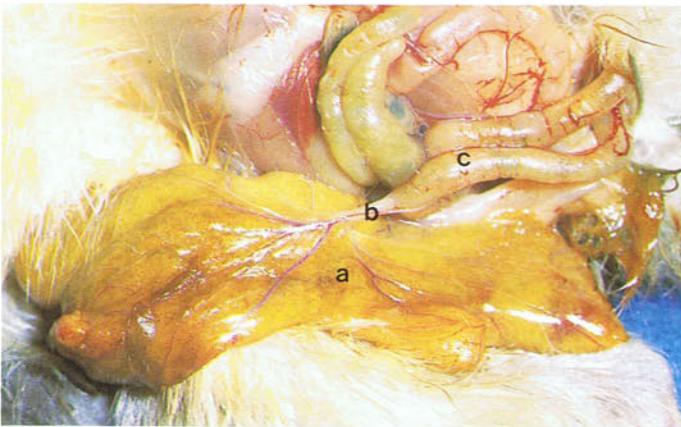
140

141




141 Jejunum and ileum of a 6-week-old chicken. The jejunum and ileum (a) in the chicken and turkey are relatively uncomplicated, unlike in most species of birds, and form short, garland-like coils at the edge of the long dorsal mesentery. Within the mesentery are the cranial mesenteric artery and vein and their branches (b).

142



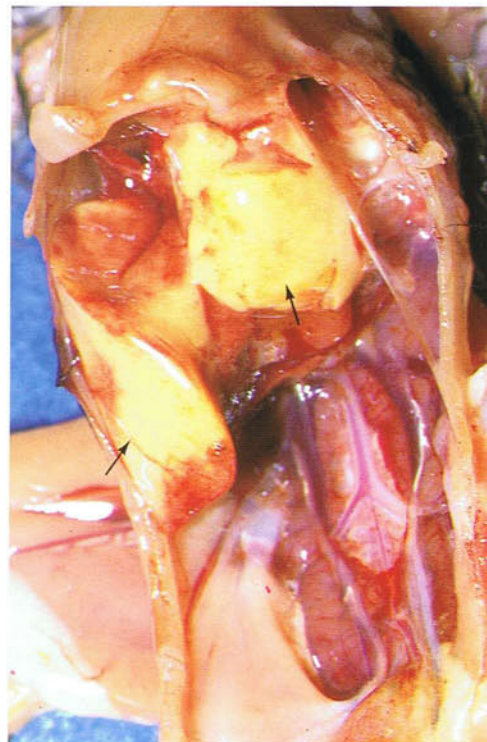142 Yolk sac of a 3-day-old chicken. The yolk sac (a) and yolk duct (b) open into the antimesenteric side of the small intestine (c) opposite the terminal branches of the cranial mesenteric artery. They are used arbitrarily to distinguish the jejunum proximally from the ileum distally. About 10 days after hatching, the residual yolk has been absorbed into the bloodstream either through the wall of the sac or through the wall of the gizzard via the small intestine. When empty, the yolk sac is converted into scar tissue.

143



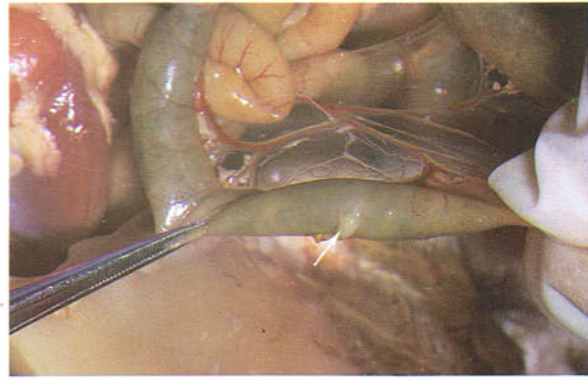
143 Yolk sac of a day-old chicken to show the normal appearance of yolk.

144 Liver of a day-old chicken. Ventral view. At hatching the liver lobes (arrows) have a bright yellow colour because of the pigments they absorb along with the lipids of the yolk. The colour gradually changes to the mahogany-brown of the adult liver between days 8 and 14.



144

145 Vitelline diverticulum (formerly Meckel's diverticulum) of a 6-week-old chicken. The diverticulum (arrow) is the remnant of the yolk duct and opens into the lumen of the small intestine on a papilla. The opening is surrounded by a sphincter. In the chicken the vitelline diverticulum has been found to contribute to extramedullary myelopoiesis, and a lymphoepithelial function has been suggested for it.

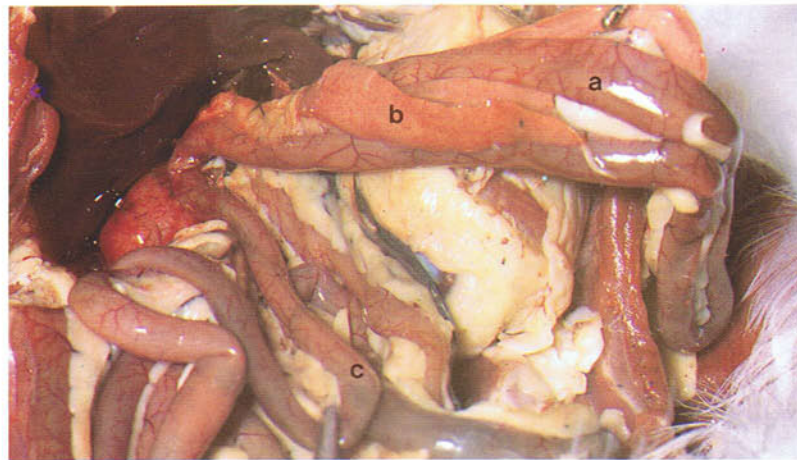


145

146 and 147 Small intestine of an adult domestic duck. The small intestine of the duck compared with that of the chicken is much more typical of birds in that the jejunum and ileum are arranged into a number of U-shaped permanent loops, the two limbs of each loop being joined together by dorsal mesentery. The most proximal loop of the small intestine is the duodenal loop (a) which en-

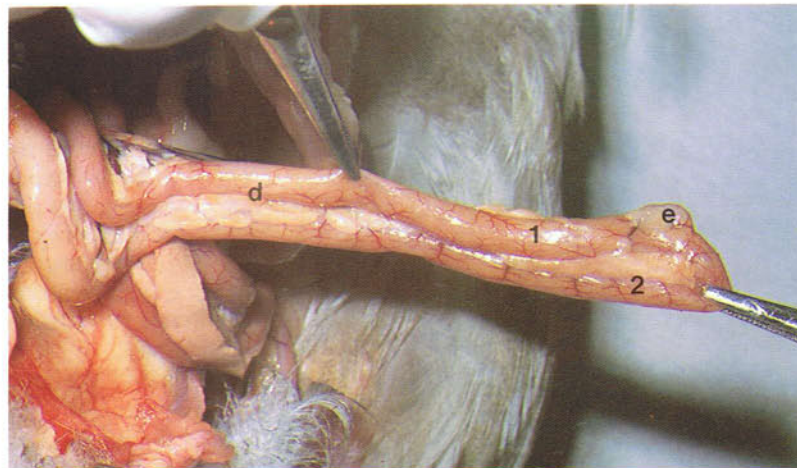clozes the pancreas (b). It is succeeded by a number of jejunal loops (c) and ileal loops. The jejunal and ileal loops are separated by the axial loop (d) which carries near its apex the vitelline diverticulum (e). The proximal limb (1) of the axial loop, therefore, is formed by the terminal part of the jejunum, while the distal limb (2) is formed by the initial part of the ileum.

146 Duodenal and jejunal loops of the small intestine of an adult duck. Ventral view.



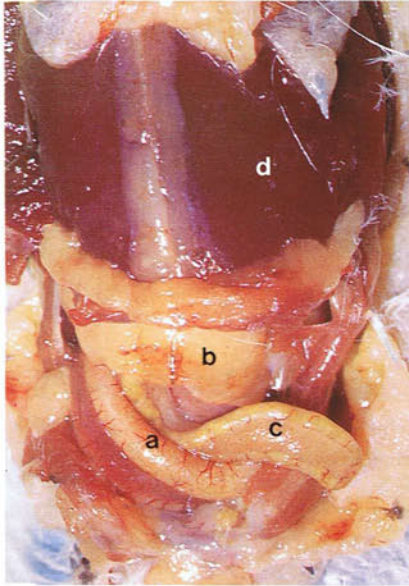
146

147 Axial loop of the small intestine of an adult duck. Ventral view.



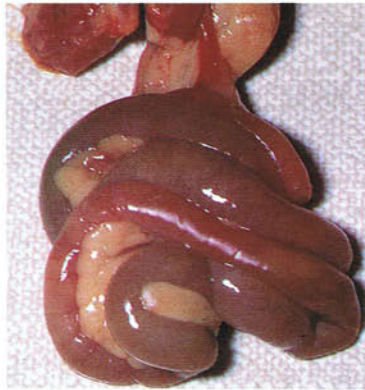147

148



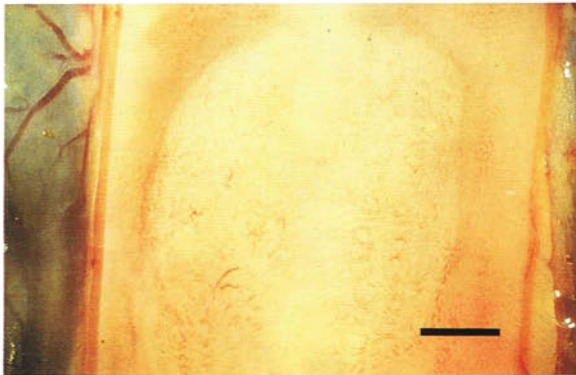
148 Abdominal cavity of an adult budgerigar. Ventral view. As in all other species the duodenal loop (a) is the most ventral part of the intestinal tract and lies to the right of the gizzard (b). In species like the budgerigar, pigeon, canary, duck and goose in which the jejunum and ileum are arranged in U-shaped loops, the most distal loop of the ileum (c) lies immediately dorsal to and to the left of the duodenum. It is therefore referred to as the supra-duodenal loop. Mid-ventral abdominal incisions may damage this loop. See also liver (d).

149

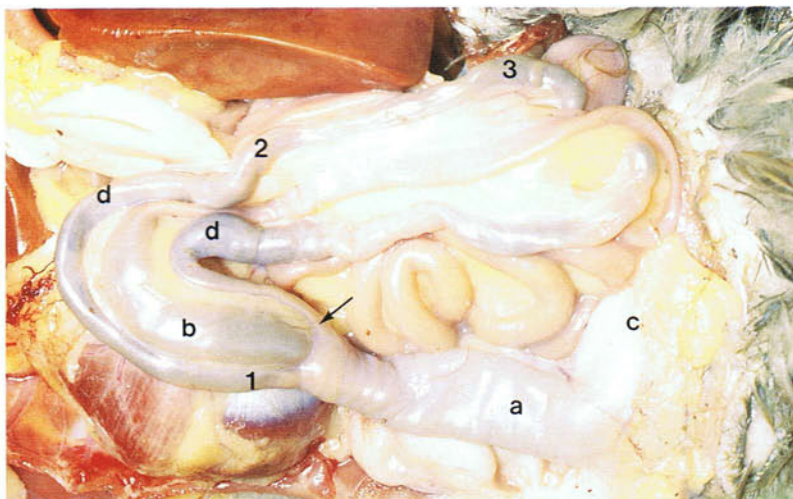


149 Small intestine of an adult pigeon. In this species the jejunum and ileum basically form three loops. The first and third loops are relatively short. The second loop shown here is enormously expanded and forms a cone-shaped mass with outer centripetal coils and inner centrifugal coils held together by mesentery.

150



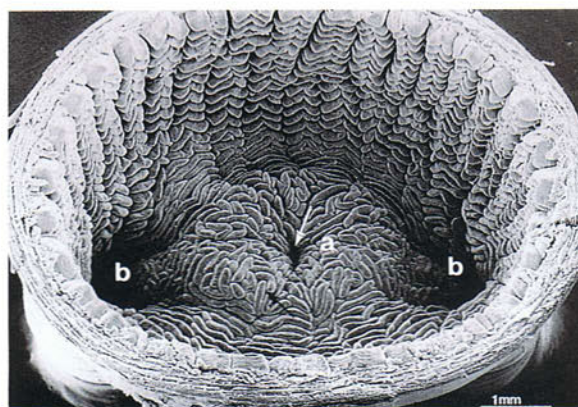
150 Aggregated lymphoid nodule in the small intestine of an adult duck. View from the mucosal surface. The aggregated lymphoid nodules of the small intestine in the duck and goose are arranged as annular bands which can be identified with the naked eye. In the duck there are four bands, the one in the photograph, verified by histology, occurring in the terminal part of the ileum. In the goose there are seven annular bands. Aggregated lymphoid nodules are also reported to be present in the small intestine of the chicken although they are not arranged as rings. One of these has been described as occurring regularly in the terminal part of the ileum about 10 cm from the ileorectal junction. Other lymphoid tissue is shown in **132, 133, 134, 154, 208, 209** and **234.** (Scale, 2 mm)



151 Large intestine of an adult duck. Ventral view. The large intestine consists of the rectum and right and left caeca. The rectum (a) extends from the ileum (b) cranially to the cloaca (c) caudally. The right and left caeca (d) arise from the lateral walls of the rectum (arrow) close to the junction with the ileum. The caeca in the duck, goose, turkey and chicken are extremely well-developed and are mostly dark green in colour. They extend at first

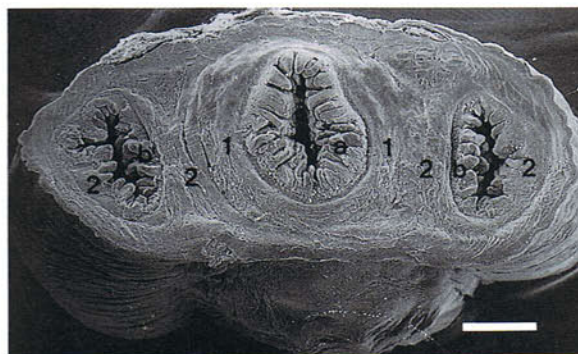cranially before turning caudally to end close to the cloaca. Each caecum can be divided externally into a short proximal neck part or base (1), a long thin-walled middle part or body (2), and a short distal part or apex (3). Enlarged forms of caeca like these play a role in the bacterial fermentation of cellulose and along with the rectum are also important in water reabsorption from ureteral urine.

152 Scanning electron micrograph of the ileocaecorectal junction of an adult duck. View from the rectum. The terminal part of the ileum, the lumen of which is indicated by a white arrow, protrudes into the rectal lumen as the ileal papilla (a). The right and left caeca (b) open into the rectum lateral to the ileal papilla. Covering the entire intestinal tract are mucosal villi (black arrow) which act to increase the surface area of the gut available for the absorption of nutrients. (Scale, 1 mm). From Mahdi, A.H. and McLelland, J. (1988). *J. Anat.* **161**, 133-142.



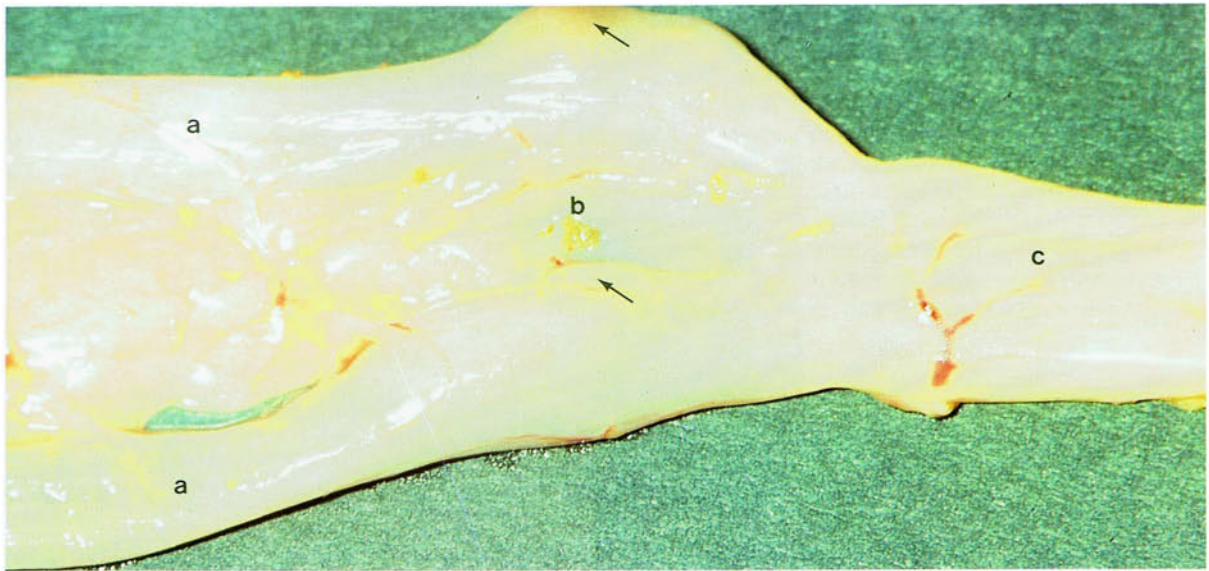
152

153 Scanning electron micrograph of a transverse section through the ileocaecorectal junction of an adult duck. Surrounding the orifices of the ileum (a) and the right and left caeca (b) is thickened circular muscle forming the ileal sphincter (1) and the right and left caecal sphincters (2). The musculature of the three sphincters is continuous. (Scale, 1 mm)



153

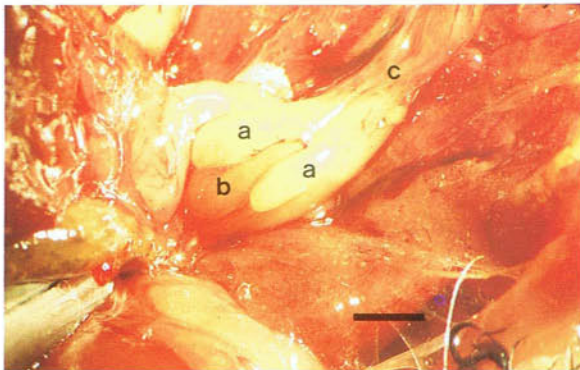
154



154 Lymphoid tissue in the caeca of an adult chicken. At the origins of the caeca (a) are large aggregated nodules, the caecal tonsils (arrows), which can easily be identified with the naked eye. Each tonsil

extends over much of the circumference of the caecum and protrudes for some distance into its lumen. See also ileum (b), rectum (c).

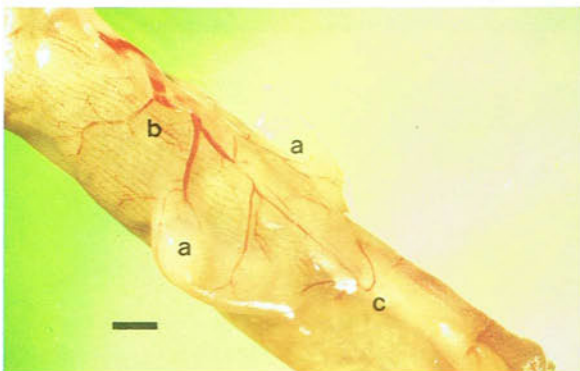
155



155 and 156 Caeca of the canary and pigeon. In these species the right and left caeca (a) are vestigial and extend forwards from the junction between the ileum (b) and the rectum (c). There is no ileal papilla. Vestigial caeca usually contain large amounts of lymphoid tissue. Caeca are absent in the budgerigar.

155 Caeca of an adult canary. (Scale, 1 mm)

156

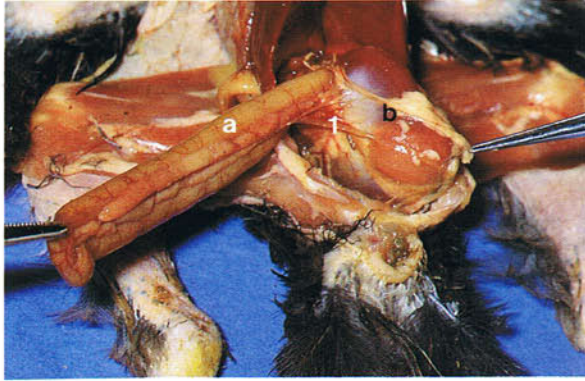


156 Caeca of an adult pigeon. (Scale, 1 mm)

157-160 Intestinal peritoneal ligaments of a 6-week-old chicken. The duodenum (a) is connected to the gizzard (b) by the gastroduodenal ligament (1), to the liver (c) by the duodenohepatic ligament (2),

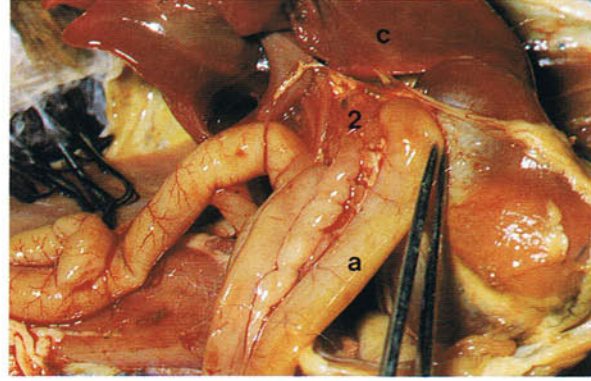
and to the caecum (d) by the duodeno-caecal ligament (3). The ileum (e) is connected to the caecum (d) by the ileocaecal ligament (4).

157



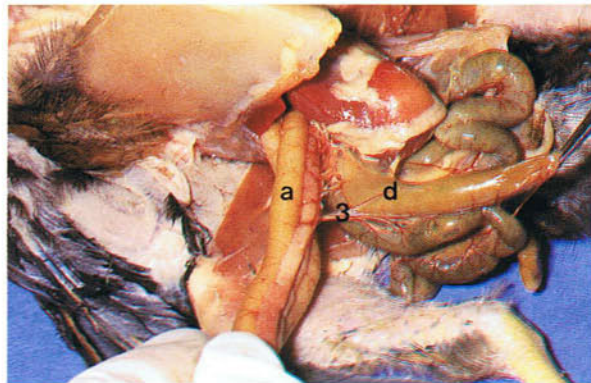
157 Gastroduodenal ligament in a 6-week-old chicken.

158



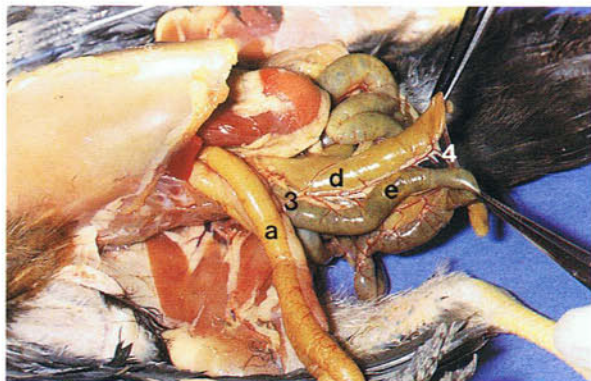
158 Duodenohepatic ligament in a 6-week-old chicken.

159 Duodeno-caecal ligament in a 6-week-old chicken.



159

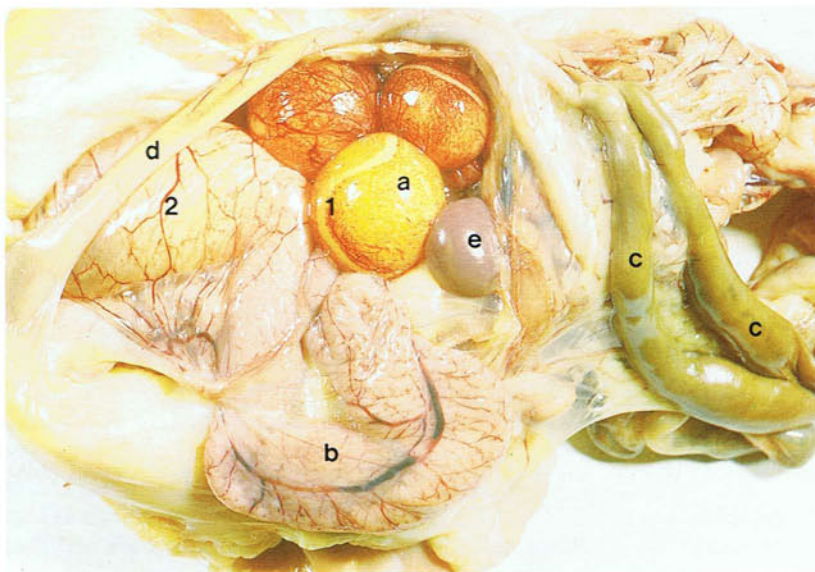
160 Ileocaecal ligament in a 6-week-old chicken.



160

Urogenital system

161



161 Ovary and oviduct of an in-lay chicken. Right lateral view: (a) ovary; (b) oviduct; (c) right and left caeca; (d) rectum; (e) spleen. While left and right gonads and oviducts are present in the avian embryo, in most species only the left ovary and oviduct develop after hatching and become functional. In this photograph, three large, mature, highly vascular follicles can be seen suspended from the

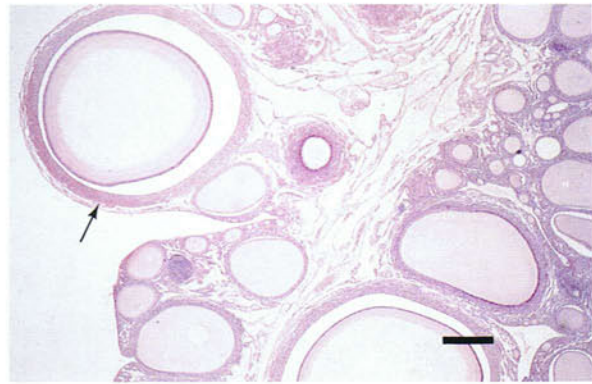
ventral surface of the ovary. On the surface of the follicles is a white avascular band, the stigma (1), where at ovulation the wall of the follicle splits to release the oocyte. The oviduct lies in the left dorsal part of the body cavity to the left of the gut mesentery and is pink due to its great vascularity. An egg is present in the uterus (2). Paired ovaries and oviducts may be found in some birds of prey.

162

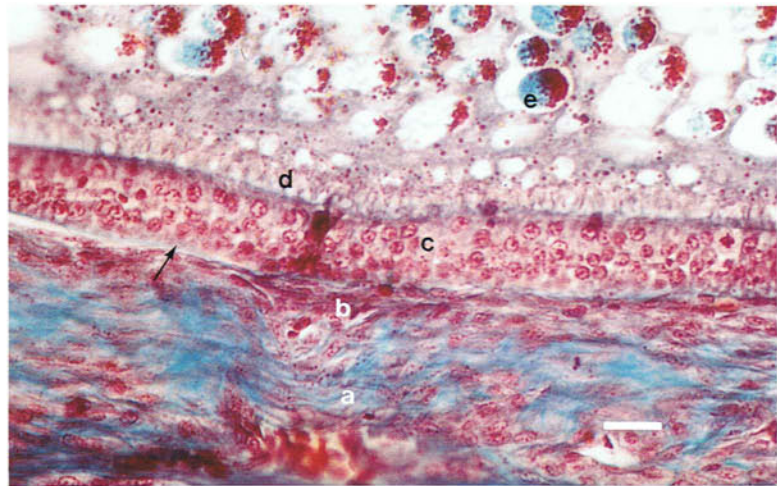


162 Ovary of an in-lay chicken. Modern breeds of chickens come into lay at about 18-21 weeks. The ovary then weighs about 60 g and resembles a bunch of grapes with four or five large, mature follicles (a) and thousands of smaller immature follicles (b). The yellow colour of the mature follicles is due to the presence of yolk, the protein and lipids of which are manufactured in the liver and travel in the bloodstream to the oocyte. About two hours before ovulation the primary oocyte in the follicle undergoes the first maturation division to form the secondary oocyte. Ovulation takes place under the influence of luteinizing hormone and in the chicken generally occurs about 30 minutes after an egg is laid. Immediately after ovulation the follicle becomes a thin-walled sac, the post-ovulatory follicle (arrow), which in the chicken regresses in about 10 days. Unlike in mammals there is no corpus luteum.

163 Light micrograph of the ovary of a chicken. Haematoxylin and eosin. There is little distinction between the cortex and medulla. Follicles in many stages of development are visible. One large follicle (arrow) lies at the surface of the ovary and will soon be suspended from the surface by a stalk or pedicle of connective tissue and smooth muscle. (Scale, 500 μ m)



163

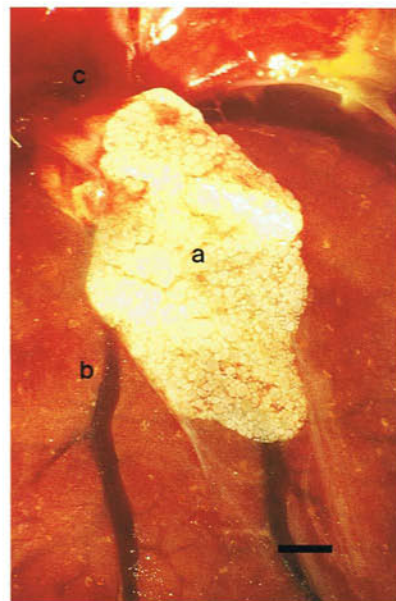


164

164 Light micrograph of the wall of a mature follicle of a chicken. Masson's trichrome. Four layers of the wall are visible. The relatively wide theca externa (a) and the much narrower theca interna (b) are composed mainly of collagen fibres and fibroblast-like cells. The stratum granulosum (c) is the inner epithelium of the follicle and is frequently pseudostratified. At the junction (arrow) of the stratum granulosum and the theca interna there is a thick basal lamina. The zona radiata (d) rests on the surface of the stratum granulosum and is a mixture of the secretions and radial processes of the granulosa cells and the radial processes of the oocyte cytolemma. Within the oocyte, yolk droplets (e) can be seen. Outside the theca externa, but not

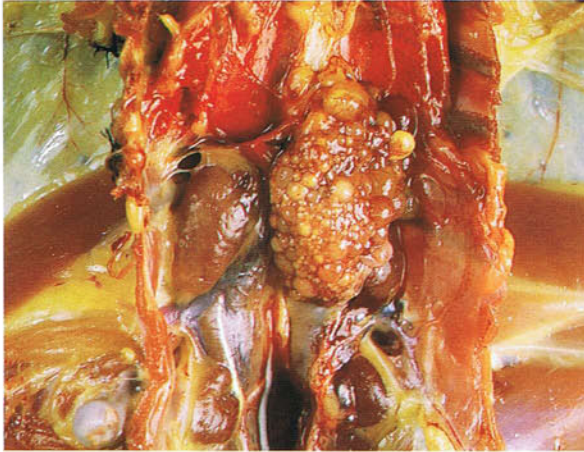shown in the photograph, are a superficial tunic of connective tissue and the superficial germinal epithelium of peritoneal mesothelial cells. (Scale, 10 μ m)

165 Juvenile ovary of a canary. Ventral view. The ovary (a) lies in the dorsal part of the body cavity adjacent to the cranial extremity of the left kidney (b) and the caudal part of the left lung (c) and has a finely granular surface. Individual follicles cannot be recognized. Canaries breed from 1 to 4 years, budgerigars from 12 months, and pigeons from 7 to 8 months. (Scale, 1 mm)



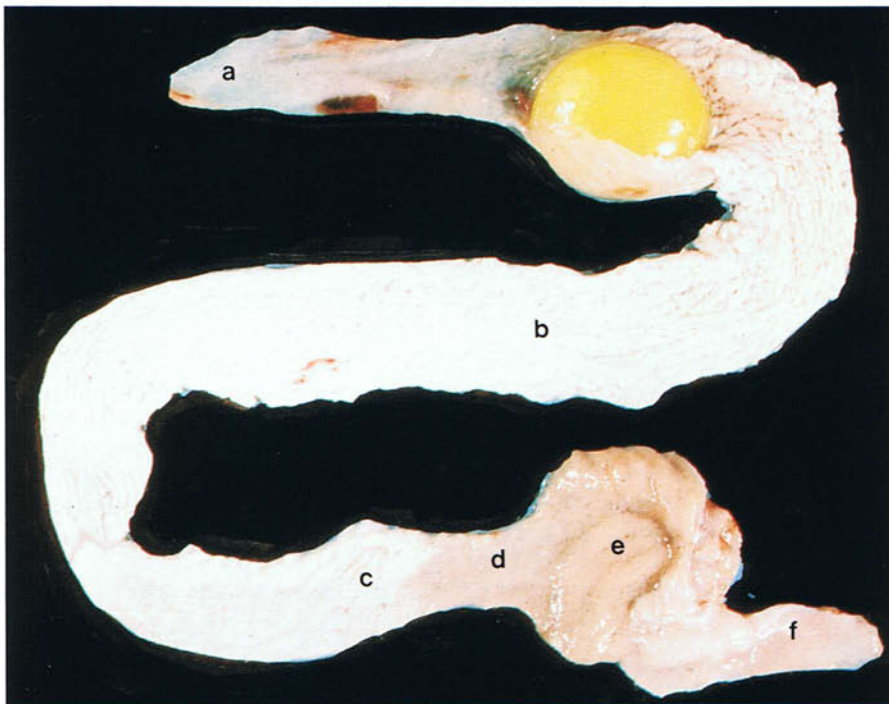
165

166



166 Inactive ovary of a moulting chicken. During the moult in chickens and in wild birds in the non-breeding state, ovulation ceases and the follicles are absorbed (atresia), so that the ovary comes to resemble the shrunken juvenile gonad. In the chicken the inactive ovary weighs only about 2-6 g.

167



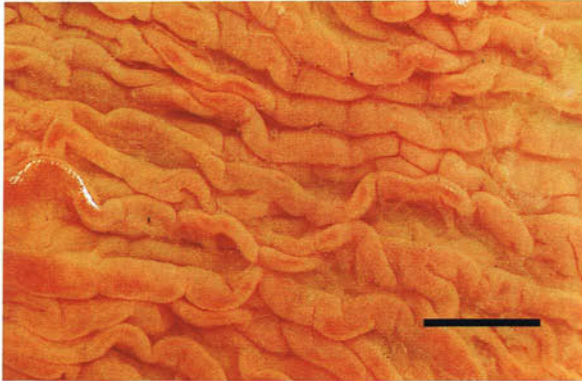
167 Oviduct from an in-lay chicken. In the mature sexually active chicken the oviduct may reach a size of about 65 cm. It has six parts. These are the infundibulum (a), the magnum (b), the isthmus (c), the tubular part of the uterus (d), the pouch of the uterus (e), and the vagina (f). In this photograph an egg is present in the cranial part of the magnum. The infundibulum is the site of fertilization and the second maturation division which forms the ovum.

The glands in the wall of the oviduct are responsible for the formation of the white and shell of the egg. The egg stays in the infundibulum for 15 minutes, in the magnum for 3 hours, in the isthmus for 75 minutes, in the uterus for 20 hours, and in the vagina for a few seconds. When the chicken goes out of lay, the length of the oviduct is dramatically reduced to about 15 cm.

168 and 169 Inner surface of the oviduct of an adult chicken. The inner surface of the oviduct is greatly increased by mucosal folds in which lie the glands. The appearance of the folds is characteristic for each part of the oviduct. In the magnum (168) there are about 22 very well-developed primary

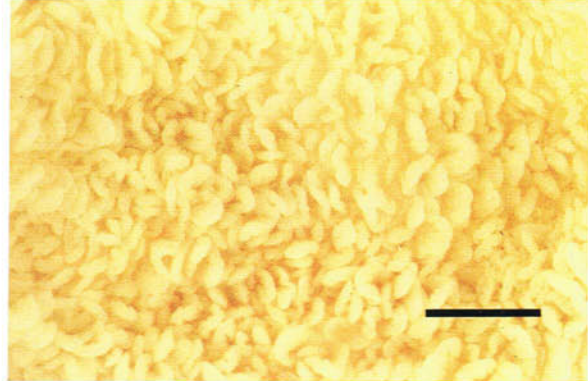
folds with no secondary folds. In the uterus (169), in contrast, the folds are in the form of leaf-like lamellae. Because the folds are continuous and form a spiral, the egg is rotated as it passes down the oviduct.

168



168 Inner surface of the magnum of an adult chicken photographed under water. (Scale, 10 mm)

169

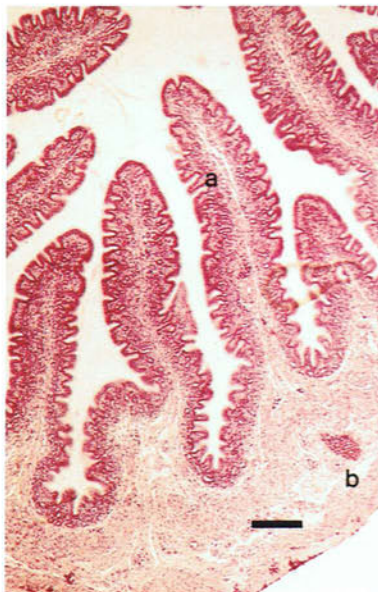

169 Inner surface of the pouch of the uterus of an adult chicken photographed under water. (Scale, 10 mm)

170 and 171 Histological structure of the magnum. Throughout the oviduct there are two types of glands: unicellular glands in the epithelium, and multicellular glands in the mucosal folds. The unicellular glands are especially well-developed in the

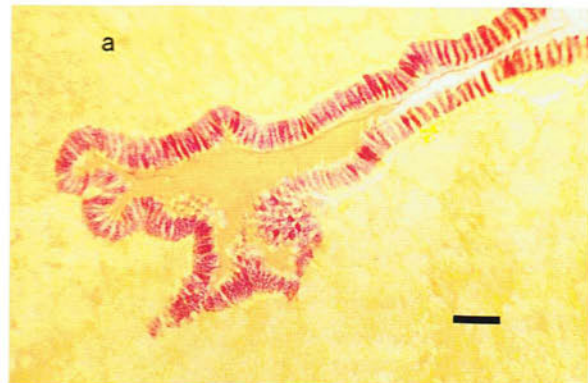
magnum and in 171 they are stained red and resemble goblet cells. Alternating with the unicellular glands are ciliated cells. The multicellular glands (a) are also massively developed in this part of the oviduct. Because in the sexually active bird the cytoplasm of the gland cells is packed with secretion, it is difficult to identify the lumen of the glands. Outside the glandular layer is smooth muscle (b) which is best developed in the vagina and uterus. In the proximal part of the vagina it forms a sphincter.

170



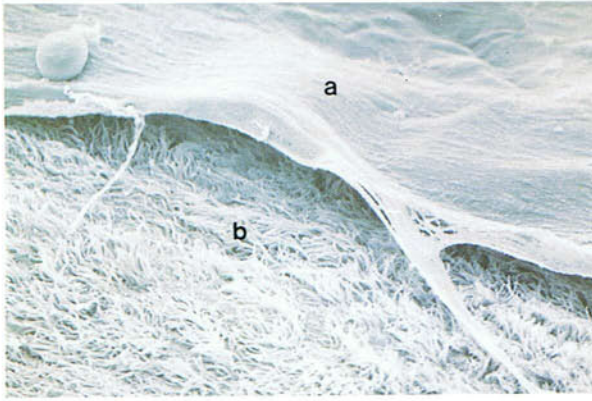
170 Light micrograph of the magnum of a non-laying chicken. Haematoxylin and eosin. (Scale, 100 μ m)

171



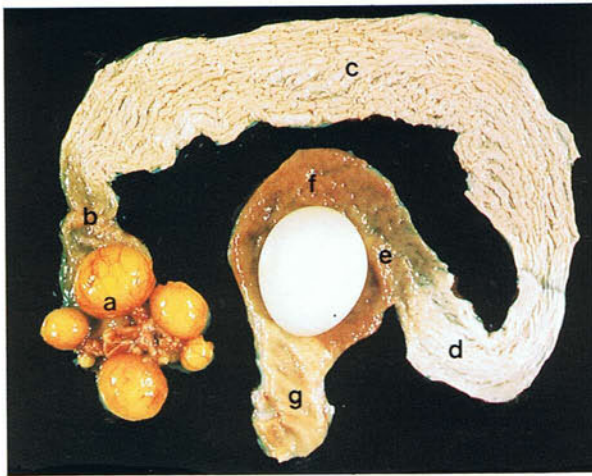
171 Light micrograph of the magnum of an in-lay chicken. Periodic acid-Schiff. (Scale, 20 μ m)

172



172 Scanning electron micrograph of the inner surface of the magnum of an adult chicken. A continuous layer of mucus (a) covers the surface. The numerous ciliated cells (b) of the epithelium tend to obscure the goblet-like cells. $\times 18,000$.

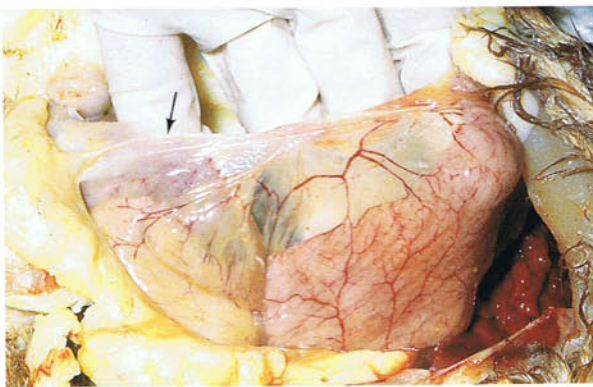
173



173 Ovary and oviduct of an in-lay chicken with an egg in the pouch of the uterus: (a) ovary; (b) infundibulum; (c) magnum; (d) isthmus; (e) tubular part of the uterus; (f) pouch of the uterus; (g) vagina.

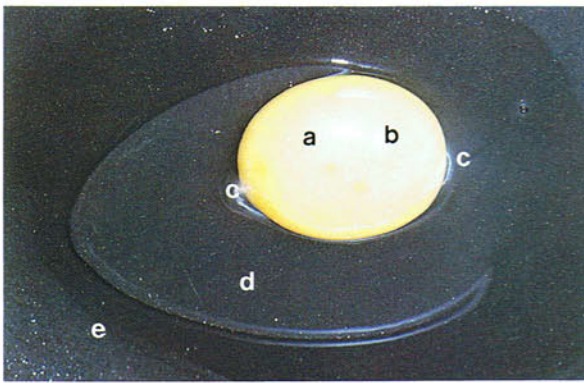
The white and shell of the egg are secreted by the glands in the various regions of the oviduct. The glands in the infundibulum form the thin chalaziferous layer of dense albumen surrounding the yolk and the chalazae (see 175) which suspend the yolk and permit it to rotate so that the germinal disc stays on top. In the magnum albumen, sodium, magnesium and calcium are produced. The glands in the isthmus form the shell membranes and 10 per cent of the albumen protein, while in the uterus the shell and the watery solutions which 'plump' out the egg are produced. The vagina does not contribute to the egg. Calcium for the formation of the shell comes from two sources, the diet and medullary bone. The latter is cancellous bone laid down in the marrow cavity of the long bones about 2 weeks before the onset of laying. During the laying cycle this bone is periodically produced and reabsorbed. The bright red colour of the pouch of the uterus is the result of vascular engorgement.

174



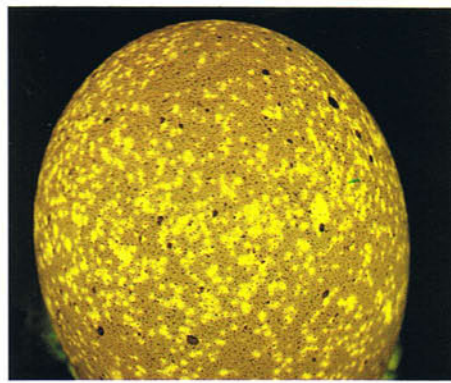
174 Ventral ligament of the oviduct of an adult chicken. Right ventral view. The oviduct is suspended from the roof of the body cavity by the dorsal peritoneal ligament which continues ventrally from the oviduct as the ventral ligament. This ligament ends in a free border which caudally has a well-developed muscular cord (arrow). The oviductal arteries form a series of anastomosing arcades in the dorsal and ventral ligaments.

175




175 Structure of a chicken egg. Shell and shell membranes removed: (a) yolk; (b) germinal disc (forms embryo if egg fertilized); (c) chalaza; (d) middle thick white of albumen; (e) outer thin white of albumen.

176



176 Candling an egg. Candling or transillumination of eggs is first carried out a few days after laying and can be used to determine clear (infertile) eggs, eggs with dead embryos, and eggs with structural variations and faults such as an abnormally large air space or hairline cracks within the shell.

177 Eggs. Some birds, for example chickens and ducks, are indeterminate layers and if their egg is removed they will replace it. Chickens can be induced to lay approximately 230 eggs in a year. Most birds, however, are determinate layers and produce a fixed number of eggs in their clutch. The frequency of laying varies according to the species; some birds, for example finches, lay every day, others, for example parrots, lay on alternate days. Clutch sizes and incubation times of some common birds: Zebra Finch, 6 eggs, 12 days incubation; Canary, 4 eggs, 13-14 days; Budgerigar, 4-6 eggs, 16-18 days; Cockatiel, 5 eggs, 19 days; Ring-necked Parakeet, 6 eggs, 23 days; Pigeon, 2 eggs, 17-19 days. In the indeterminate-laying chicken and duck the incubation periods are 21 days and 28 days respectively. The particular chicken eggs shown in the photograph are 'splashed' on the surface with calcium, which is associated with stress.



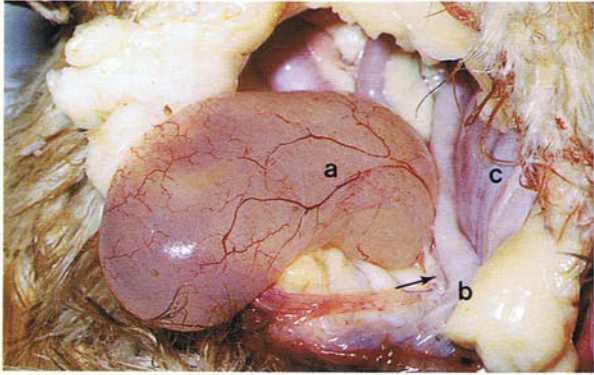
177

178 Pigmentation of eggs. The wide variation in the colour of eggs is produced mainly by the pigments biliverdin and porphyrins. There are often other markings on top of this colour, such as spots and streaks which may form a range of patterns as shown on these quail eggs.



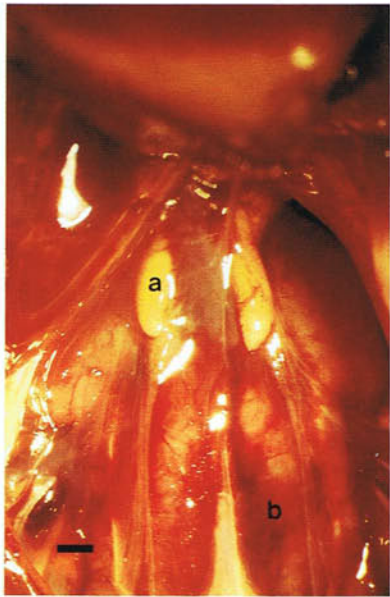
178

179



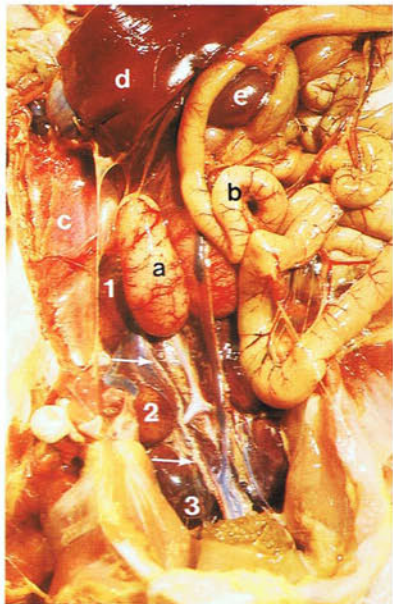
179 Right oviduct of a chicken. Ventral view. While the right oviduct stops developing early in the embryo, remnants of it can frequently be found after hatching. These remnants, like the one in the photograph, may be very large cystic structures (a). The fluid within the cyst is derived from blood plasma. The oviduct remnant is attached to the cloaca (b) by a narrow stalk (arrow). Part of the normal left oviduct (c) can also be seen. In contrast to the right oviduct, remnants of the right gonad are usually not obvious. However, if the left ovary is destroyed, this remnant generally enlarges into a structure which in 90 per cent of cases is testis-like.

180

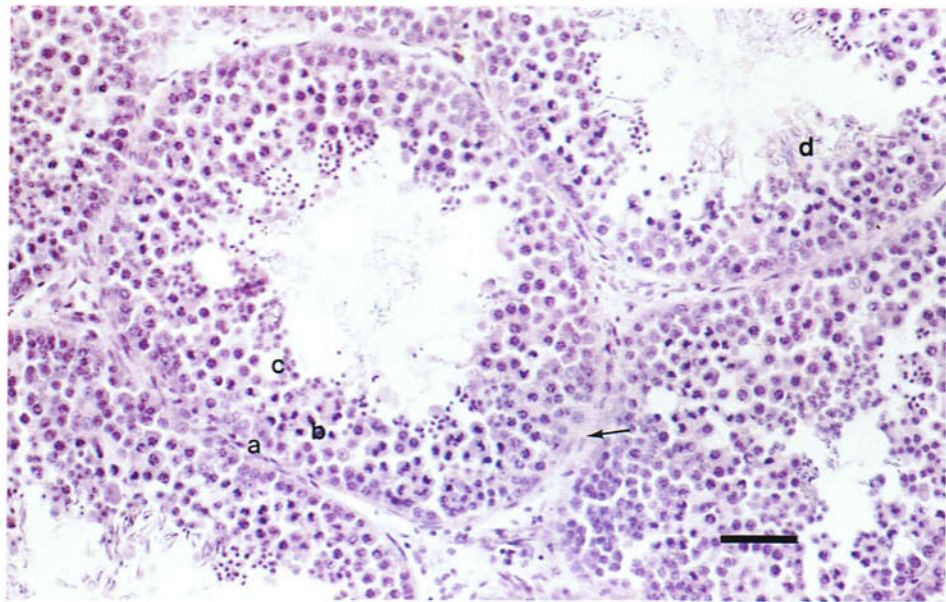


180 Testes of a 5-day-old chicken. Ventral view. The right and left juvenile testes (a) are bean-shaped and overlie the cranial ends of the kidneys (b). In chickens and many wild birds the juvenile testes are yellow due to lipids in the interstitial cells. (Scale, 1 mm)

181



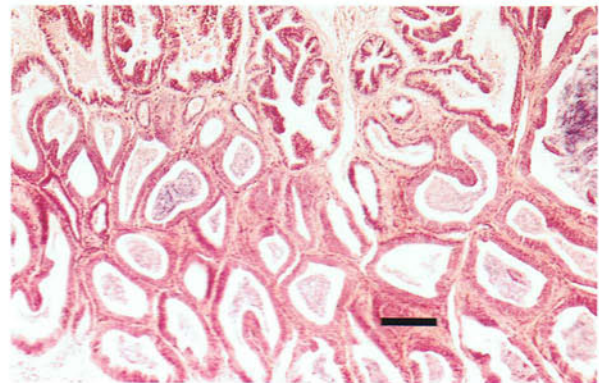
181 Testes of a sexually active chicken. Ventral view. During sexual activity the testes (a) approximately triple in size and become white in colour due to the dispersal of the interstitial cells by the enlarging seminiferous tubules. The increase in size of the testes is most marked in wild birds in which the testes practically disintegrate during the non-breeding phase and have to be almost totally regenerated in time for the next breeding season. The increase in size can be as much as 300 times. As shown in the photograph the surface of the sexually active testis is highly vascular. The epididymis lies dorsal to the testis and is therefore not seen in a ventral view. In wild birds it also enlarges considerably during the breeding season. The ductus deferens (arrows) extends caudally on the ventral surface of the kidney and terminates in the cloaca. In this photograph the cranial (1), middle (2) and caudal (3) divisions of the kidney are visible. There are no accessory genital glands such as a seminal vesicle or prostate. Also visible are small intestine (b), lung (c), liver (d), spleen (e).



182

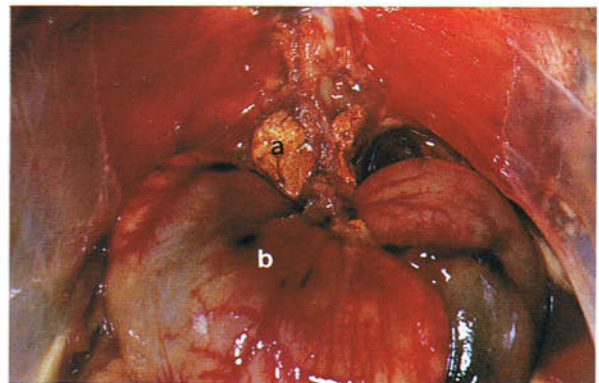
182 Light micrograph of the testis of an adult chicken. The testis consists mainly of convoluted seminiferous tubules lined by a spermatogenic epithelium formed by germ cells and sustentacular cells. The germ cells include spermatogonia (a), primary and secondary spermatocytes (b), spermatids (c) and maturing spermatozoa (d) which develop with their heads attached to the sustentacular cells and their

tails projecting into the lumen. The testis is enclosed by a connective tissue tunica albuginea which gives rise to the thin connective tissue septa (arrow) separating the tubules. There are no lobules or mediastinum, unlike in mammals. Between the tubules lie the interstitial cells which are the source of androgens. (Scale, 40 μm)



183

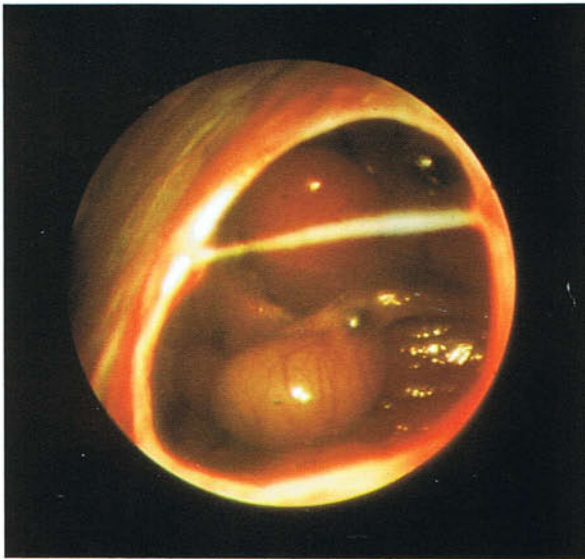
183 Light micrograph of the epididymis of a sexually active chicken. Haematoxylin and eosin. The coiled and anastomosing efferent ductules arise along the whole length of the epididymis so that a head, body and tail cannot be distinguished. They contain many maturing spermatozoa and open into the epididymal duct close to the surface of the epididymis. (Scale, 100 μm)



184

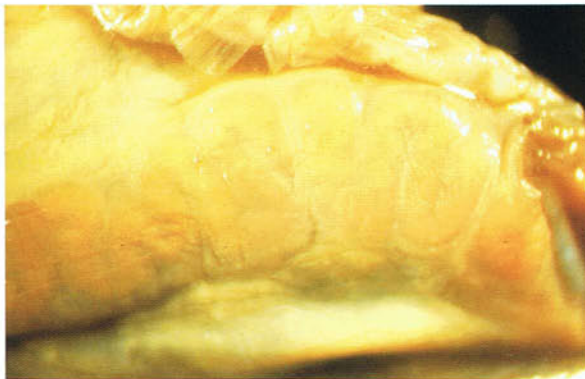184 Adrenal glands of an adult male chicken. Ventral view. The right and left adrenal glands (a) are yellow structures lying on either side of the midline at the cranial end of the kidneys and dorsal to the testes (b). They are firmly attached to the cranial extremity of the epididymis. Unlike in mammals the cortical and medullary cells do not form two distinct regions but intermingle.

185



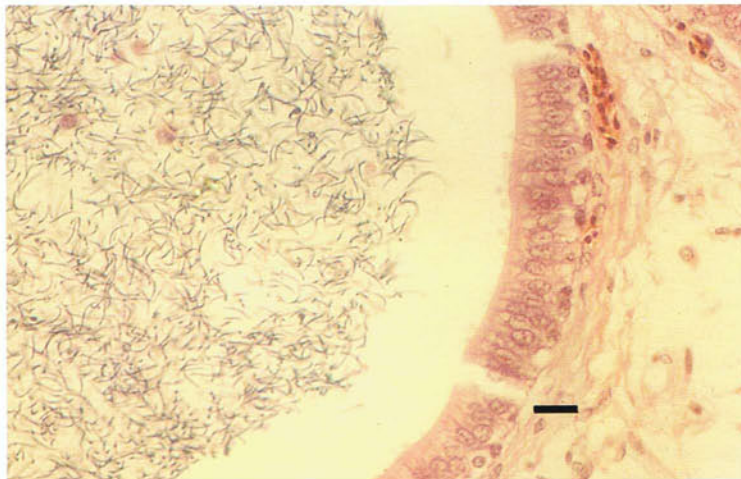
185 Sexing by endoscopy. By inserting an endoscope into the body cavity it is possible to determine the sex of monomorphic species and therefore increase the opportunity for breeding programmes. Because females usually have only a left ovary, the approach is generally from the left side. Common sites of entry include the sternal notch; between the penultimate and last ribs just below the cranial border of the sartorius muscle; and in the upper part of a triangle formed by the proximal part of the femur, the last rib and the cranial edge of the pubis. The technique is most often used in parrots and birds of prey. In this photograph the testes of a parrot (*Amazona* sp.) are seen as viewed through an endoscope.

186



186 Ductus deferens of an adult chicken. The ductus deferens in the chicken is a zig-zag tube. Because it is packed with spermatozoa during the breeding period, it is white in colour. In wild birds the duct is only convoluted during the breeding season and in the non-breeding state it is relatively straight. In passerines the caudal end forms a convoluted mass, the seminal glomus, which enlarges during the breeding season. The two glomera then push out the cloacal wall to form the externally visible cloacal promontory.

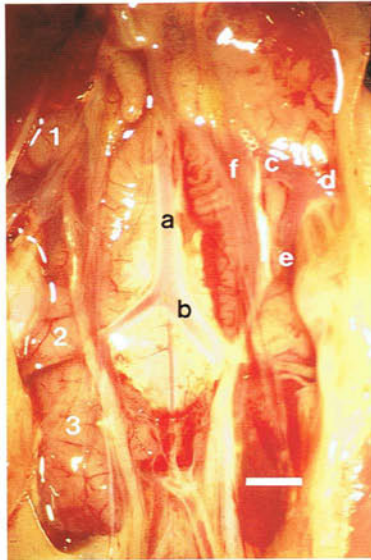
187



187 Light micrograph of the ductus deferens of an adult chicken. Haematoxylin and eosin. The epithelial lining is pseudostratified. The spermatozoa take 1-4 days to reach the ductus deferens and only then do they become fully fertile. The lumen of the

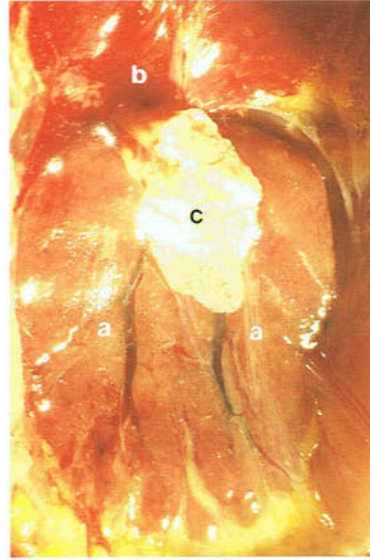
ductus deferens is therefore packed with mature spermatozoa. While most avian species have a simple type of spermatozoon, passerine birds have a complex type with a spiral structure. (Scale, 10 μ m)

188



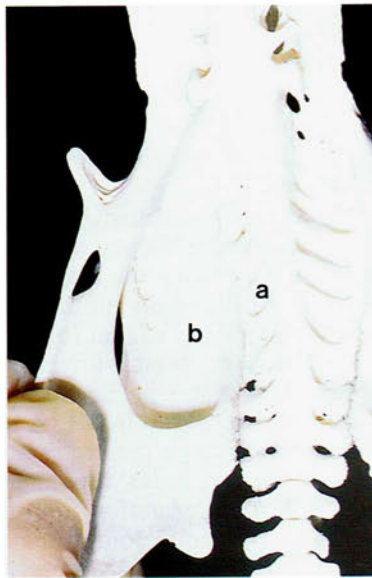
188 Kidneys of a day-old chicken. Ventral view: (a) aorta; (b) ischiadic artery; (c) common iliac vein; (d) external iliac vein; (e) caudal renal portal vein; (f) caudal renal vein. Each kidney is divided into cranial (1), middle (2) and caudal (3) divisions, the boundaries between them being formed by the external iliac and ischiadic arteries. The kidney surface has a faint reticular pattern. (*Scale, 2 mm*)

189

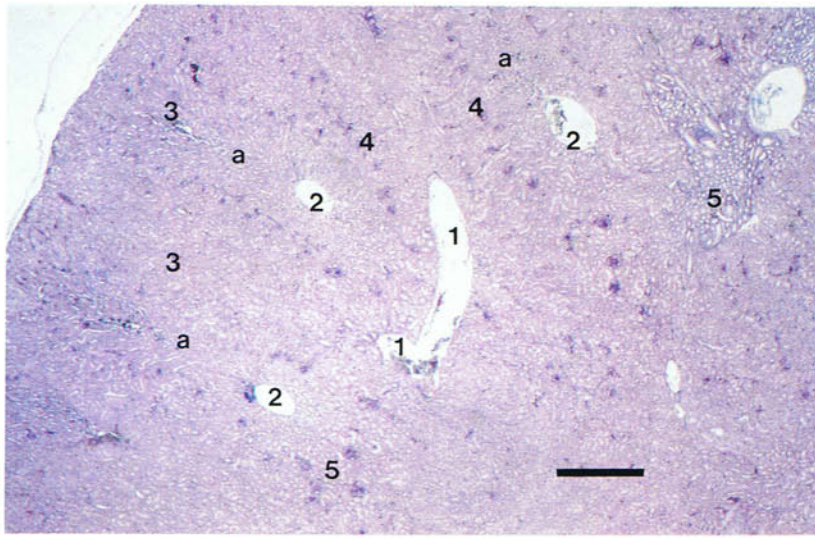


189 Kidneys of a canary. Ventral view. The right and left kidneys (a) fill depressions on the ventral surfaces of the synsacrum and hip bones, and reach from the lungs (b) cranially to the end of the synsacrum caudally. Their colour varies according to the amount of blood they contain from pink to brownish-red. While in non-passerine birds the kidneys can be externally divided into cranial, middle and caudal divisions (see **181** and **188**), these divisions are not obvious in passerines like the canary. Furthermore, in the canary, as in budgerigars and many other birds, there appears to be fusion caudally between the right and left kidneys. Adjacent to the cranial end of the left kidney is a juvenile ovary (c).

190



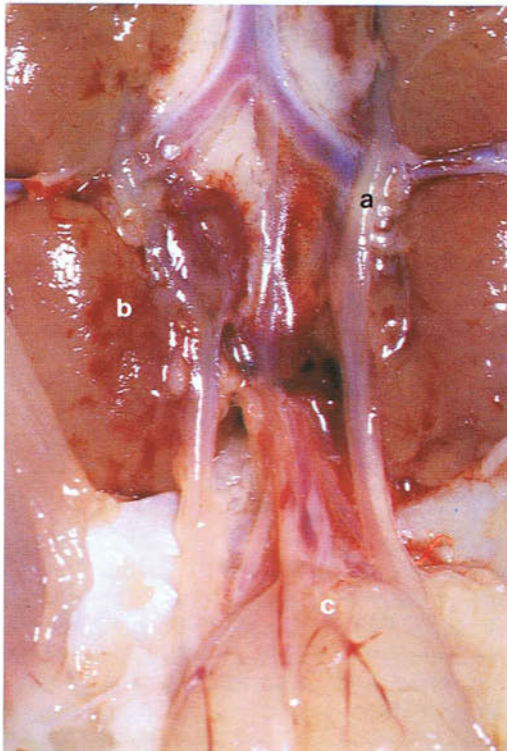
190 Synsacrum and right pelvic bone of an adult chicken. Ventral view. The kidneys are embedded in depressions on the ventral surface of the synsacrum (a) and in the renal fossa (b) of each ilium. Because of the relatively fixed position of the kidney and the fact that large blood vessels and nerves pass through it, there is difficulty in dissecting it intact. In the poultry slaughter plant the kidneys are generally removed by suction.



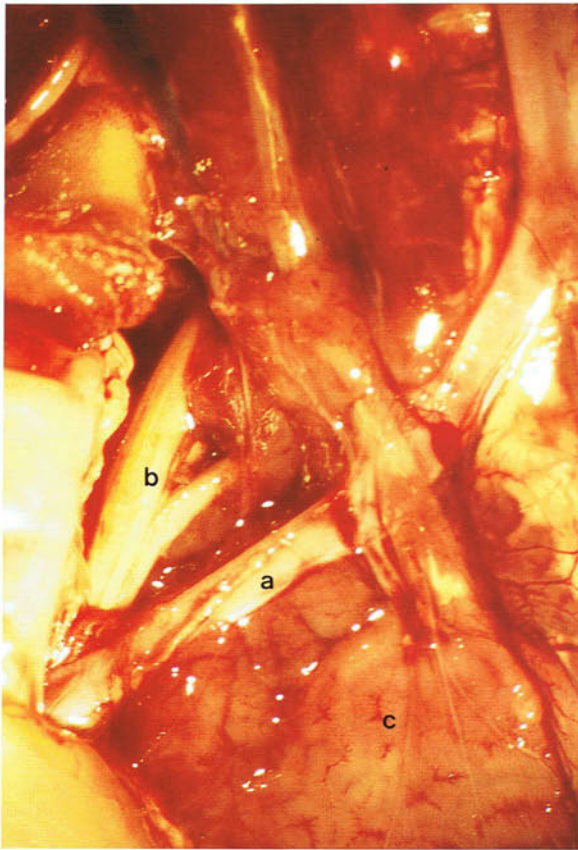
191 Light micrograph of the kidney of a chicken. Haematoxylin and eosin. Ideally in a histological section of the kidney a lobule appears as a pear-shaped structure lying between interlobular veins (1) with an intralobular vein (2) and artery at its centre. In this photograph only bits of lobules (a) are visible. Lying beside the interlobular veins are perilobular collecting tubules. The broad part of the lobule is the cortical region which contains nephrons (3) and the peritubular capillary network. The renal corpuscles (4) lie approximately halfway

between the peripheral interlobular veins and the central intralobular vein. The narrow part of the lobule is the medullary region which contains some nephrons and the collecting tubules (5). A cortical region drains into several medullary regions and a medullary region drains the cortical region of several lobules. Because the lobules (and lobes) lie at different depths of the kidney, there are no continuous layers of cortex and medulla as there are in mammals. (Scale, 600 μm)

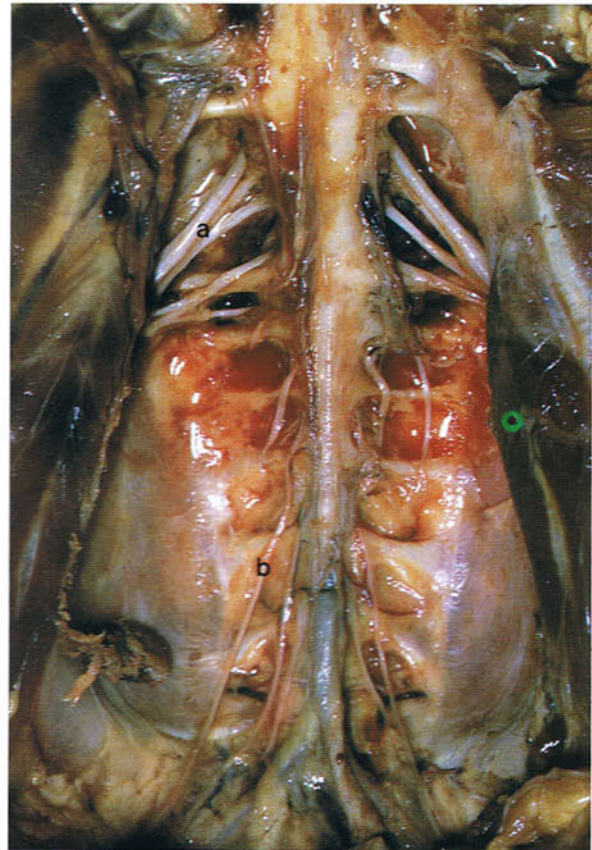192



192 Ureters of a chicken. Ventral view. The collecting ducts of the kidney drain into the ureter (a) which begins within the cranial division of the kidney and runs caudally on the ventromedial border of the middle and caudal (b) divisions. The pelvic part crosses the dorsal surface of the cloacal bursa (c) and terminates in the cloaca. The openings of the ureters are shown in 201. A bladder and urethra are absent. Because the ureter is capable of peristaltic movement it 'milks' the semisolid urine into the cloaca. Normal excretion from the kidney consists of white or cream-coloured semisolid urates which in the cloaca become incorporated into the faeces.

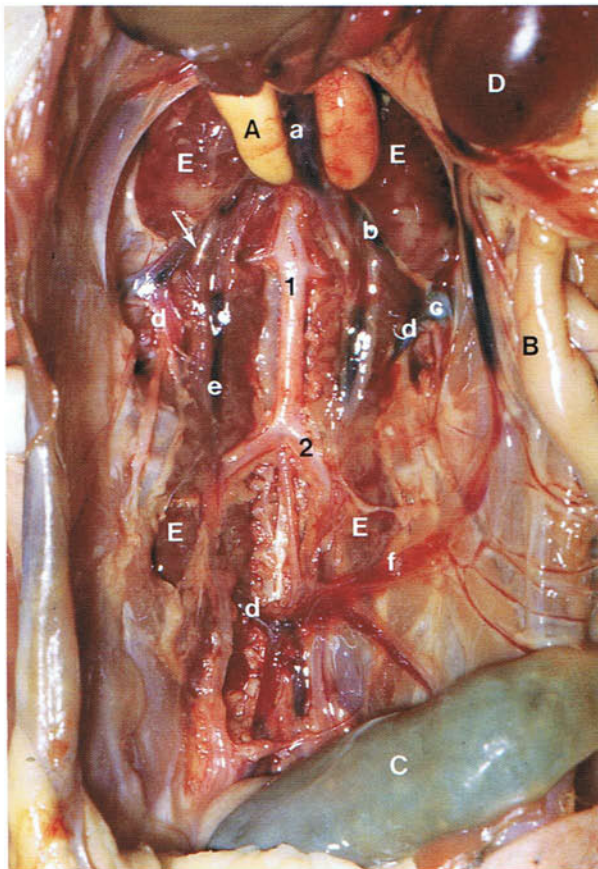


193 Sacral nerve plexus of a chicken. Ventral view. The ventral part of the middle division of the kidney just cranial to the ischiadic artery (a) has been scraped away to reveal the sacral nerve plexus (b) which is totally embedded in the kidney. Among the nerves originating from the plexus is the largest nerve in the body, the ischiadic nerve, which supplies the hindlimb. The sacral nerve plexus can easily be examined post-mortem. Because the ischiadic nerve is closely related to the kidney, nephritis or renal tumours may result in nerve damage and paralysis. See also caudal division of kidney (c).



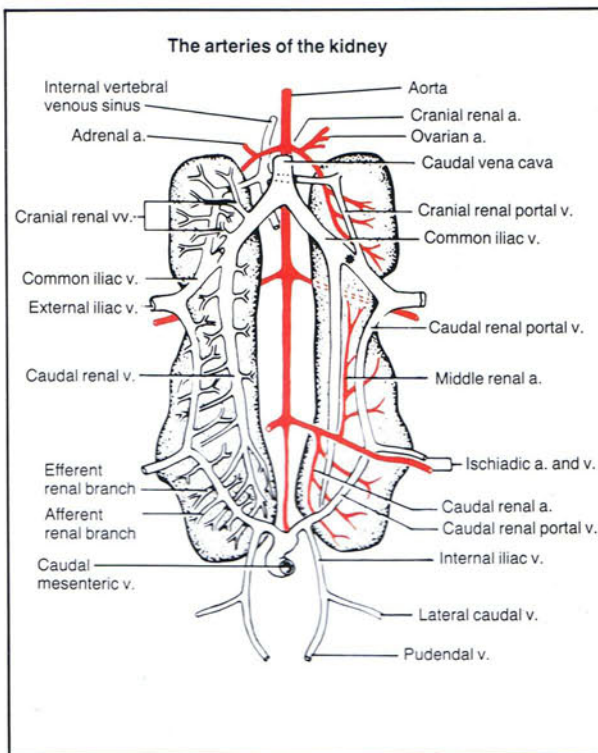
194 Sacral and pudendal nerve plexuses in an adult duck. Ventral view. The kidneys have been removed from the renal fossae of the hip bones, exposing the nerves of the sacral (a) and pudendal (b) plexuses. The nerves arising from the pudendal plexuses innervate the striated muscles of the tail and cloaca, as well as the skin around the vent. One of the nerves, the pudendal nerve, together with the intestinal nerve (see 196), forms the cloacal plexus. Branches of the plexus innervate the terminal parts of the urogenital ducts, and the phallus, vascular body and cloaca.

195a



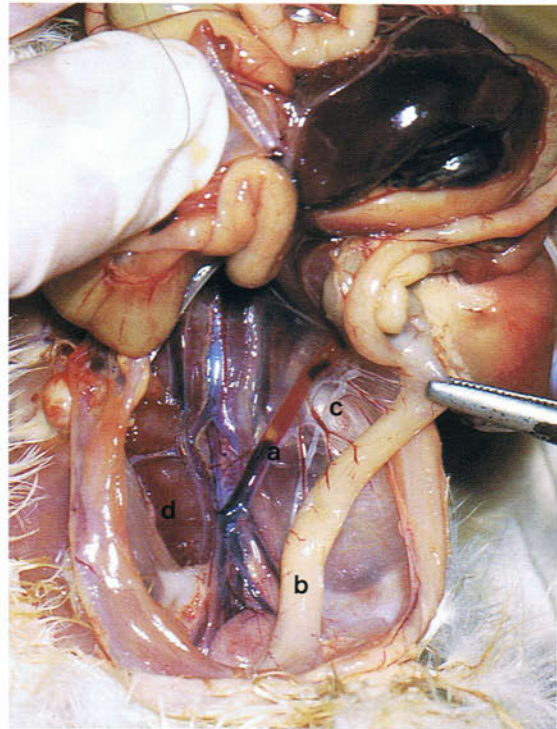
195a Blood supply of the kidneys of an immature male chicken. Ventral view. (A diagrammatic representation of the blood supply is shown in Figure 195b). (A) Testes; (B) caeca; (C) rectum; (D) spleen; (E) kidneys. (a) Caudal vena cava; (b) common iliac vein; (c) external iliac vein; (d) caudal renal portal vein; (e) caudal renal vein; (f) caudal mesenteric vein. (1) Aorta; (2) ischiadic artery. Blood is supplied to the kidneys by the aorta and renal portal veins. Two of the renal arteries arise from the ischiadic artery and their final branches form the central intralobular arteries which give rise to the afferent glomerular arterioles. Blood from the rectum, pelvis and hind limbs is carried to the kidney in the caudal mesenteric vein and ischiadic veins. This venous portal blood enters a venous ring lying on the ventral surface of the kidneys, only very small parts of which, the caudal renal portal veins, can be seen in the photograph. The venous ring has connections with the common iliac vein, and therefore the caudal vena cava, and the venous sinus in the neural canal. Branches of the veins enter the kidney and form the peripheral interlobular veins (see 191) which discharge into the capillary network surrounding the nephrons. While the flow in the caudal mesenteric vein is usually towards the kidneys, it may sometimes be in a cranial direction towards the hepatic portal circulation. Blood in the portal venous ring can be diverted away from the kidneys and flow cranially into the caudal vena cava via the common iliac vein or cranially into the hepatic portal circulation via the caudal mesenteric vein. Within the lumen of the common iliac vein at approximately the point indicated by the arrow, is the renal portal valve which when open allows portal blood to enter the caudal vena cava. The renal portal system enhances renal tubular secretion and reabsorption and is especially important in the secretion of urates. The renal lobules are drained by the central intralobular veins (see 191), the branches of which eventually discharge into the caudal and cranial renal veins. The caudal renal vein opens into the common iliac vein on the central side of the renal portal valve.

195b



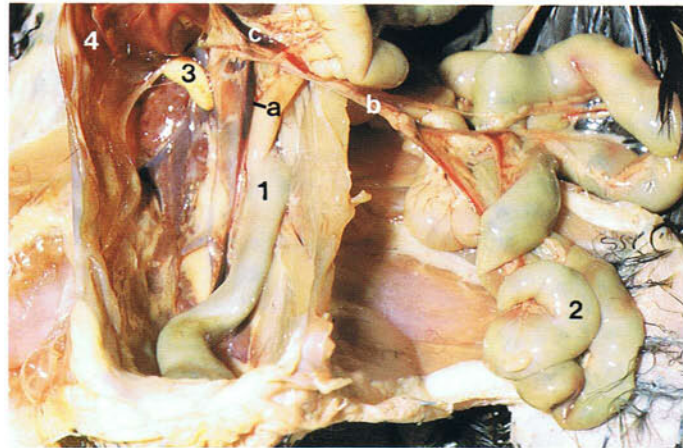
195b Drawing of a ventral view of the kidneys of the domestic fowl to show the blood supply. The kidneys are depicted as though transparent to demonstrate the intrarenal vessels. The arteries are shown on the right side of the diagram, and the renal portal veins and the efferent veins on the left side. The asterisk on the right side indicates the position of the renal portal valve which is shown diagrammatically in the right kidney. From King, A.S. and McLelland, J. (1984). *Birds. Their Structure and Function*. Baillière Tindall, London.

196 Intestinal nerve of a chicken. Ventral view. In the mesorectum between the caudal mesenteric vein (a) and the rectum (b) lies the intestinal nerve (c). The intestinal (Remak's) nerve is a large ganglionated nerve which originates from the sympathetic nerve plexuses on the caudal mesenteric artery, aorta and cranial mesenteric artery and extends cranially as far as the duodenum. It innervates the intestines. Both parasympathetic and sympathetic fibres enter its cranial and caudal ends. The intestinal nerve is usually examined post-mortem. See also kidney (d).



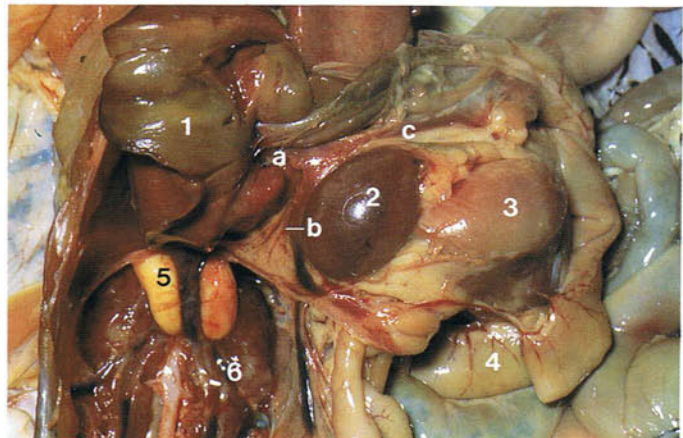
196

197 Mesenteric veins of a 10-week-old chicken. Ventral view. The caudal mesenteric vein (a) joins the cranial mesenteric vein (b) to form the common mesenteric vein (c). (1) Rectum; (2) small intestine; (3) right testis; (4) liver.



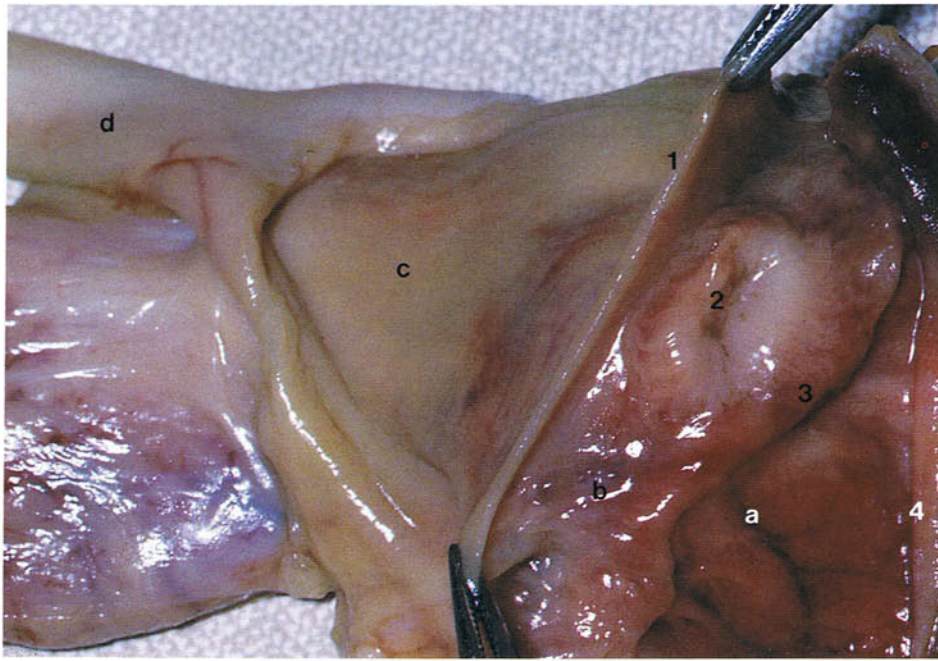
197

198 Right hepatic portal vein of a 10-week-old chicken. Ventral view. Of the two hepatic portal veins, the right vein is the larger and drains the stomach, spleen and the small and large intestines. The right hepatic portal vein (a) is formed by the anastomosis of the common mesenteric vein (b) and the gastropancreaticoduodenal vein (c). The smaller left hepatic portal vein drains the region of the stomach. (1) Liver; (2) spleen; (3) stomach; (4) intestines; (5) testes; (6) kidney.



198

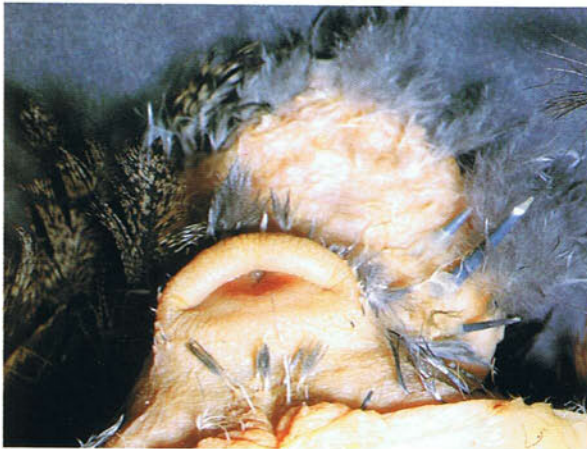199



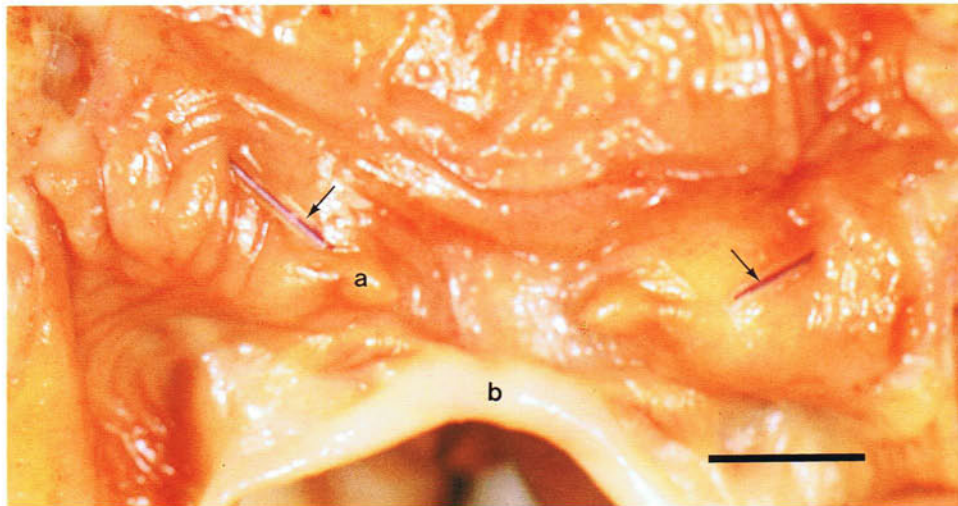
199 Cloaca of an adult female chicken opened along the ventral midline and laid flat. The cloaca consists of three compartments: proctodeum (a), urodeum (b) and coprodeum (c). The coprodeum is directly continuous with the rectum (d). It is separated from the urodeum by the coprourodeal fold (1). The urodeum contains the openings of the ureters and genital ducts and in this photograph the opening of the left oviduct (2) on a slight mound can be seen. In young chickens, ducks and geese the opening is closed by a membrane. This membrane is lost

in chickens at the beginning of the first breeding season and in ducks at sexual maturity (1-1½ years). A vestigial right oviduct is frequently seen in the chicken attached to the urodeum (see 179). The urodeum is separated from the proctodeum by the uroproctodeal fold (3). The proctodeum opens to the outside through the lips of the vent (4). If the coprodeum is full of faeces, the coprourodeal fold protrudes through the vent so that the faeces do not come into contact with the urodeum and proctodeum during defaecation.

200



200 Vent of a 10-week-old chicken. The vent is bordered by dorsal and ventral lips which are inverted into the proctodeum. During the passage of faeces or an egg the lips are everted. In the duck the vent is U-shaped. The appearance of the vent may be used to sex canaries during the breeding season, it being more prominent in the male. In the process of 'venting' in the poultry slaughter plant the skin around the vent is cut and the rectum and cloaca are pulled caudally and suspended from the abdominal cavity.



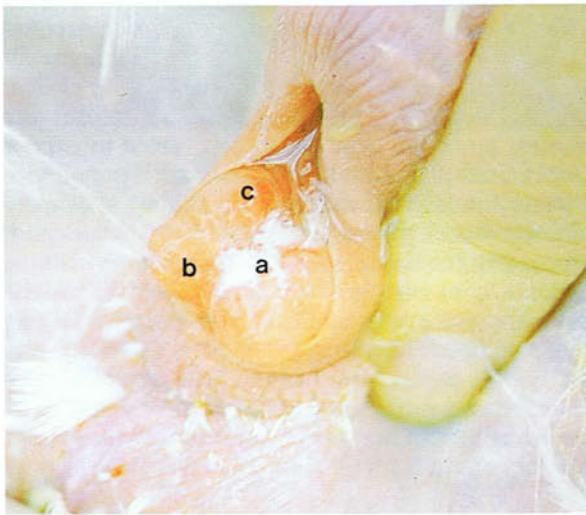201 Urogenital ducts and phallus of an adult chicken. Caudal view. The urogenital ducts open into the urodeal compartment of the cloaca. The ureters are relatively dorsal and in the specimen in the photograph their position is indicated by probes (arrows). Urine deposited in the urodeum is moved by retroperistalsis into the rectum and caeca where reabsorption and conservation of water takes place. Urine and faeces are excreted from the cloaca together, the dark faeces being surrounded by a white ring of uric acid. The ductus deferens opens at the end of a small projection, the papilla of the ductus deferens (a), which is more ventrally situated. The phallus (b) lies on the crest of the ventral lip of the vent and consists of a median phallic body flanked on either side by a lateral phallic body and lym-

phatic folds. The phallus is composed of interconnecting lymphatic channels and in the detumescent state is directed towards the interior of the cloaca. To sex day-old chicks manually, therefore, the ventral lip of the vent has to be everted to expose the region of the phallus. This is not necessary in certain breeds, however, which exhibit sex-linked characteristics such as feather markings. Tumescence of the phallus is due to lymph which flows into the phallus from vascular structures in the ventrolateral walls of the urodeum called the paracloacal vascular bodies. This everts the ventral lip of the vent so that the phallus is extruded. This type of phallus is called non-intromittent because it does not enter the cloaca but is merely applied to the protruded oviduct of the female. (Scale, 5 mm)

202 and 203 Artificial insemination. This procedure is commonly carried out on turkeys and pheasants. In turkeys it is the obligatory method for the commercial production of poults because the large size of the birds and the broad breast conformation impairs natural mating ability. Figure **202** shows the phallus everted through the vent during the collection of semen by manually-induced ejaculation. The semen is deposited in the median ejaculatory sulcus (a) which lies between the tumescent paired lateral phallic bodies (b) and lymphatic folds (c). Immediately before insemination the oviduct

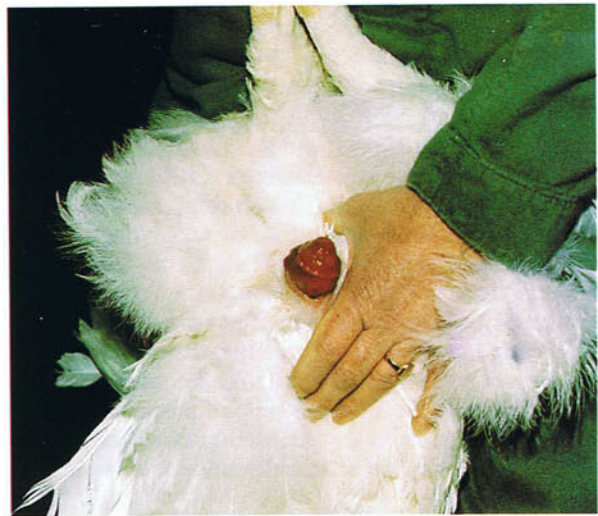of the female is everted by pressure applied to the abdomen as shown in **203** and the inseminating cannula inserted into the vagina. The spermatozoa are stored in spaces in the wall of the vagina, the spermatid fossulae, and can survive there for 4-6 weeks in turkeys and at least 5-11 days in chickens and ducks. Because they are released from the fossulae at subsequent ovulations only single inseminations are required. In the chicken the volume of the ejaculate is 0.8-1.0 ml and the total number of sperm lies between $1-2 \times 10^9$ million.

202



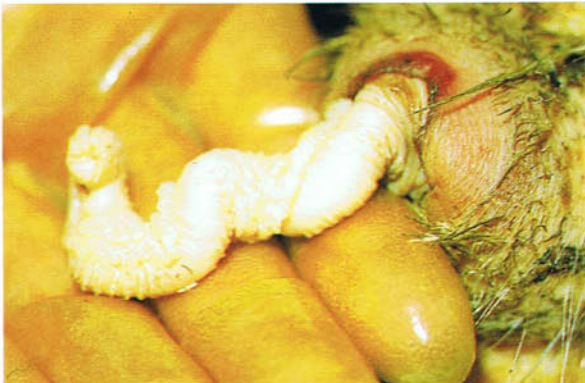202 Artificial insemination. Collection of semen in an adult turkey.

203



203 Artificial insemination. Everted oviduct of an adult turkey.

204

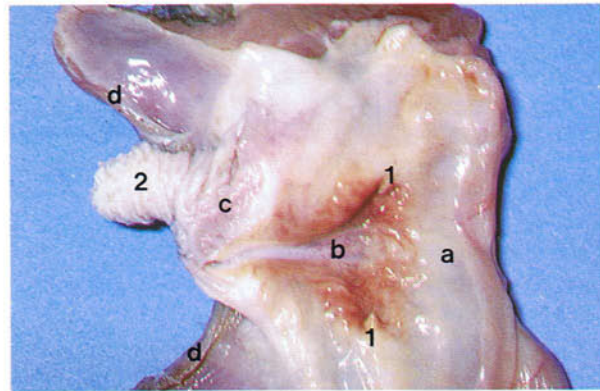


204 Protruded phallus of an adult duck. Ducks and other anseriforms have an intromittent type of phallus which when tumescent is about 6-8 cm in length.

205-207 Phallus of an adult duck: (a) coprodeum; (b) urodeum; (c) proctodeum; (d) vent. (1) Papilla of ductus deferens; (2) phallus. At rest the phallus is invaginated into a sac in the ventrolateral wall of the proctodeum as in **206**. Tumescence is brought about by engorgement with lymph which results in the phallus being partly everted and protruded through the vent opening in a cranial direction. The phallus has a spiral appearance because it is made up of right and left fibrolymphatic bodies which are twisted around each other. Separating

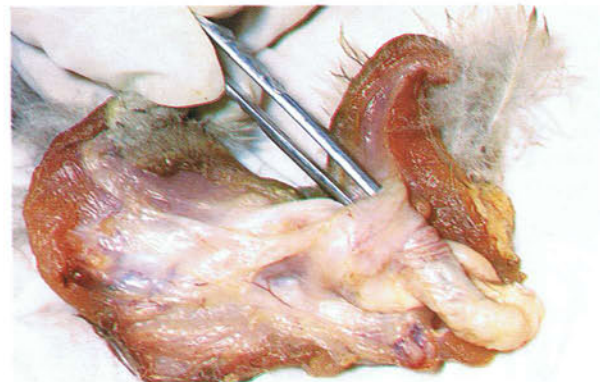
the fibrolymphatic bodies is a spiral groove, the phallic sulcus. In **206** forceps have been inserted into the invaginated phallus. In **207** the forceps have been withdrawn everting the phallus. Detumescence involves removal of the lymph, the invagination of the phallus back into the cloacal wall being helped by an elastic ligament. Because of the great length of the anseriform phallus during coitus, it is inserted into the cloaca. To sex a bird the phallus can be everted by pressure applied on either side of the cloaca.

205 Cloaca of an adult duck cut open along the dorsal midline and laid flat with the phallus protruded.



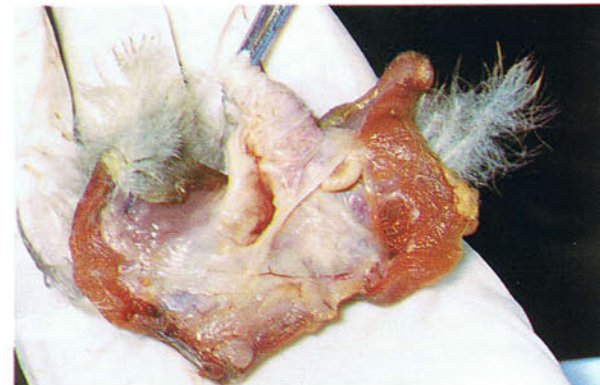
205

206 Cloaca of an adult duck cut open along the dorsal midline and laid flat with the phallus invaginated.



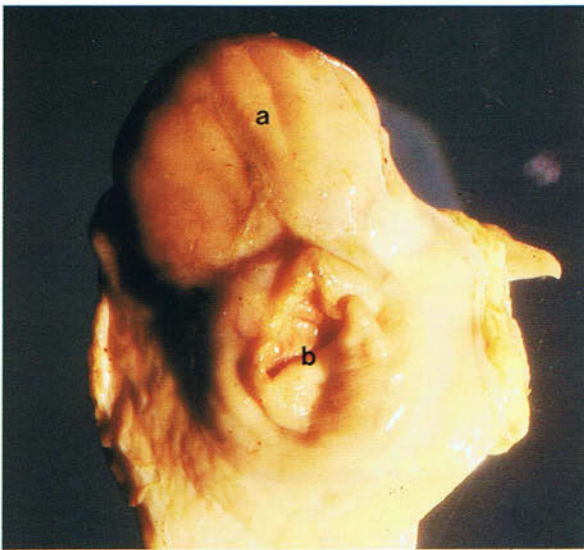206

207 Cloaca of an adult duck cut open along the dorsal midline and laid flat with the phallus protruded.



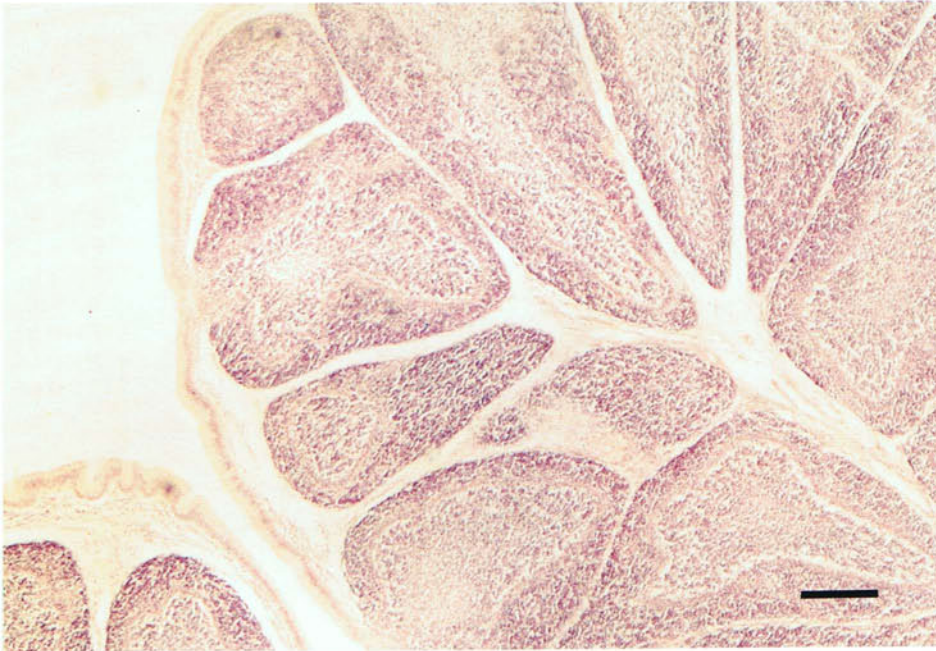
207

208



208 Cloacal bursa of a chicken. Cranial view. The cloacal bursa (bursa of Fabricius) is a dorsal median pear-shaped diverticulum in the wall of which is much lymphoid tissue. In this photograph the bursa (a) can be seen sitting on top of the rectum (b). The bursa in the chicken reaches its maximum size at 3-6 weeks when it measures about $3 \times 2 \times 1$ cm and weighs about 4 g. It then begins to regress at about 8-12 weeks until at 20 months it weighs only 0.5 g. A nodular remnant of the bursa can still be found in the adult. During the process of 'venting' in the poultry slaughter plant it is important that the cloacal bursa is not cut, because cloacal contents could contaminate the carcass.

209



209 Light micrograph of the cloacal bursa of a chicken. The inner surface of the bursa is longitudinally folded, each fold containing follicles of lymphoid tissue separated by connective tissue. Each of the

follicles consists of a dark outer cortex and a pale inner medulla. The lumen of the bursa is lined by columnar epithelium. The bursa is the site of differentiation of B lymphocytes. (Scale, 250 μ m)

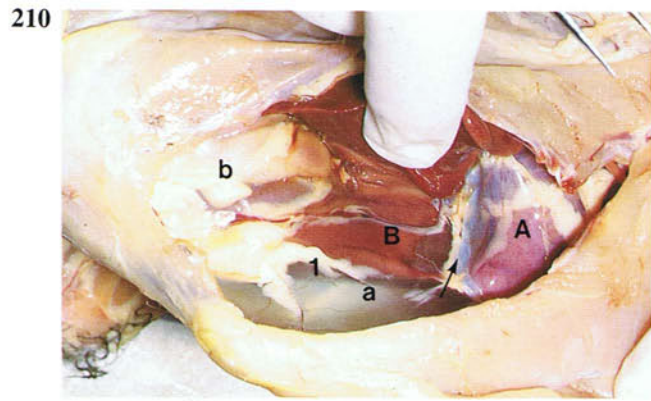
Peritoneum and peritoneal cavities

210-220 Peritoneum and peritoneal cavities of a chicken. (A) Heart; (B) liver; (C) gizzard; (D) intestines. (a) Ventral mesentery; (b) right sheet of posthepatic septum; (c) left sheet of posthepatic septum; (d) left hepatic ligament; (e) oblique septum. (1) Right ventral hepatic peritoneal cavity; (2) left ventral hepatic peritoneal cavity. The main peritoneal cavity of birds is subdivided into five chambers by five peritoneal double-layered sheets of peritoneum. The ventral mesentery (a) is a vertical midline sheet which stretches the length of the peritoneal cavity from the floor to the liver and gizzard (210-212). At the level of the liver and gizzard it is continuous dorsally with the dorsal mesentery of the proventriculus and intestines. Cranially it is continuous (arrow in 210) with the pericardium surrounding the heart. The right (b) and left (c) sheets of the posthepatic septum extend about three-quarters of the length of the peritoneal cavity and stretch ventrally from the roof of the cavity to the ventral mesentery (210-214 and 219). The left sheet (c) encloses the gizzard (214). Cranially, behind the liver, the right and left sheets fuse together and therefore shut off the liver from the rest of the viscera.

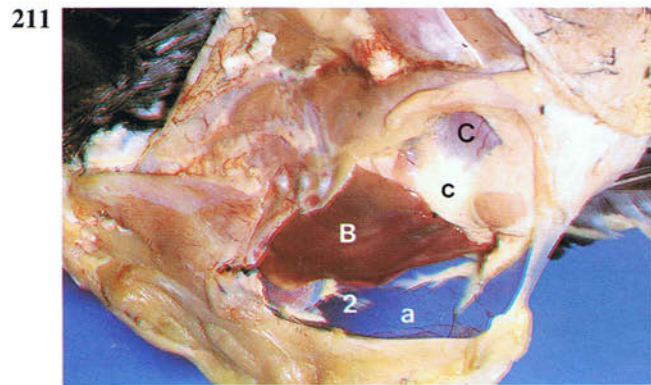
When the bird is opened ventrally in a post-mortem, the posthepatic septum is the glistening membrane through which the gizzard and intestines can be seen as shown in 215. Usually, however, the posthepatic septum contains much fat between its two layers as in 216, 217 and 219 (see also 120). The posthepatic septum has connections with the mesoduodenum (arrow in 218) and the visceral peritoneum enclosing the liver (arrow in 219). The delic-

ate right and left hepatic ligaments (d) arise obliquely from the parietal peritoneum forming the cranio-dorsal boundary of the peritoneal cavity (the oblique septum, see also 292) and extends to the visceral peritoneum covering the liver (220). The right and left sheets of the posthepatic septum divide the peritoneal cavity into a hepatic peritoneal cavity containing the liver and an intestinal peritoneal cavity containing the intestines and the urogenital organs. The hepatic peritoneal cavity is subdivided by the right and left hepatic ligaments (220) into small right and left dorsal hepatic peritoneal cavities dorsal to the liver and large elongated right (1) and left (2) ventral hepatic peritoneal cavities (210-213, 215, 216, 219 and 220), which extend from the liver to the caudal body wall. The left dorsal hepatic cavity is continuous with the intestinal cavity. In 220 the left dorsal hepatic cavity can be seen through the transparent left hepatic ligament (d). In 213 and 215 the intestinal peritoneal cavity can be seen through the transparent posthepatic septum. It can also be seen through the incision in the septum in 217.

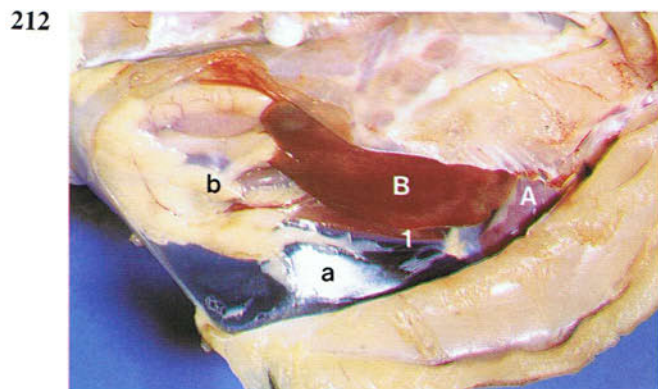
By dividing the peritoneal cavity into two parts, the posthepatic septum is important in restricting the spread of some diseases. The various chambers of the peritoneal cavity should be considered with regard to surgical access to the viscera. To reach the duodenum, pancreas and supraduodenal loop, for example, a ventral abdominal incision is made into the right ventral hepatic cavity, followed by an incision through the right sheet of the posthepatic septum into the intestinal cavity.



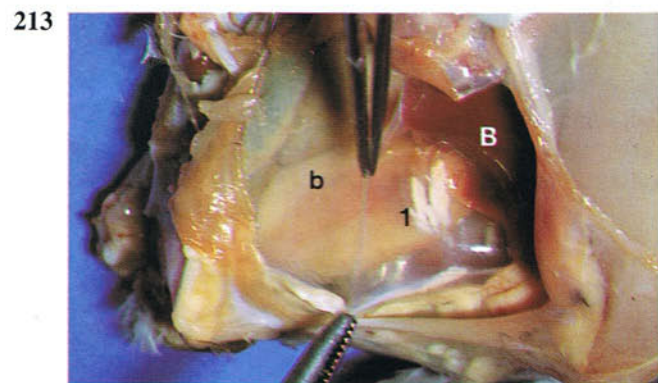
210 Ventral mesentery and right part of the posthepatic septum of a 10-week-old chicken. Right lateral view.



211 Ventral mesentery and left part of the posthepatic septum of a 10-week-old chicken. Left lateral view.

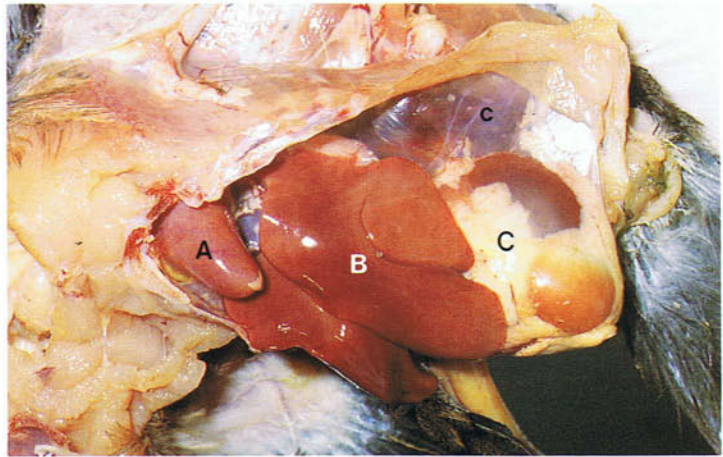


212 Ventral mesentery and right part of the posthepatic septum of a 10-week-old chicken. Right lateral view.

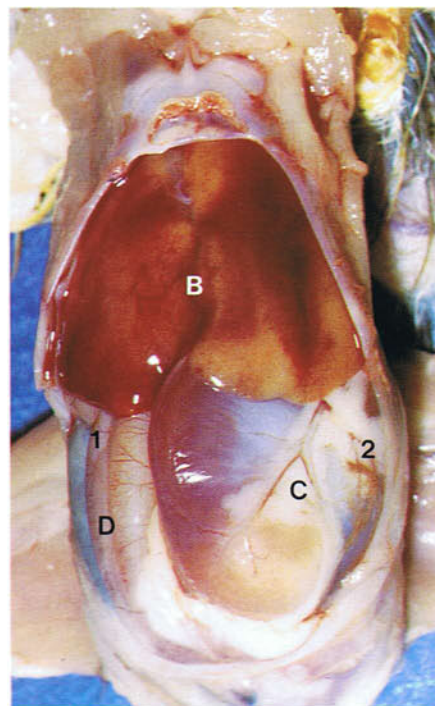


213 Right part of the posthepatic septum of a 6-week-old chicken. Right lateral view.

214 Left part of the posthepatic septum of a 6-week-old chicken. Left lateral view.

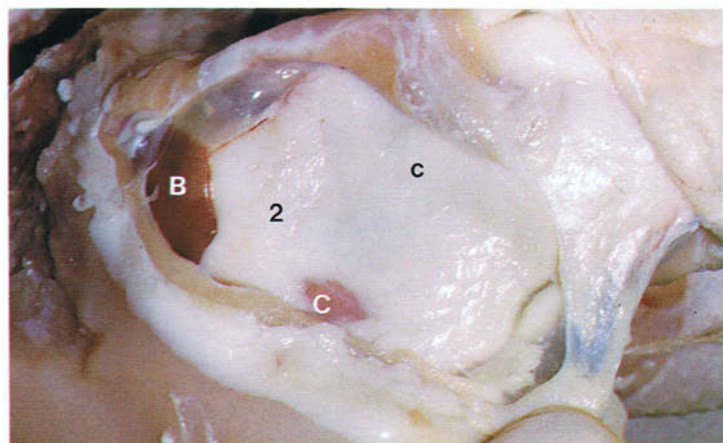


214



215

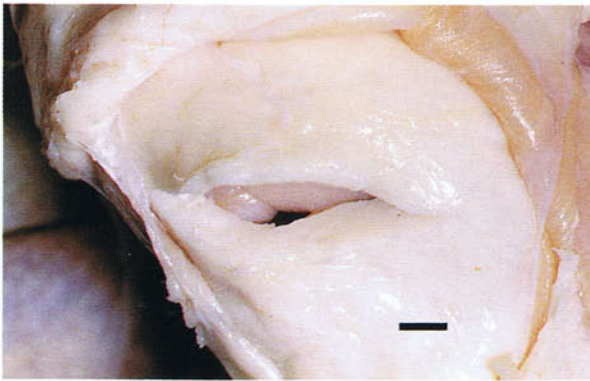
215 Posthepatic septum of a chicken. Ventral view.



216

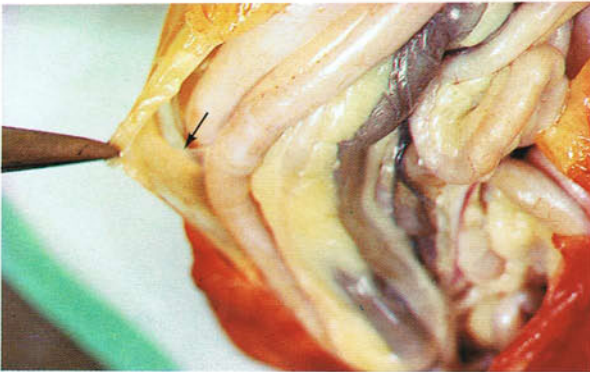216 Left part of the fat-laden posthepatic septum of an 8-week-old chicken. Left lateral view.

217



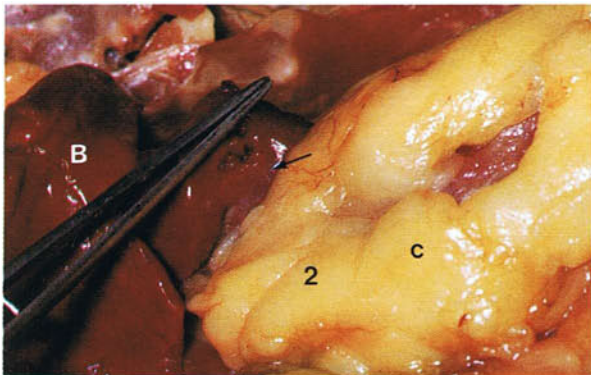
217 Posthepatic septum of an 8-week-old chicken incised to show the thickness of the fat layer. (Scale, 4 mm)

218



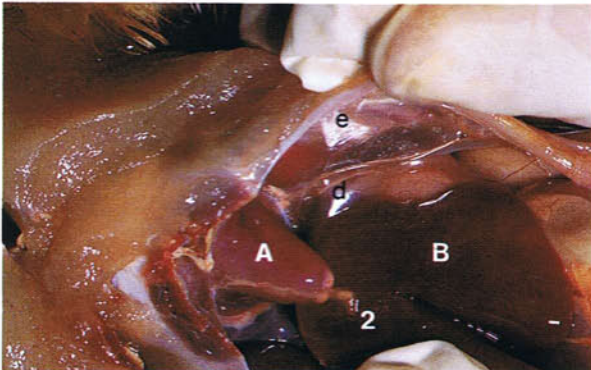
218 Connection between the mesentery of the duodenum and the posthepatic septum in an adult chicken. Ventral view.

219



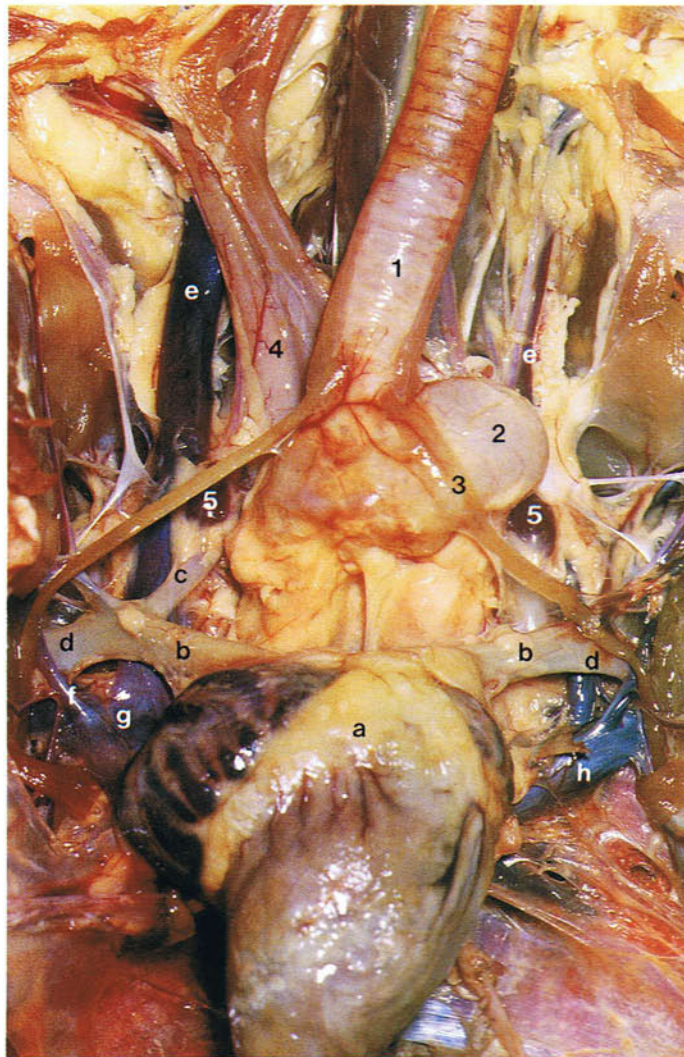
219 Connection between the visceral peritoneum covering the liver and the posthepatic septum in an adult chicken. Left lateral view.

220



220 Left hepatic ligament and oblique septum of a 6-week-old chicken. Left lateral view.

Thorax and neck



221

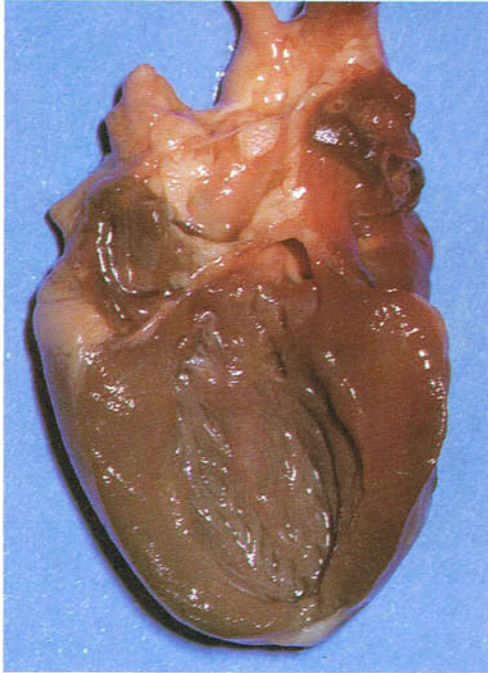
221 Blood vessels at the thoracic inlet of a duck. Ventral view: (a) heart; (b) brachiocephalic trunk; (c) common carotid artery; (d) subclavian artery; (e) jugular vein; (f) subclavian vein; (g) right cranial vena cava; (h) left cranial vena cava. (1) Trachea; (2) syrinx; (3) sternotracheal muscle; (4) oesophagus; (5) thyroid gland. The avian heart on a body weight basis is much larger than that of mammals. Because its rate of contraction is very high, its out-

put is also relatively much greater. It lies in the ventral part of the thorax surrounded by the lobes of the liver (see 120). Opening into the right atrium are three venae cavae—the right cranial vena cava, the left cranial vena cava, and the caudal vena cava. Usually the coronary groove contains much fat and is therefore a good site to examine a bird for serous atrophy of fat, a sign of inanition.

222-225 Heart. Compared to the left ventricle (222), the right ventricle (224) has a much thinner wall and the endocardial surface is smooth. While the

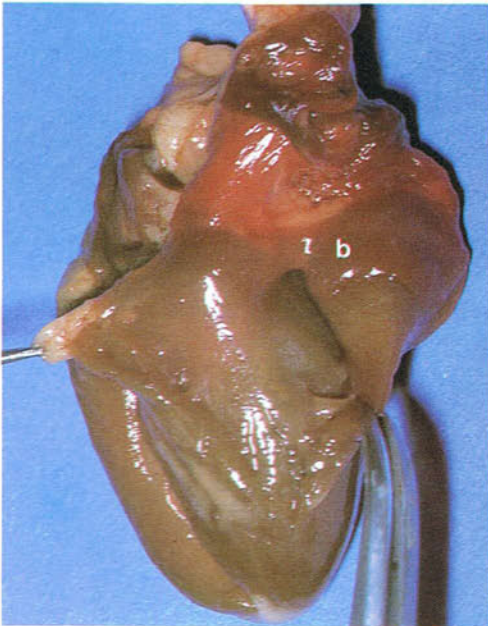
left atrioventricular valve (a) is formed by cusps and chordae tendineae, the right atrioventricular valve (b) is a muscular flap (see also 266).

222



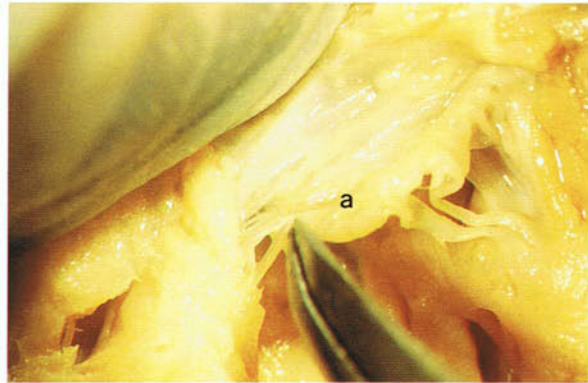
222 Left ventricle of a 5-week-old chicken.

224



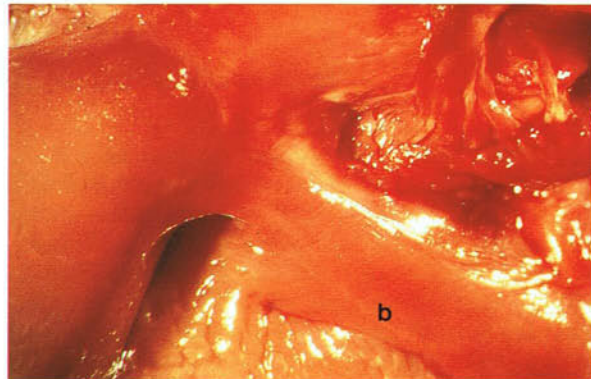
224 Right ventricle of a 5-week-old chicken.

223



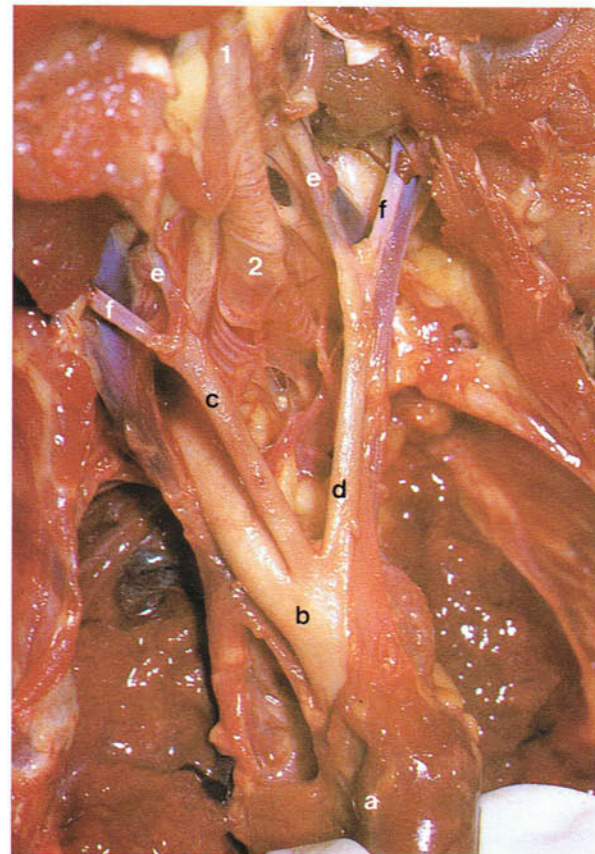
223 Left atrioventricular valve of a 5-week-old chicken. Fixed preparation.

225



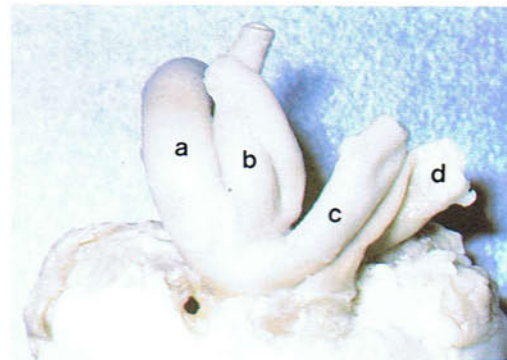
225 Right atrioventricular valve of a 5-week-old chicken.

226 Arteries at the thoracic inlet of a chicken. Ventral view. (a) Heart; (b) aorta; (c) right brachiocephalic trunk; (d) left brachiocephalic trunk; (e) common carotid artery; (f) subclavian artery. (1) Trachea; (2) syrinx. Unlike in mammals, the aorta in birds develops from the right fourth arterial arch and consequently bends to the right. The subclavian artery supplies the wing. The short common carotid artery divides at the base of the neck to form the vertebral trunk and the internal carotid artery (see 228).



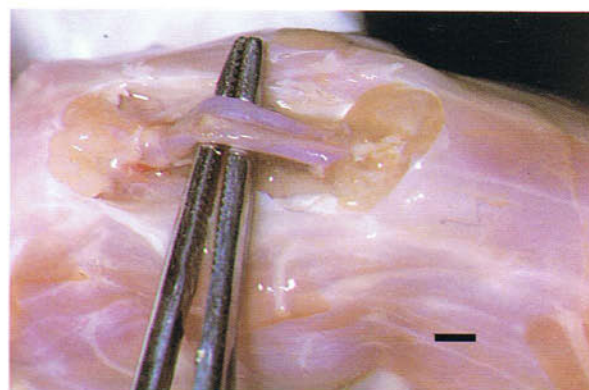
226

227 Aorta and pulmonary trunk of a 5-week-old chicken. Cranial view. Fixed preparation: (a) aorta; (b) right brachiocephalic trunk; (c) left brachiocephalic trunk; (d) pulmonary trunk.



227

228 Internal carotid arteries of a chicken. Ventral view. The paired internal carotid arteries travel up the neck buried in muscle in a groove on the ventral midline of the cervical vertebrae. Close to the head the arteries emerge onto the surface of the muscle and enter the skull. They provide the major blood supply to the brain. In slaughter by neck cutting, ideally both internal carotid arteries should be severed. (Scale, 2 mm)

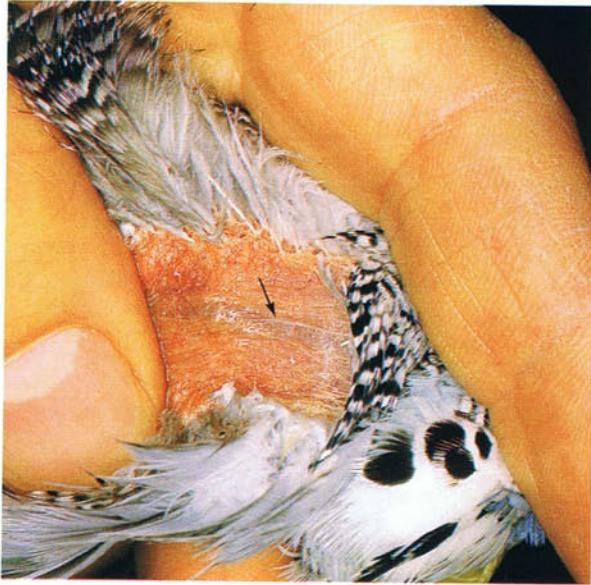

228

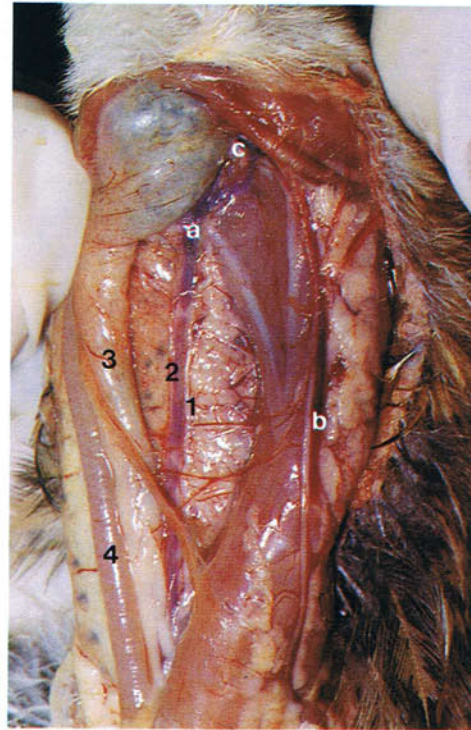
229 and 230 Jugular veins. The right jugular vein (a) is much larger than the left vein (b) because it receives blood from the left via an oblique anastomosis (c) in the cranial part of the neck. The right vein can be seen through the skin (arrow) and is used for collecting blood. The left jugular vein may be absent in small cage birds. Because of the large

size of the right jugular vein, incisions in the neck should be made on the left side. In the slaughter of chickens by neck cutting, a jugular vein may be severed. Closely attached to the jugular veins are the vagal (1) and glossopharyngeal (2) cranial nerves. The vagus is usually examined post-mortem. See also oesophagus (3), trachea (4).

229



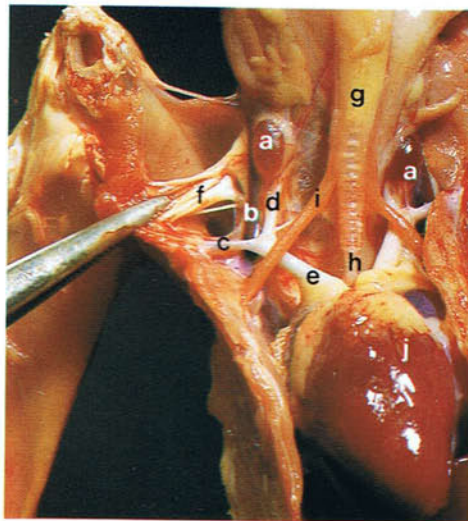
229 Right jugular vein of a budgerigar visible through the skin of the neck.



230

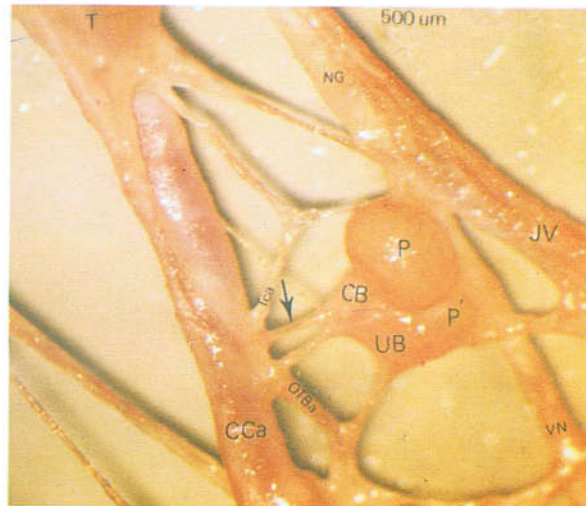
230 Jugular veins in the neck of a 6-week-old chicken. Ventral view.

231



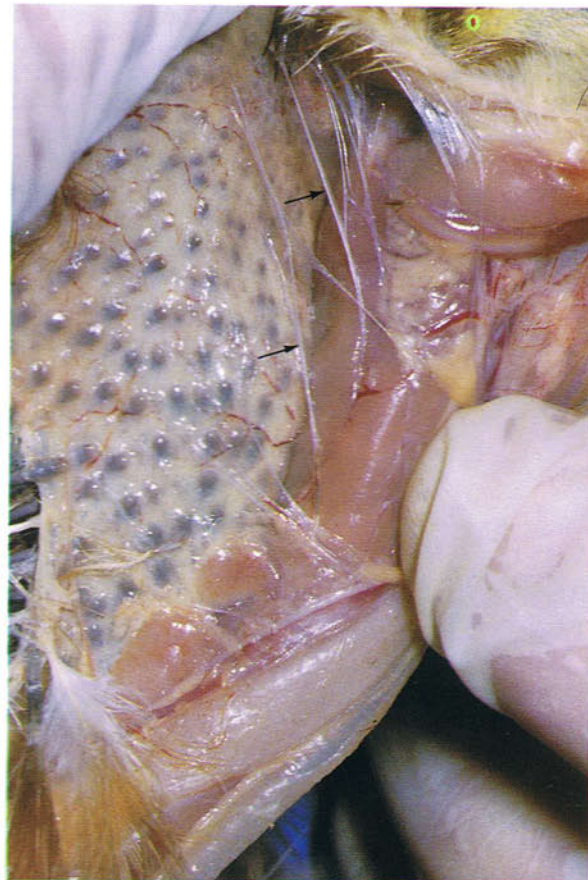
231 Thoracic inlet of a chicken. Ventral view. The paired reddish-brown, oval thyroid gland (a) lies medial to the jugular vein (b) and cranial to the origin of the subclavian (c) and common carotid (d) arteries from the brachiocephalic trunk (e) (see also 221). The thyroid glands in the budgerigar are much paler than in the chicken. Enlargement of the thyroid gland, as frequently occurs in psittacines, may lead to respiratory distress. Lateral to the thyroid gland is the brachial plexus (f) which is usually examined post-mortem. See also trachea (g), syrinx (h), sternotracheal muscle (i), heart (j).

232 Blood vessels, nerves and endocrine glands on the left side of the thoracic inlet of a chicken. (CB) carotid body; (CCA) common carotid artery; (ICA) internal carotid artery; (JV) jugular vein; (NG) nodose (distal vagal) ganglion; (OTBA) oesophago-tracheobronchial artery; (P) parathyroid glands; (T) thyroid gland; (UB) ultimobranchial gland; (VN) vagus nerve. The arrow indicates the artery which supplies the carotid body. Unlike on the left, the right cranial parathyroid gland is in contact with the thyroid gland, and the right ultimobranchial gland is separate from the caudal parathyroid gland. The ultimobranchial glands contain C-cells homologous to the C-cells of the thyroid glands of mammals. From Abdel-Magied, E.M. and King, A.S. (1978). *J. Anat.* **126**, 535-546.

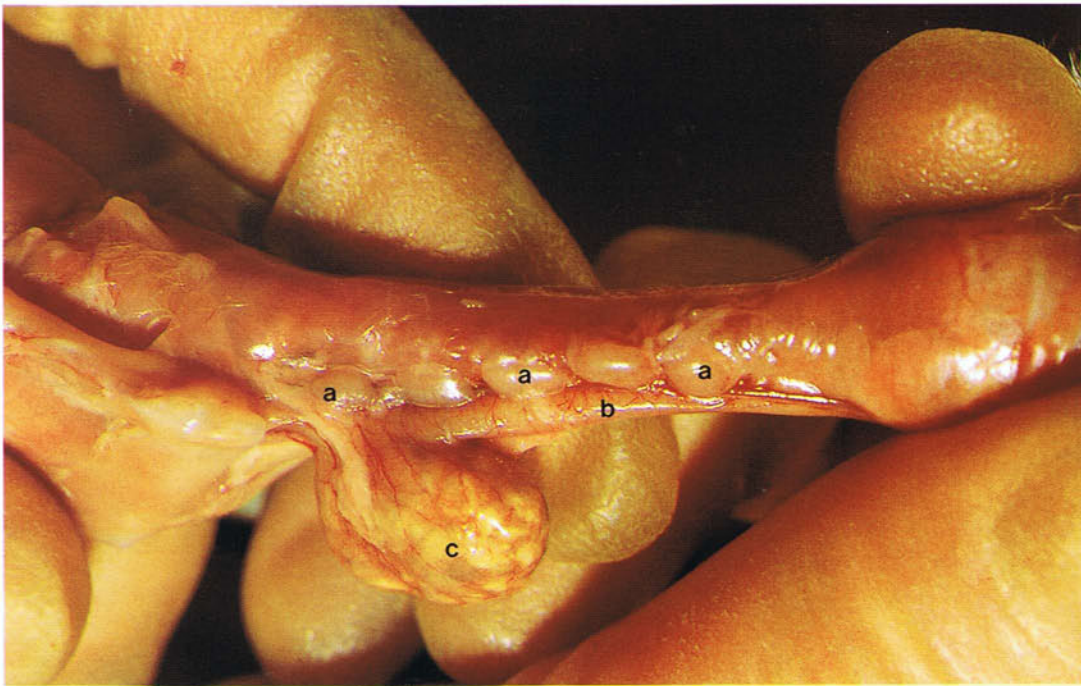

232

233 Cervical spinal nerves of a chicken. Ventral view. In addition to the vagal and glossopharyngeal nerves, other nerves which lie in the neck that may be examined post-mortem include the cervical spinal nerves (arrows) where they extend from the neck muscles to the skin.



233



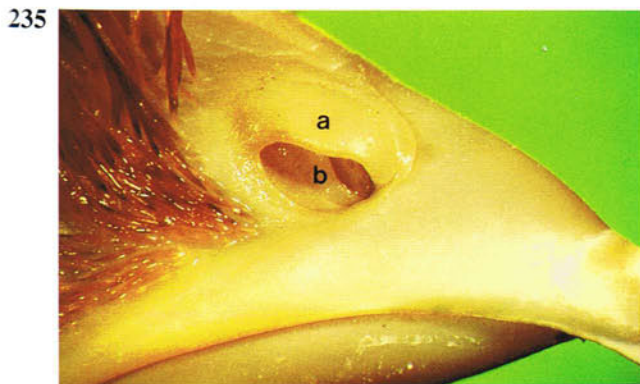
234 Thymus of a chicken: (a) thymus; (b) oesophagus; (c) crop. The thymus in birds lies in the neck and consists in the chicken of between four and seven pale lobes. Each lobe is divided into lobules which have a histological structure similar to that of mammals. The maximum size of the thymus in the chicken is reached between 4 and 17 weeks. At the onset of sexual maturity it regresses. In some wild birds the thymus enlarges annually after the breeding cycle. The thymus, along with the cloacal bursa, contains primary lymphoid tissue. Within it stem

cells differentiate into T lymphocytes. Secondary lymphoid tissue in birds includes the spleen, bone marrow, mural lymphoid nodules and aggregations of lymphoid tissue in the gut and visceral organs. Mural lymphoid nodules are accumulations of lymphoid tissue which occur at short intervals in the walls of the lymph vessels and are not visible with the naked eye. Lymph nodes only occur in some aquatic birds, including the duck and goose, in which there is one pair at the thoracic inlet near the thyroid gland and one pair near the kidneys.

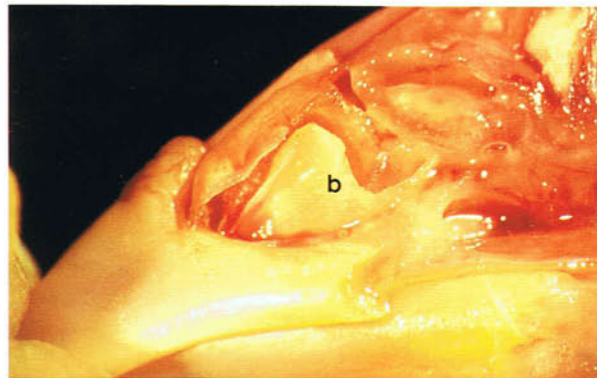
Respiratory system

235 and 236 Nostril of a chicken. In the chicken and turkey the nostril is closed dorsally by a horny flap, the operculum (a). At the ventral border of

the nostril in the chicken is a vertical lamella of cartilage (b) which in **236** has been exposed by removing the operculum.

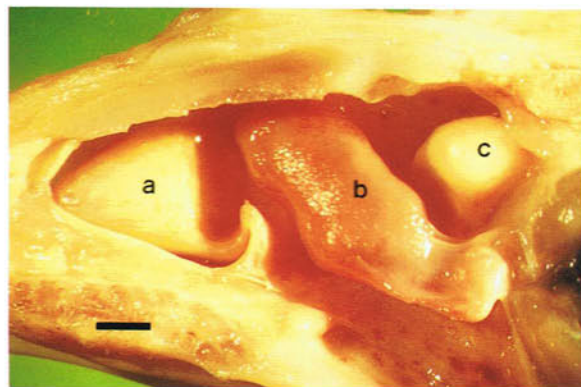


235 Right nostril of a day-old chicken.

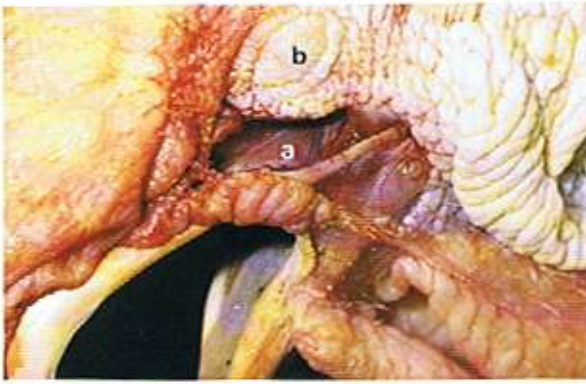

236 Left nostril of a day-old chicken with the operculum removed.

237 Right nasal cavity of a chicken. Medial view. In the photograph the right nasal cavity is viewed as though from the left cavity with the nasal septum removed. There are three cartilaginous nasal conchae. The rostral nasal concha (a) is scroll-like and is lined by stratified squamous epithelium. This concha is absent in quail. The middle nasal concha (b) is also scroll-like and has a mucociliary epithelium. The dome-shaped caudal nasal concha (c) protrudes from the lateral wall of the nasal cavity and is hollow, its cavity being continuous with that of the infraorbital sinus (**238**). The nasal surface of the caudal concha is lined by an olfactory epithelium. The nasal cavity is important in olfaction, filtering airborne particles, and in water and heat economy. (Scale, 2 mm)

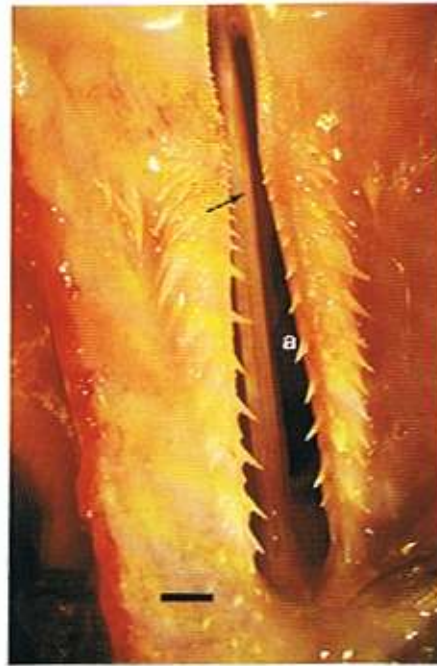

238



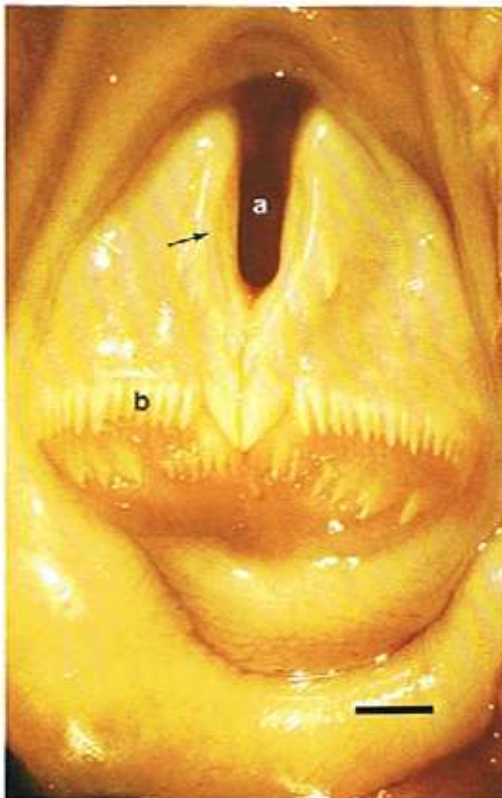
238 Infraorbital sinus of an adult chicken. The infraorbital sinus is a cavity (a) in the lateral wall of the nasal cavity ventral and caudal to the eye (b). It communicates with the lumen of the caudal nasal concha (see 237) and with the nasal cavity. Infection of the sinus in the chicken is common. In psittacines the right and left infraorbital sinuses communicate with each other and have diverticula which pneumatize extensive areas of the skull; in some species, for example the Amazon Parrot, the diverticula extend dorsolaterally on each side of the neck as far caudally as the seventh cervical vertebra. These diverticula make infections of the sinus very difficult to treat.

239



239 Choana of an adult duck. Ventral view. Inspired air passes from the nasal cavities to the oropharynx via the median slit-like opening in the palate, the choana (a) (see also 102). The nasal cavities are separated by a median nasal septum (arrow) which at the level of the choana is incomplete ventrally so that the right and left nasal cavities here are in communication. Clinical examination of the nasal mucosa is possible by endoscopy through the choana. (Scale, 3 mm)

240

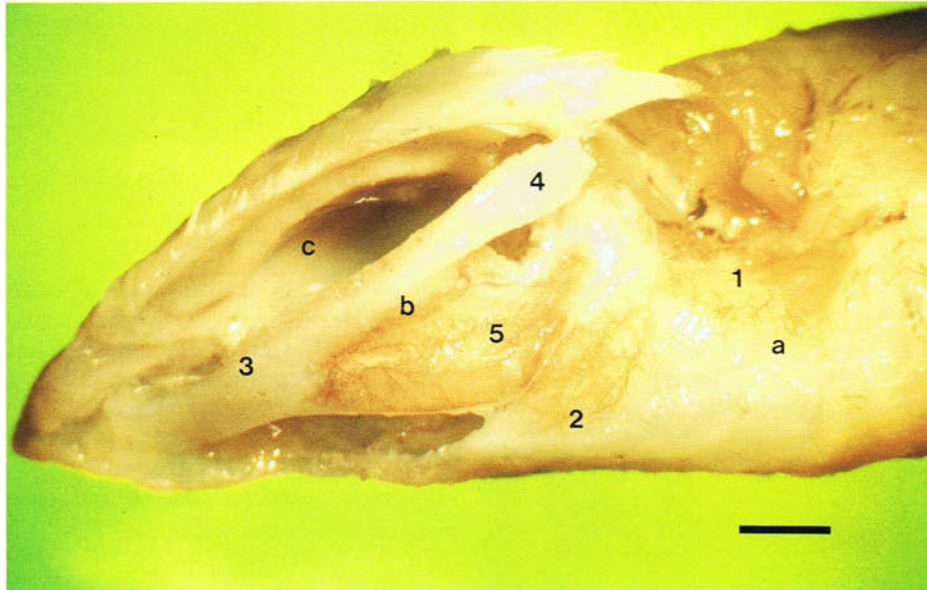


240 Laryngeal mound of a chicken. Dorsal view. The muscles and cartilages of the larynx form a prominent mound which protrudes into the caudal part of the floor of the oropharynx (see also 102). On its rostral surface is the glottis (a), the slit-like opening into the larynx. The margins of the glottis (arrow) are formed by the arytenoid cartilages (see 241). Unlike in mammals there is no epiglottis. The caudal part of the mound carries backward-pointing papillae (b) which are used in swallowing to rake food caudally into the oesophagus. (Scale, 2 mm)

241 and 242 Larynx of an adult duck. In **241** the laryngeal mucosa and muscles on the left side have been removed to show the cartilages. There are four laryngeal cartilages. The cricoid cartilage (a) is scoop-shaped with left and right lateral wings (1) and a median body (2). The wings articulate in the dorsal midline with the small procricoid cartilage (not shown in the photograph). In songbirds the wings are replaced by separate dorsal cricoid cartilages. The body of the cricoid in the duck has a median ventral crest (arrow in **242**) which projects dorsally into the lumen of the larynx. The arytenoid cartil-

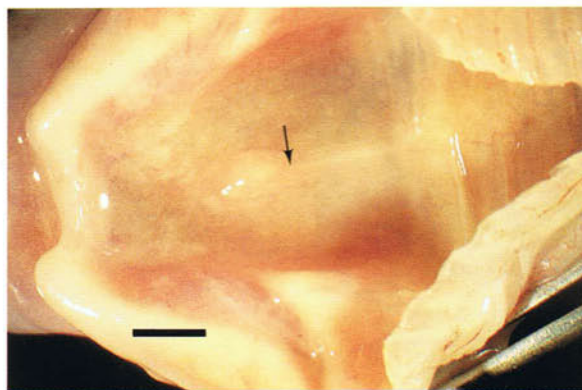
ages (b) are paired and form the margins of the glottis (c). Each is made up of rostral (3) and caudal (4) processes and a body (5). The body articulates with the procricoid and cricoid cartilages. In the chicken ossification of parts of the cartilages starts at about 3½ months of age. The size of the glottis is altered by constrictor and dilator muscles. As shown in **242** there are no vocal folds and, unlike in mammals, the larynx is not a source of sound. It is, however, important in preventing food and foreign material entering the lower respiratory tract.

241



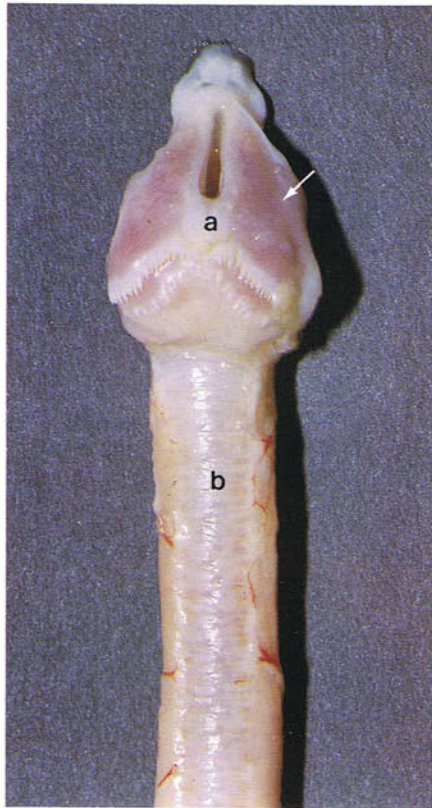
241 Laryngeal cartilages of an adult duck. Left dorso-lateral view. Fixed preparation. (Scale, 2 mm)

242



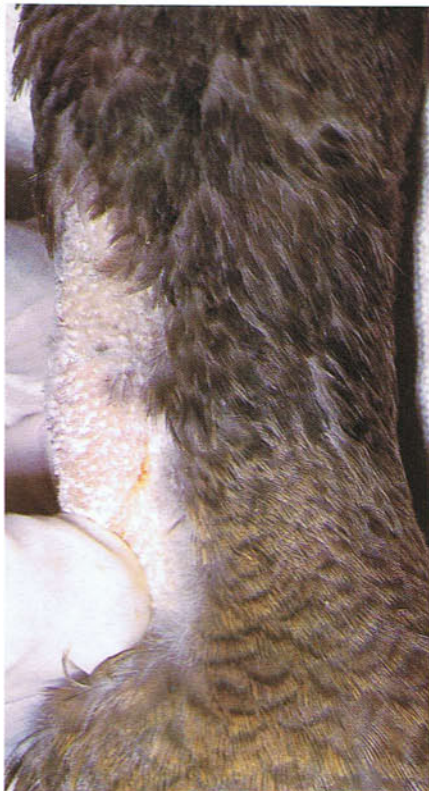242 Interior of the larynx of an adult duck. Dorsal view. (Scale, 2 mm)

243



243 Larynx and trachea of a chicken. Dorsal view. The larynx (a) is directly continuous caudally with the trachea (b) which unlike in mammals is surrounded by complete rings. The laryngeal muscles (arrow) lie below the mucosa on the dorsal surface of the laryngeal mound. While the resistance to air flow in the upper respiratory tract of birds is potentially greater than in mammals because of the relatively long neck, this is compensated for by a relative increase in tracheal radius.

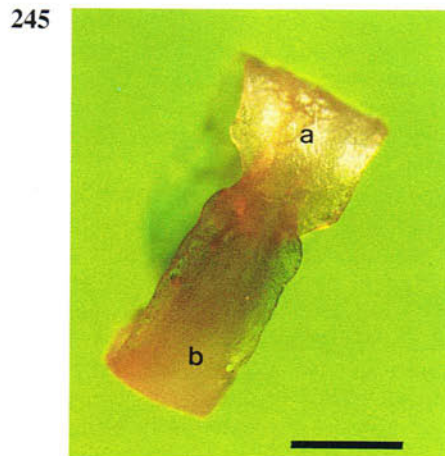
244



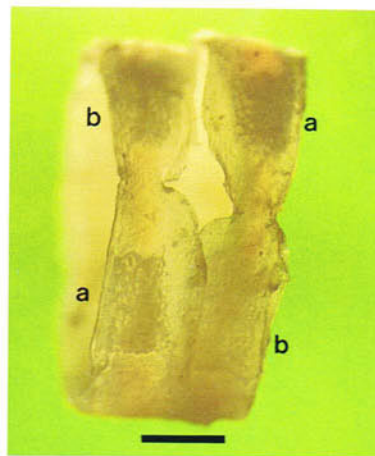
244 Neck of a chicken. Ventral view. Most of the trachea lies on the right side of the neck and can easily be palpated in the live bird. In some swans the trachea is massively elongated into coils that lie in an excavation of the sternum.

245 and 246 Tracheal cartilages. The tracheal cartilages are complete rings and consist of broad (a) and narrow (b) parts. The broad part of one cartilage

ring overlaps the narrow parts of the two adjacent rings.

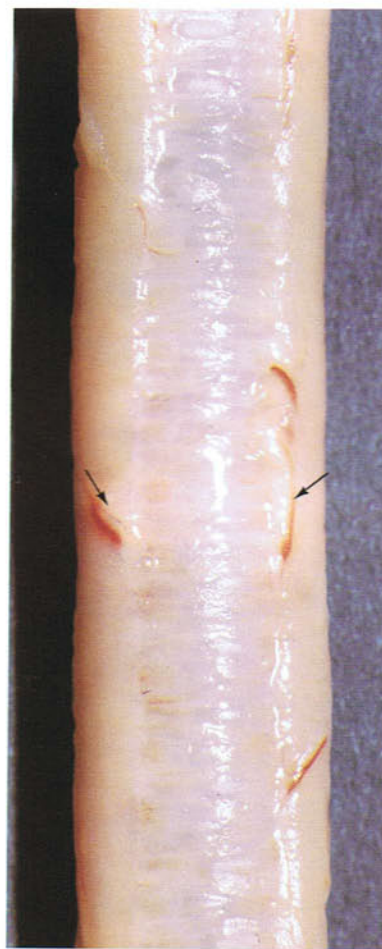


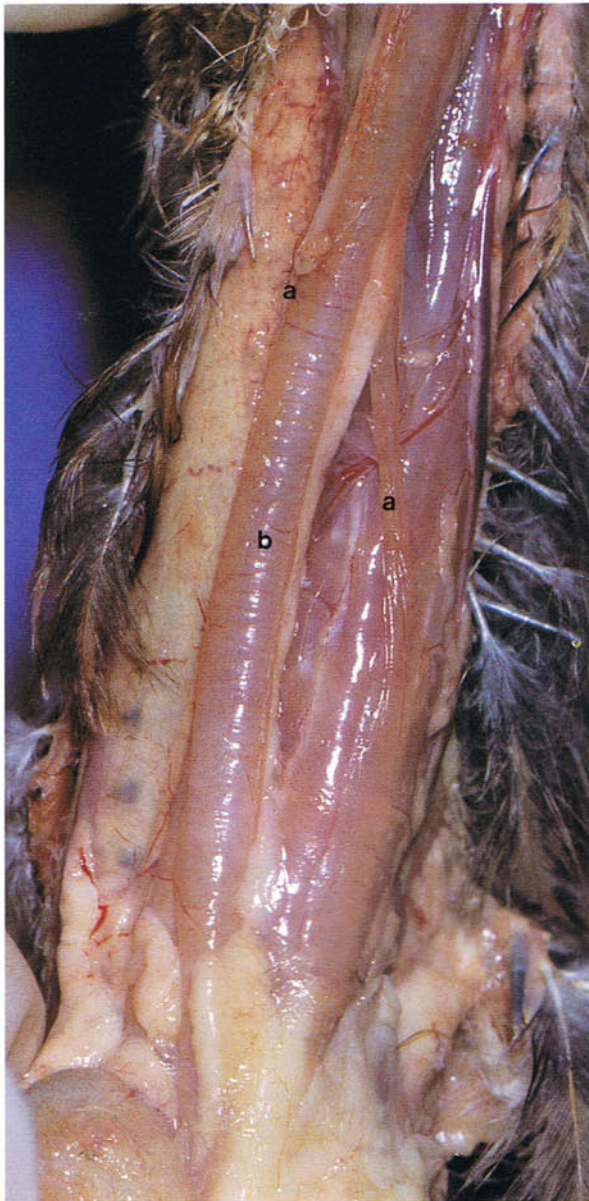
245 Tracheal cartilage of a chicken. (Scale, 2 mm)



246 Tracheal cartilages of a chicken. (Scale, 2 mm)

247 Tracheolateral muscles of a chicken. Dorsal view. The tracheolateral muscles (arrows) in the chicken extend from the caudal part of the trachea to the larynx and combine with the sternotracheal muscles (see 249 and 263) to form a composite muscle which encloses the trachea except dorsally. In most other species they have their origin on the syrinx (see 254). Their role in the chicken in controlling the tension of the syringeal membranes is discussed under 249-253.

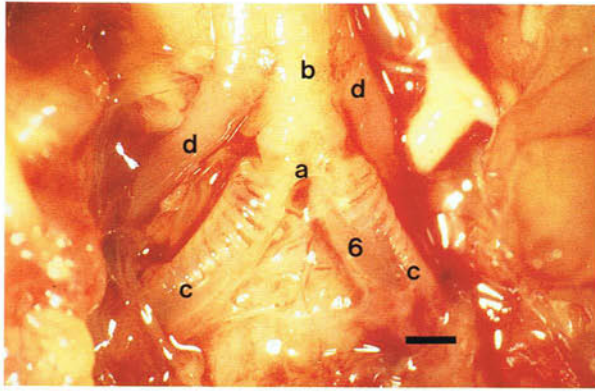




248 Cleidothyroid muscles of a 6-week-old chicken. Ventral view. Paired right and left cleidothyroid muscles (a) extend between the symphysis of the furcula and the larynx and are attached to the trachea by loose fascia. They act to pull the trachea caudally, relaxing its caudal part and therefore isolating the syrinx from the effects of movements of the trachea and neck.

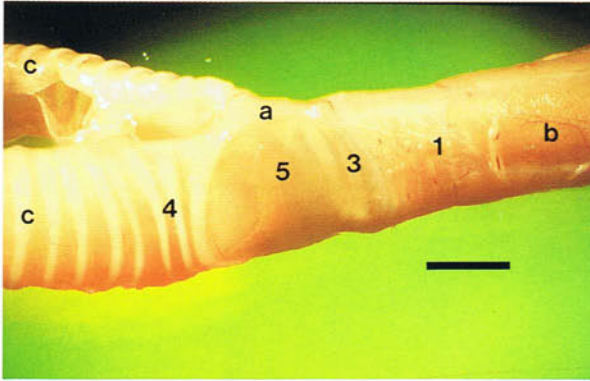
249-253 Syrinx of the chicken. The syrinx (a) is the source of sound. It lies at the junction of the trachea (b) and the right and left primary bronchi (c) (249 and 250). In most species the syrinx is partly tracheal and bronchial in origin and is highly variable in structure between species. Basically it is composed of variably ossified cartilages, vibrating membranes and muscles. In the chicken the cartilages consist of the tympanum (1) formed by the close apposition of four cartilaginous rings (250-252), the wedge-shaped pessulus (2) where the airway divides (visible in 252 in which the left lateral tympaniform membrane has been removed and in 251 through the transparent tympaniform membrane), four C-shaped tracheal syringeal cartilages (3) which are attached to the pessulus ventrally (250-252), and three C-shaped bronchial syringeal cartilages (4) (250, 251 and 253). There are two pairs of vibrating membranes. The paired lateral tympaniform membrane (5) extends between the last tracheal syringeal cartilage and the first bronchial syringeal cartilage (250 and 251). The paired medial tympaniform membrane (6) stretches between the free ends of the bronchial syringeal cartilages in the medial wall of the divided part of the syrinx (249, 251 and 253). In 249 the right and left sternotracheal muscles (d) can be seen (see also 231). Each muscle extends from the cranio-lateral process of the sternum to the trachea a short distance cranial to the syrinx and contributes to the fused tracheolateral muscles (see 247). The left sternotracheal muscle in the pigeon crosses over the trachea and fuses with the right muscle. Syringeal muscles are muscles which have one attachment to the syrinx. In the chicken true syringeal muscles are absent, the tracheolateral muscle, the syringeal muscle of most non-passerine species, ending caudally in front of the syrinx. Sound is produced only in expiration when a rise in pressure in the clavicular air sac (288) which surrounds the syrinx, forces the tympaniform membranes into the lumen of the syrinx. In the chicken contraction of the tracheolateral muscles tenses the membranes so that they vibrate when expired air flows over them, producing sound.

249



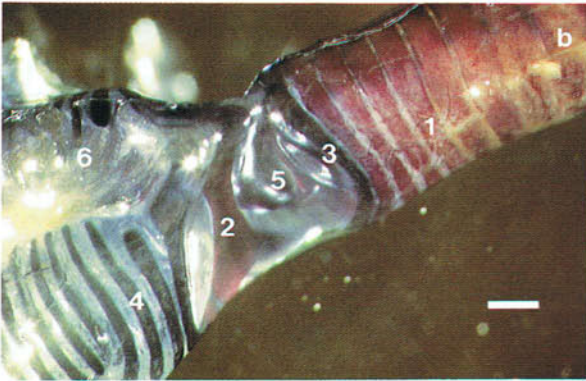
249 Syringe of a day-old chicken. Ventral view. (Scale, 1 mm)

250



250 Syringe of an adult chicken. Lateral view. (Scale, 2 mm)

251

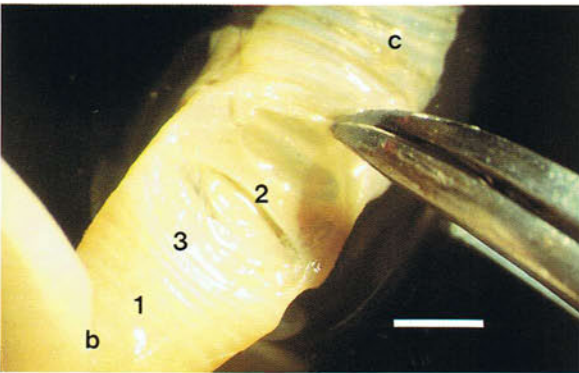


251 Syringe of an adult chicken. Lateral view. Toluidine blue and alizarin red S preparation. Bone appears red in colour, cartilage is dark blue, and soft tissue is transparent. (Scale, 1 mm)

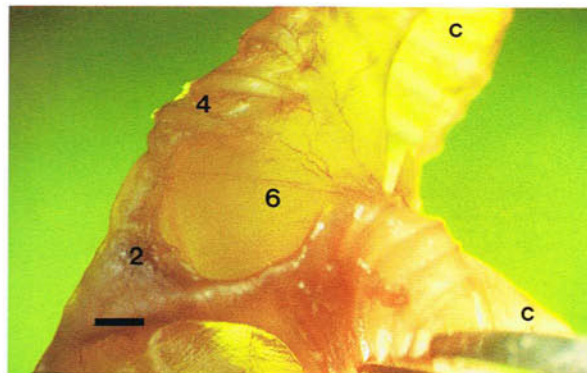
252 Syringe of an adult chicken with the left lateral tympaniform membrane removed. Lateral view. Fixed preparation. (Scale, 2 mm)

253 Syringe of an adult chicken. Lateral view. (Scale, 1 mm)

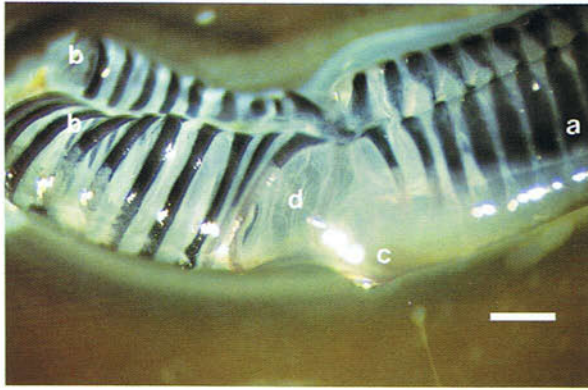
252



253

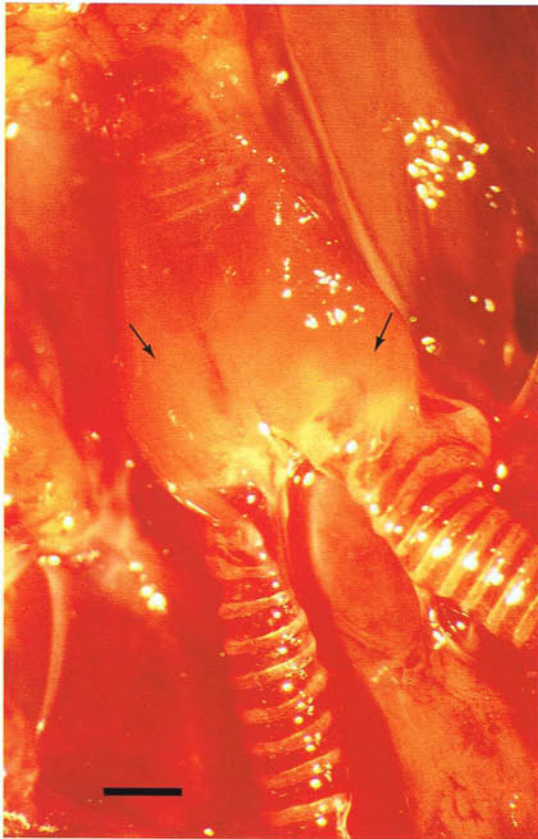


254



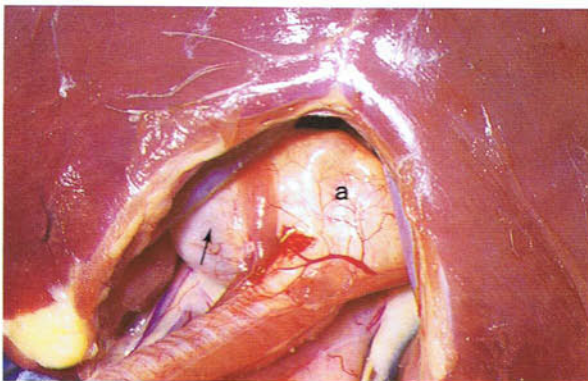
254 Syrinx of an adult pigeon. Lateral view. Toluidine blue and alizarin red S preparation. (a) Trachea; (b) right and left primary bronchi. The pigeon is typical of non-passerine species in having one pair of syringeal muscles, the tracheolaterals (c), which in this species attach directly to the lateral tympaniform membranes (d). The pessulus is not visible through the lateral tympaniform membrane because it is formed in the pigeon by connective tissue. (Scale, 1 mm)

255



255 Syrinx of an adult canary. Ventral view. Passerine species have four or five pairs of short syringeal muscles (arrows) which give the syrinx a fleshy appearance. Other features of the songbird syrinx are the reduction of the lateral tympaniform membrane to narrow strips between the bronchial syringeal cartilages and, in some species, the presence of lateral and medial lips or labia which project into the lumen and are probably important in regulating the voice. (Scale, 0.5 mm)

256

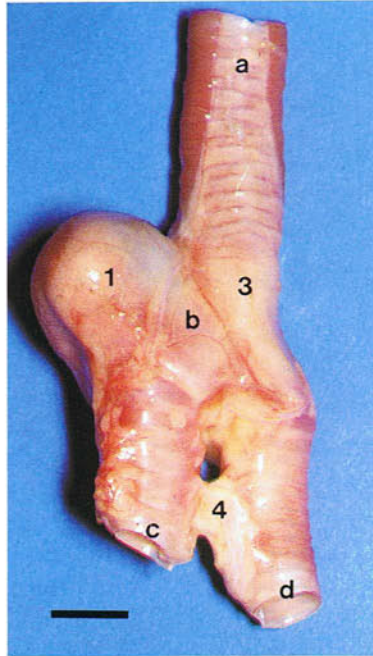


256 Syrinx of an adult male duck. Cranioventral view. The syrinx (a) in the male duck has a large bony dilation on the left side, the syringeal bulla (arrow), and almost fills the thoracic inlet.

257-259 Syrinx of an adult male duck: (a) trachea; (b) syrinx; (c) left primary bronchus; (d) right primary bronchus. (1) Major compartment of the syringeal bulla; (2) minor compartment of the syringeal

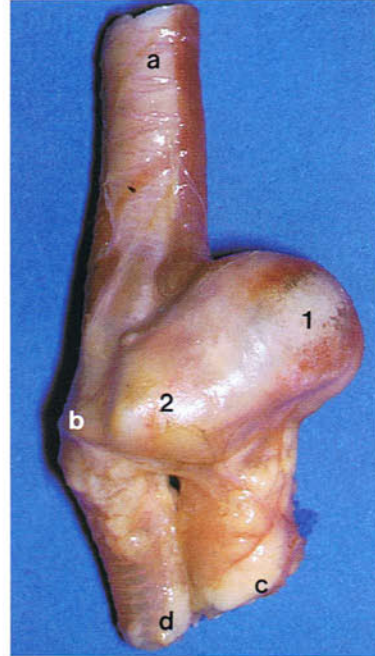
bulla; (3) tympanum; (4) interbronchial ligament. The syringeal bulla appears to be formed from the bronchial syringeal cartilages.

257



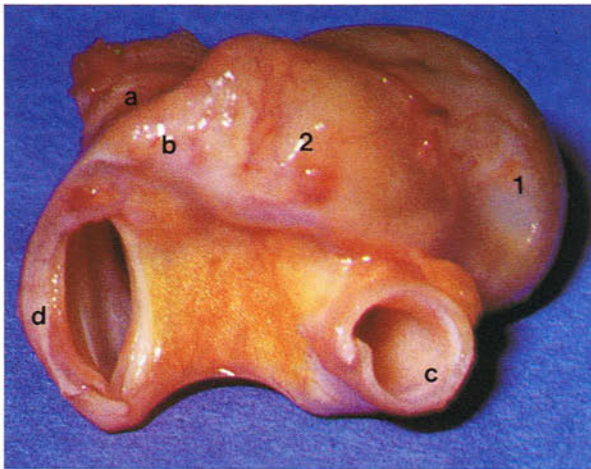
257 Syrinx of an adult male duck. Dorsal view. (Scale, 10 mm)

258



258 Syrinx of an adult male duck. Ventral view.

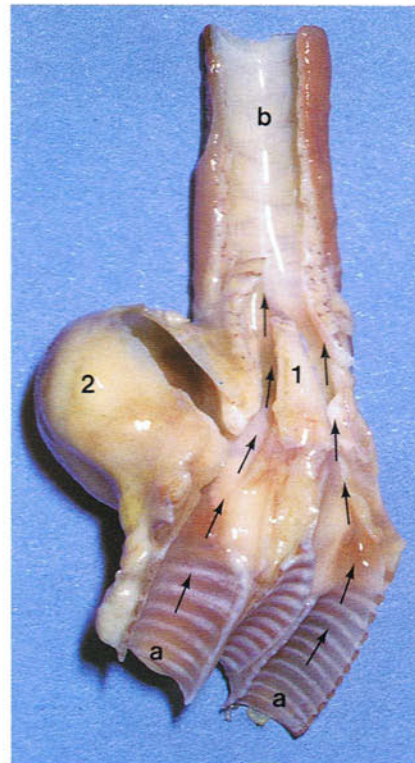
259



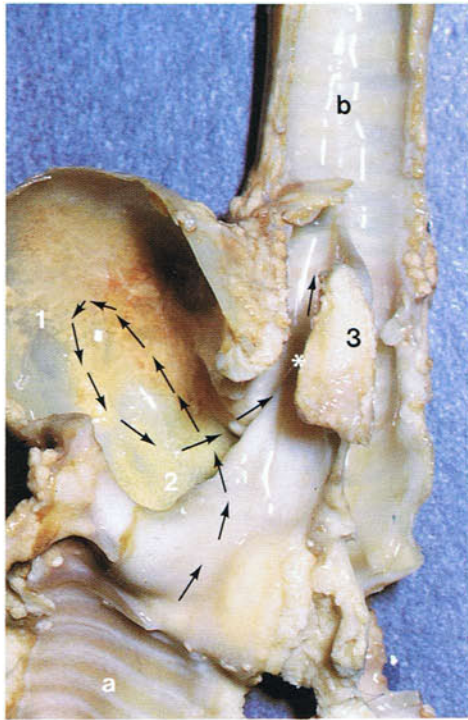
259 Syrinx of an adult male duck. Caudoventral view.

260 Syrinx of an adult male duck with the dorsal wall removed. Dorsal view. Fixed preparation. The direct pathways for expired air from the bronchi (a) to the trachea (b) are indicated by arrows. The pessulus (1) separates the left and right parts of the tympanum. See also syringeal bulla (2).

260



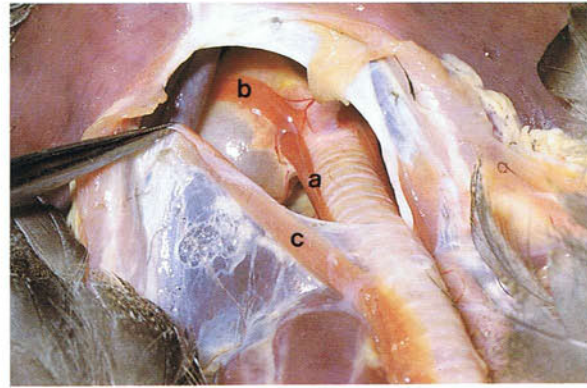
261



261 Syrinx of an adult male duck with the dorsal wall of the syringeal bulla fully removed. Dorsal view. Fixed preparation. The direct pathways shown in **260** may be closed if the syrinx is pulled caudally, so that the tympanum presses upon the right and left bronchi. Expired air now cannot escape from the right bronchus to the trachea. The direct pathway of the expired air in the left bronchus (a) is closed in the upper part of the tympanum at the point marked by the asterisk. The air instead appears to reach the trachea (b) by travelling first into the major compartment (1) of the syringeal bulla, and then down into the minor compartment (2) of the bulla from where it enters the lower part of the tympanum to the left of the pessulus (3). The arrows represent the air pathway.

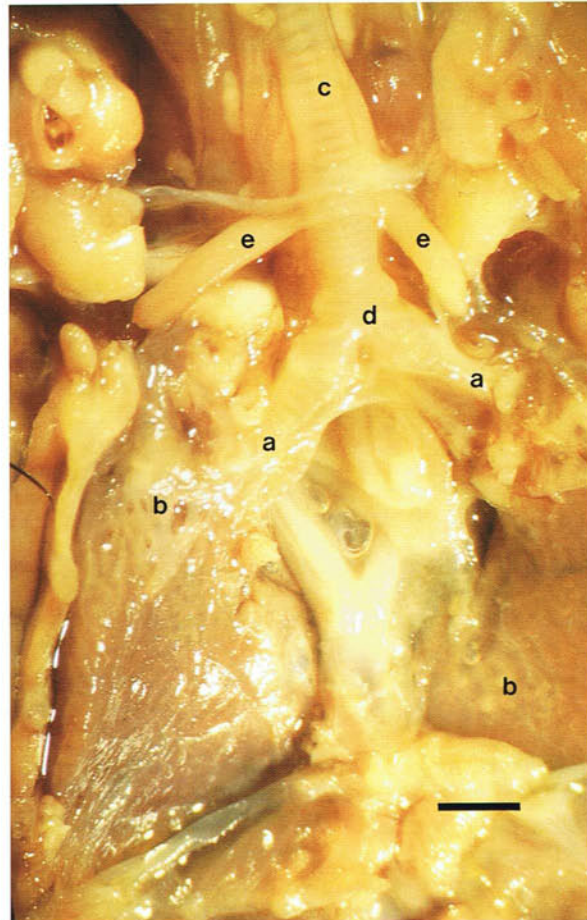
263 Primary bronchi of a day-old chicken. Ventral view. Fixed preparation. The left and right primary bronchi (a) enter the lung (b) on its septal surface: (c) trachea; (d) syrinx; (e) sternotracheal muscles. (Scale, 2 mm)

262

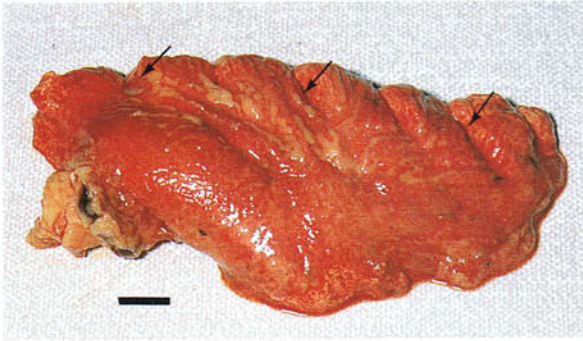


262 Tracheal muscles of an adult male duck. Cranio-ventral view. In addition to the tracheolateral (a) and sternotracheal (b) muscles found in most species, the duck has a third muscle, the cleidotracheal (c), which extends from the clavicle to the trachea.

263

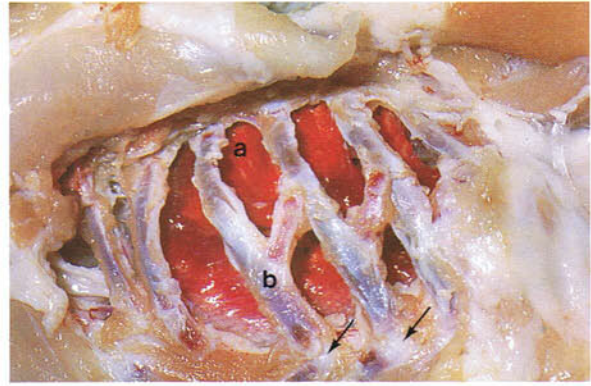


264



264 Left lung of an adult duck. Lateral view. Each lung is small, bright red, and triangular or quadrilateral in shape. It is not divided into lobes. The upper border has a row of grooves (arrows) in which the vertebral ribs are embedded. Unlike in mammals the avian lung undergoes little change in volume during breathing and, consequently, auscultatory signs of pulmonary infection are almost impossible to detect. (Scale, 5 mm)

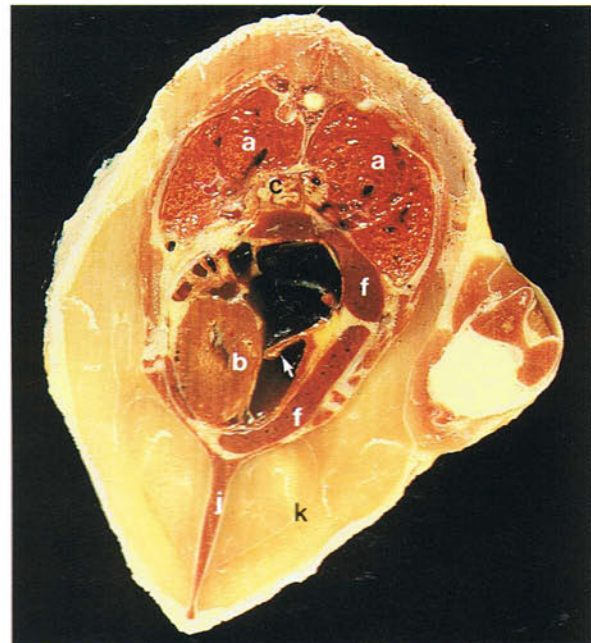265



265 Left lung of an 8-week-old chicken with the soft tissues of the thoracic wall removed. The lung (a) lies in the dorsal part of the thorax opposite the vertebral ribs (b) and does not extend ventrally beyond the junction (arrows) of the vertebral ribs and sternal ribs.

266 and 267 Thoracoabdominal viscera *in situ*: (a) lung; (b) heart; (c) oesophagus; (d) proventriculus; (e) gizzard; (f) liver; (g) testis; (h) kidney; (i) intestines; (j) keel of sternum; (k) breast muscles. In contrast to mammals the heart is surrounded by the liver and not the lungs. In **266** the muscular flap (arrow) of the right atrioventricular valve can be seen. The position of the uropygial gland is indicated by the arrow in **267**.

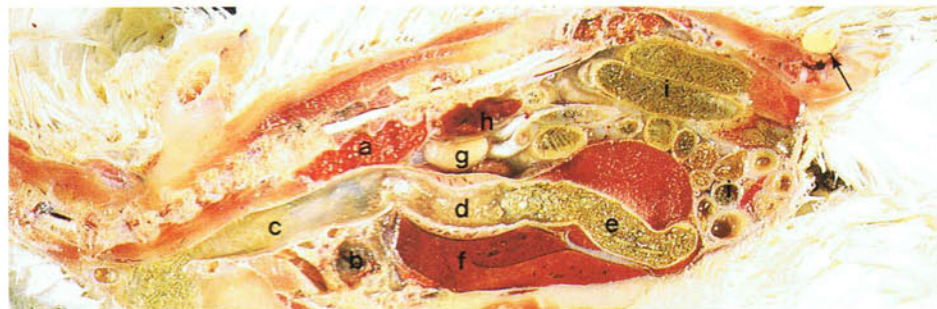
266

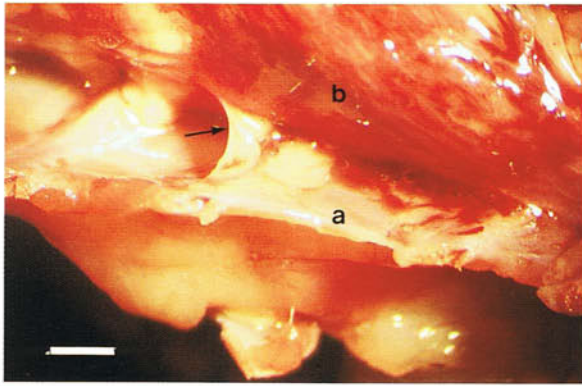


266 Transverse section through the thorax of an adult chicken. Caudal view.

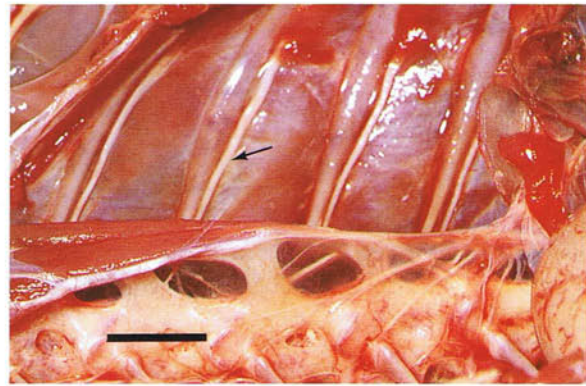
267 Longitudinal section through the trunk of an adult chicken. Left lateral view.

267





268 Pleural cavity of an 8-week-old chicken. Ventral view. The pleural cavity is reduced by connective tissue strands (arrow) uniting the parietal pleura (a) covering the ribs and the visceral pleura (b) covering the lungs. The cavity in the chicken seems to be best developed opposite the dorsolateral part of the lung, but in some places it is totally obliterated. (Scale, 2 mm)

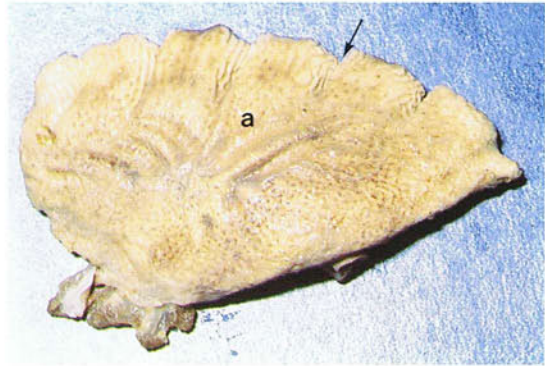


269 Intercostal nerves of an adult duck. Right medial view. The intercostal nerves (arrow) can be seen after removal of the lungs. They lie below the parietal pleura and caudal to the ribs. They may easily be examined post-mortem. (Scale, 10 mm)

270 and 271 The lung surfaces. The lung has three surfaces. The costal surface (a) is dorsolateral and lies opposite the thoracic wall. The vertebral surface (b) is dorsomedial and faces the vertebrae. The

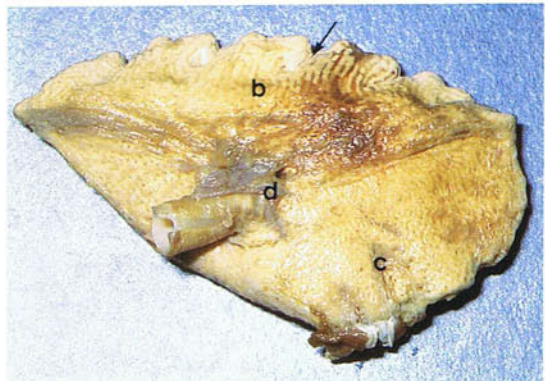
septal surface (c) is ventromedial and is covered by the horizontal septum (296). The hilus (d) of the lung is present on this surface. Note the grooves (arrows) for the ribs at the costovertebral border.

270 Right lung of an adult duck. Lateral view. Fixed preparation.

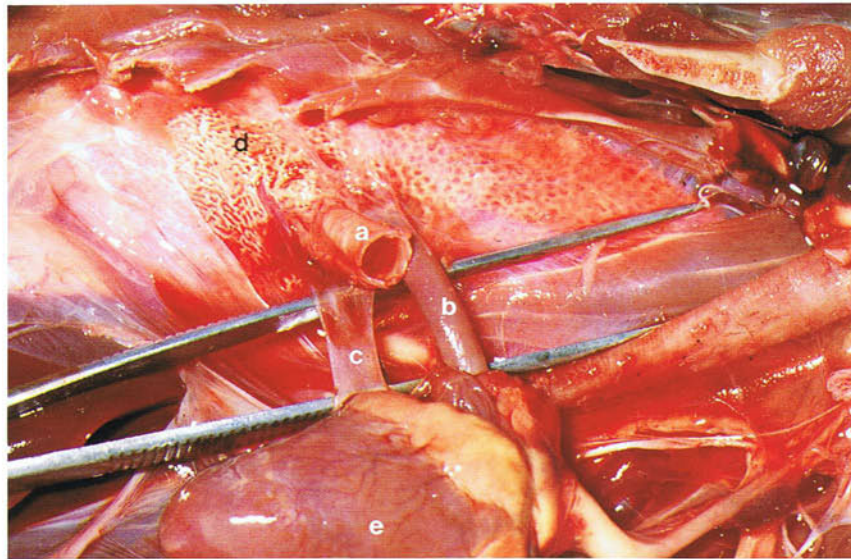


270

271 Right lung of an adult duck. Medial view. Fixed preparation.



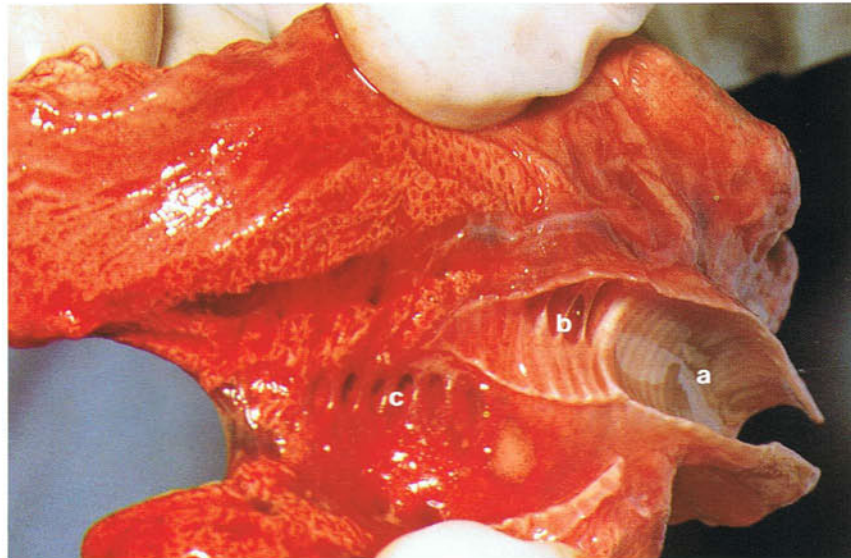
271



272

272 Hilus of the right lung of an adult duck. Ventral view. On the septal surface of the lung lies the hilus where the primary bronchus (a), the pulmonary

artery (b) and pulmonary vein (c) enter the lung (d): (e) heart.



273

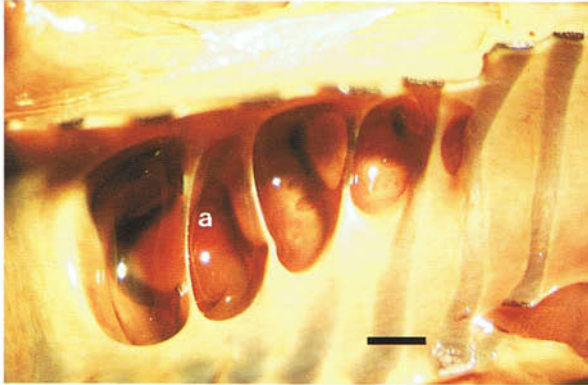
273 Lung of an adult duck with the primary bronchus cut open. Lateral view. The air passages of the lung consist of a primary bronchus which extends to the caudal border of the lung; four groups of secondary bronchi which arise from the primary bronchus and are named according to the parts of the lung they supply; and parabronchi which arise from the secondary bronchi, anastomose freely with each other, and contain the gaseous exchange tissue in their walls. In the photograph the openings of two of the groups of secondary bronchi are visible in the

wall of the primary bronchus (a). These are the medioventrals (b) and the mediodorsals (c) which are arranged in almost straight lines. The straight line of openings formed by the lateroventral secondary bronchi and the scattered openings of the laterodorsals cannot be seen. In birds generally, there are about four medioventral bronchi, eight mediodorsal bronchi, eight lateroventral bronchi, and 25 laterodorsal bronchi. The bulk of the lung is formed by parabronchi.

274 and 275 Openings of secondary bronchi in the primary bronchus of an adult duck: (a) medioventral secondaries; (b) mediiodorsal secondaries; (c) laterodorsal secondaries. The openings of the medioventrals are oval and orientated transversely to the long axis of the primary bronchus. They are separated by cartilage. Compared with the other secondary bron-

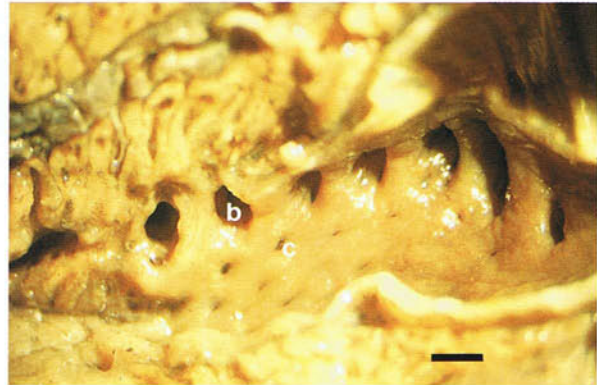
chi the laterodorsals are very numerous and do not arise in a straight line. The medioventrals and the mediiodorsals, and the parabronchi they give rise to, form the thick medial part of the lung and all the cranial part. The lateroventral and laterodorsal secondary bronchi, and the parabronchi they give rise to, form the thin lateral part of the lung.

274



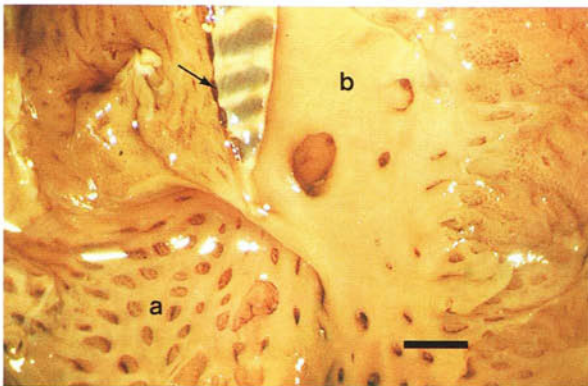
274 Openings of the medioventral secondary bronchi in the primary bronchus of an adult duck. Lateral view. Fixed preparation. (Scale, 1 mm).

275



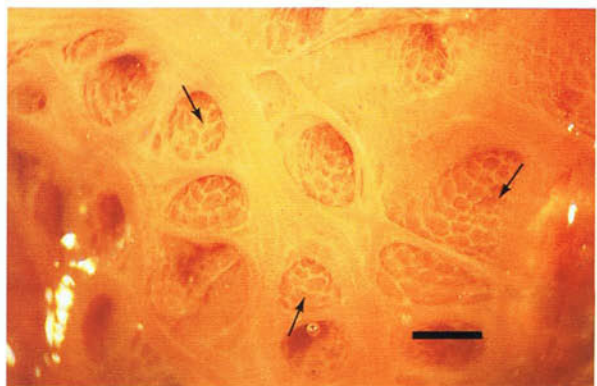
275 Openings of the mediiodorsal and laterodorsal bronchi in the primary bronchus of an adult duck. Lateral view. Fixed preparation. (Scale, 3 mm)

276



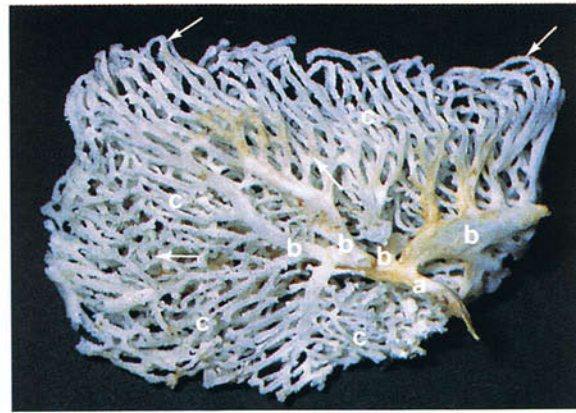276 Structure of a secondary bronchus of an adult duck. Fixed preparation. A large medioventral secondary bronchus (a) has been cut open close to its origin from the primary bronchus (b). In the wall of the secondary bronchus are the numerous openings of the parabronchi. The cartilages of the lung are restricted to the cranial part of the primary bronchus and some of them (arrow) can be seen. (Scale, 2 mm)

277



277 Large mediiodorsal secondary bronchus of an adult duck cut open close to its origin from the primary bronchus. In the wall of the bronchus are the openings of the parabronchi. The small openings or atria (arrows) visible in the walls of the parabronchi lead into the exchange tissue of the lung. (Scale, 0.5 mm)

278 Bronchi of the left lung of an adult chicken. Vinylite cast. Medial view. The primary bronchus (a), the four medioventral secondary bronchi (b), and numerous parabronchi (c) can be seen. There are many anastomoses, either end to end (upper arrows) or transversely (lower arrow), between the parabronchi.

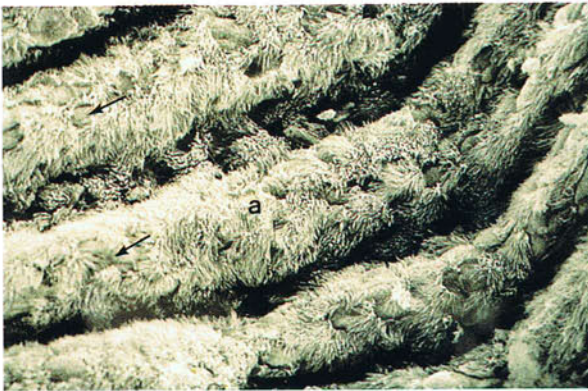

278

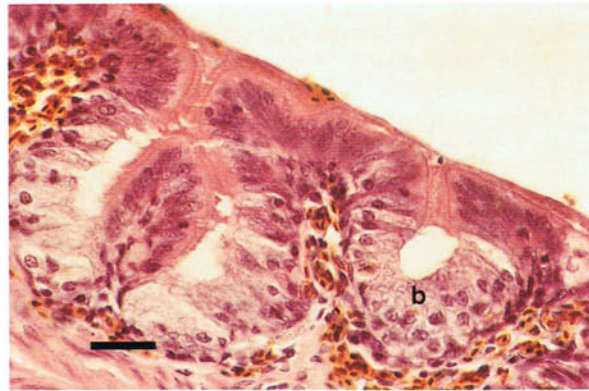
279 and 280 Interior of the primary bronchus. The inner surface is raised into ciliated longitudinal folds (a) with goblet cells which occur either singly (arrows) or

grouped together mainly between the folds as shallow intraepithelial alveolar glands (b).

279



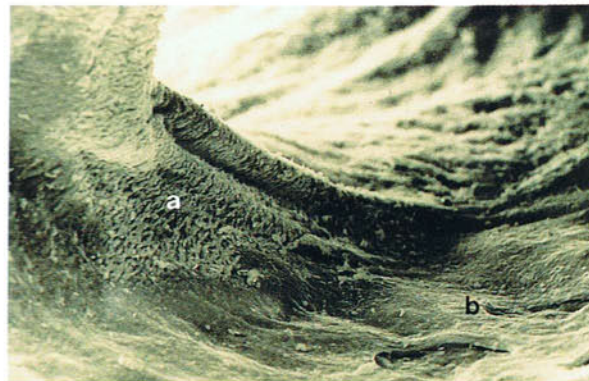
279 Scanning electron micrograph of the interior of the primary bronchus of a Ringed Turtle Dove (*Streptopelia risoria*). $\times 555$. From McLelland, J. and MacFarlane, C.J. (1986). *J. Anat.* **147**, 83-93.



280

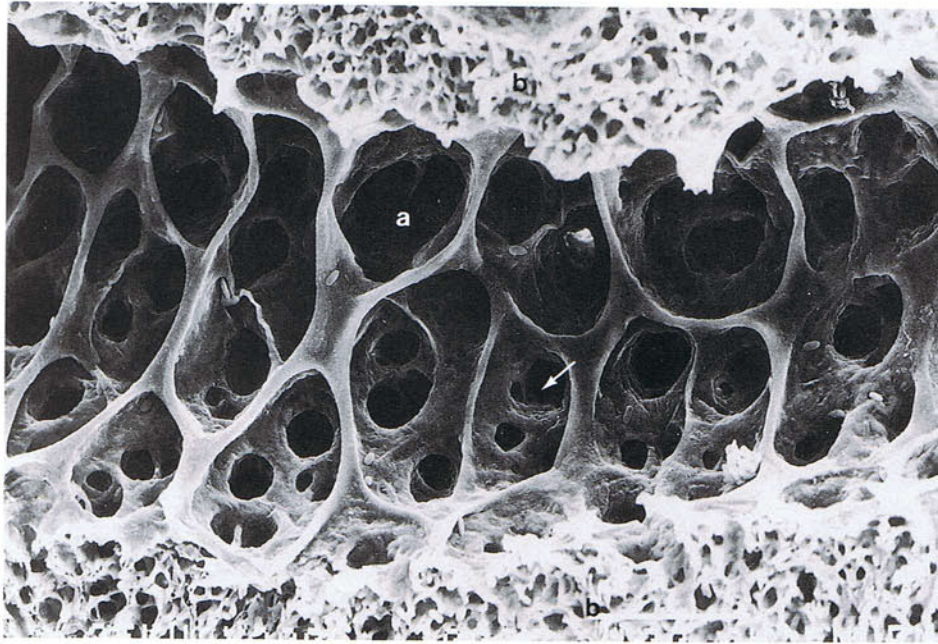
280 Light micrograph of the epithelium of the primary bronchus of a chicken. Haematoxylin and eosin. (Scale, $1 \mu\text{m}$)

281 Scanning electron micrograph of the interior of the origin of a medioventral secondary bronchus of a Ringed Turtle Dove (*Streptopelia risoria*). Here folded ciliated areas (a) alternate with flat unciliated areas (b) in an apparently haphazard manner. In this species a flat, mainly unciliated surface also surrounds the entrances to the laterodorsal secondary bronchi and many of the lateroventral and medio-dorsal bronchi. $\times 105$. From McLelland, J. and MacFarlane, C.J. (1986). *J. Anat.* **147**, 83-93.



281

282



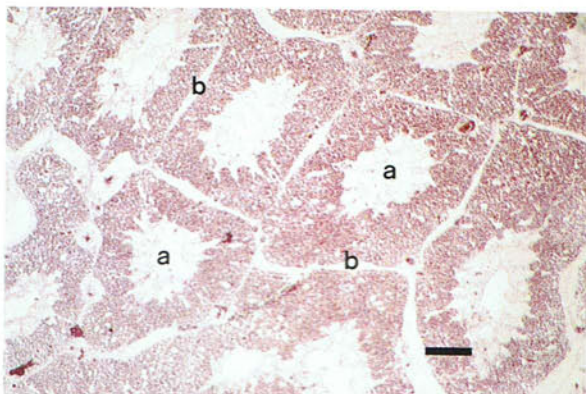
282 Scanning electron micrograph of a parabronchus, cut in longitudinal section, in the lung of an adult Red Jungle Fowl. The inner surface has numerous openings which lead into spherical chambers, the atria (a). In the floor of each atrium are the openings

of the infundibula (arrow) which lead to the air capillaries of the exchange tissue (b). Despite their name, the wall structure of large lengths of the secondary bronchi is identical to that of a parabronchus. $\times 200$.

283 and 284 Histological structure of the parabronchus. The parabronchi (a) are separated by interparabronchial septa (b). The lumen of each parabronchus is lined by a simple squamous epithelium and communicates with spherical chambers, atria (c), in its wall. At the openings of the atria are spiral bands of

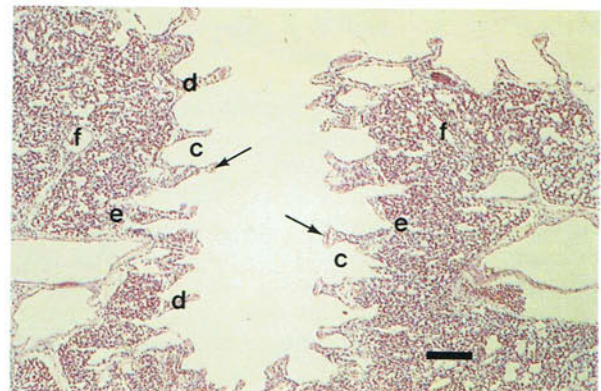
smooth muscle bundles (arrows). The atria are separated by interatrial septa (d). Funnel-shaped ducts, the infundibula (e), in the floor of the atria lead to the air capillaries of the exchange tissue (f). The exchange tissue is formed by networks of air capillaries and blood capillaries.

283

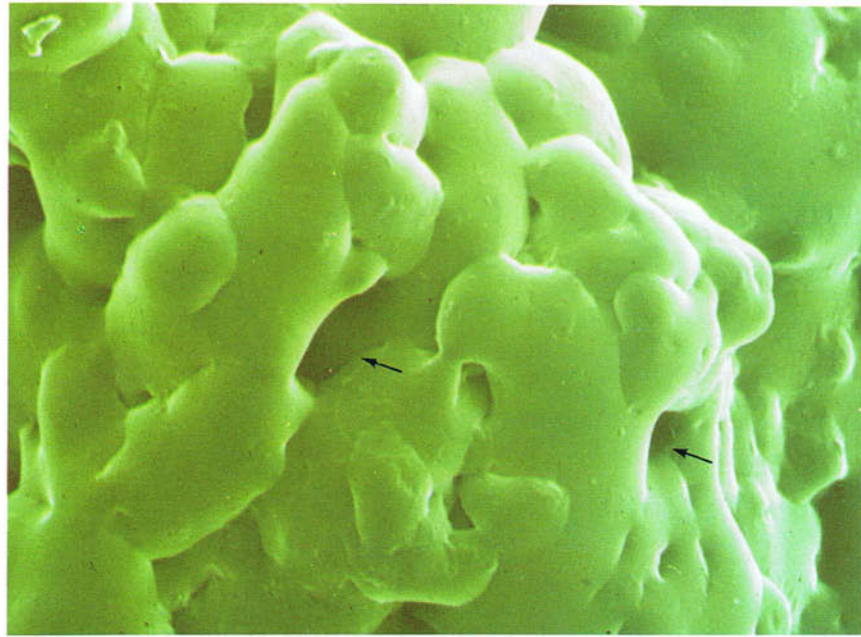


283 Light micrograph of the parabronchi in the lung of a chicken cut in transverse section. Haematoxylin and eosin. (Scale, $250 \mu\text{m}$)

284



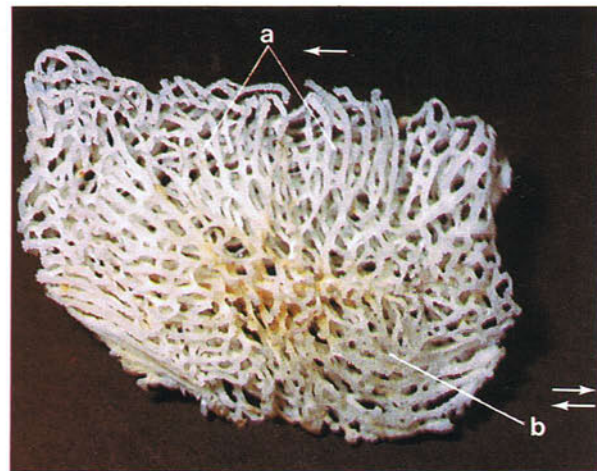
284 Light micrograph of part of a parabronchus, cut in longitudinal section, in the lung of a chicken. Haematoxylin and eosin. (Scale, $70 \mu\text{m}$)

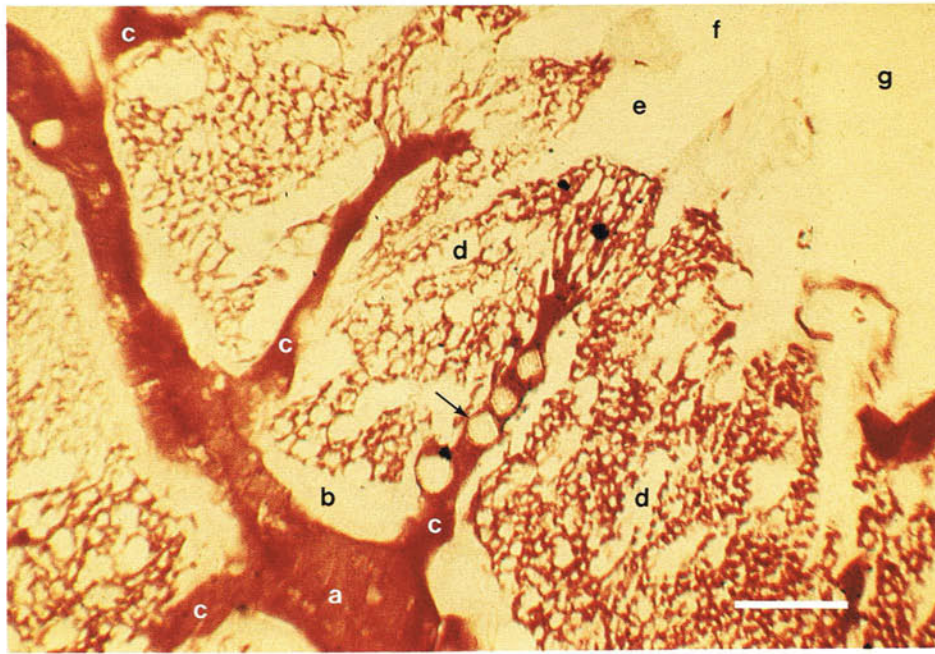


285 Scanning electron micrograph of a latex cast of the air capillary network in the lung of a chicken. The space between the cast (arrows) is occupied by blood capillaries. The air capillaries, unlike the mammalian alveoli, anastomose freely and have a much smaller

diameter. Consequently the area for gaseous exchange is relatively much greater in the avian lung. Gaseous exchange in birds is facilitated by the relatively thin blood-gas barrier. $\times 1790$. From Maina, J.N. (1982). *Experientia* **38**, 614-615.

286 Left lung of an adult chicken. The paleopulmo and neopulmo. Vinylite cast. Lateral view. Within the avian lung two portions, the paleopulmo and neopulmo, can be distinguished. Although the validity of these terms is still being questioned, the concept has proved invaluable to the understanding of pulmonary function. The paleopulmo consists essentially of the medioventral and mediodorsal secondary bronchi and their parabronchial connections. In the chicken it forms about 75 per cent of the lung. Part of the paleopulmo (a) is visible on the upper part of the costal surface of the lung. A feature of the paleopulmo is that air flows unidirectionally in it from caudal to cranial (arrow) in both inspiration and expiration. The neopulmo is variably developed and is seen in its most advanced form in chickens, pigeons and passerine species in which it occupies the whole of the lateroventral part of the lung as an anastomosing network (b). Unlike in the paleopulmo, air in the neopulmo changes direction (arrows) with the phase of breathing.

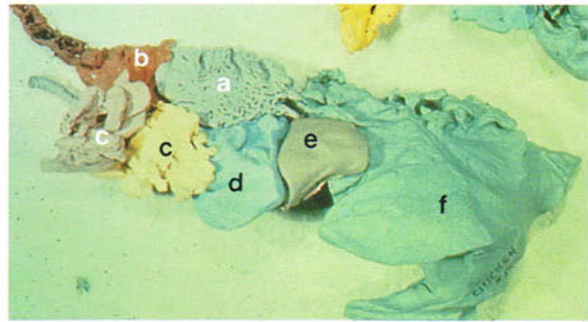




287 Light micrograph of the blood supply of the parabronchi of the chicken lung. The lung has been stained with haematoxylin and the arteries injected with gelatin containing *Lycopodium* spores. While the gelatin has filled the arteries, arterioles and capillaries, the spores (arrow) have been held up in the arteries and arterioles. The terminal interparabronchial artery (a) encircles the parabronchi in the interparabronchial septum (b) and gives off intraprabronchial arterioles (c) which form capillaries in the exchange tissue (d). The volume of capillary blood in the exchange tissue per gram body weight is much greater in birds than in mammals. In the exchange tissue therefore air diffuses from the parabronchial lumen into the air capillaries in the opposite direction to the flow of blood. Thus, a counter-current-like mechanism exists because, as

the blood flows towards the parabronchial lumen, it meets air of progressively higher pO_2 and lower pCO_2 . In contrast, in the parabronchial part of the lung a cross-current mechanism exists between bulk parabronchial gas flow and capillary blood flow, because the air in its unidirectional course along the parabronchus changes in composition as it undergoes gaseous exchange with capillary blood, so that blood is arterialized less and less along the parabronchus. The existence of these counter-current and cross-current mechanisms is an important factor in the very high gas exchange efficacy of the avian lung. See also infundibulum (e), atrium (f), parabronchial lumen (g). (Scale, 90 μm) From Abdalla, M.A. and King, A.S. (1975). *Respir. Physiol.* **23**, 267-290.

288 Air sacs of an adult chicken. Latex cast. The bronchi extend outside the lung (a) in the form of thin-walled transparent chambers called air sacs. The air sacs in the chicken consist of the unpaired cervical sac (b), the unpaired clavicular sac (c), the paired cranial thoracic (d) and caudal thoracic (e) sacs, and the paired abdominal sac (f). The cervical sac has tubular diverticula which extend up the neck on each side of the vertebral column as far as the axis. The clavicular sac also has diverticula which extend around the heart and between the muscles and bones of the thoracic girdle and shoulder joint. The abdominal sacs have perirenal diverticula which extend between the kidney and pelvis, and femoral diverticula which surround the head of the femur and penetrate between the thigh muscles. A common



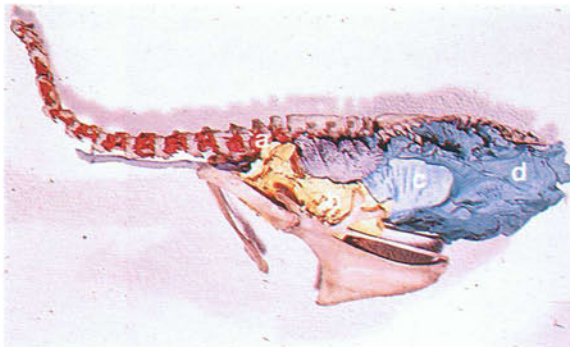
288

clinical condition of the air sacs is air sacculitis. Consequently when trimming a carcass infected with air sacculitis in the poultry slaughter plant, the existence of these diverticula must be taken into consideration.

289 and 290 Air sacs of an adult turkey. Latex casts. In turkeys the arrangement of the air sacs is relatively unusual. They consist of the cervical (a) and clavicular (b) parts of the unpaired cervicoclavicular sac, the paired cranial thoracic sac (c), and the

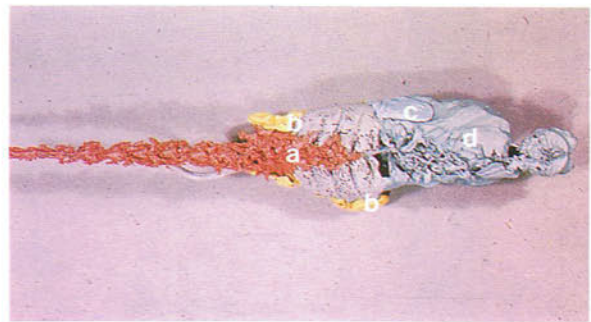
paired abdominal sac (d). A paired medial clavicular sac is also present but is not visible in the photograph. Note the tubular extensions of the cervico-clavicular sac up the neck.

289



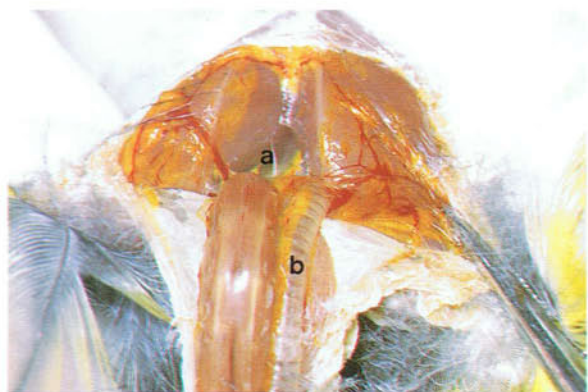289 Air sacs of an adult turkey. Latex cast. Lateral view.

291 Clavicular air sac of an adult canary. Ventral view. The median chamber of the unpaired clavicular sac (a) occupies the ventral part of the thoracic inlet and extends from the clavicles to the heart. It is closely related to the syrinx and is important in vocalization. In passerines the clavicular sac communicates with the cranial thoracic sacs. In the chicken the median chamber can be entered in the live bird by passing through the breast muscles just cranial to the ventral end of the first sternal rib. See also trachea (b).



290

290 Air sacs of an adult turkey. Latex cast. Dorsal view.

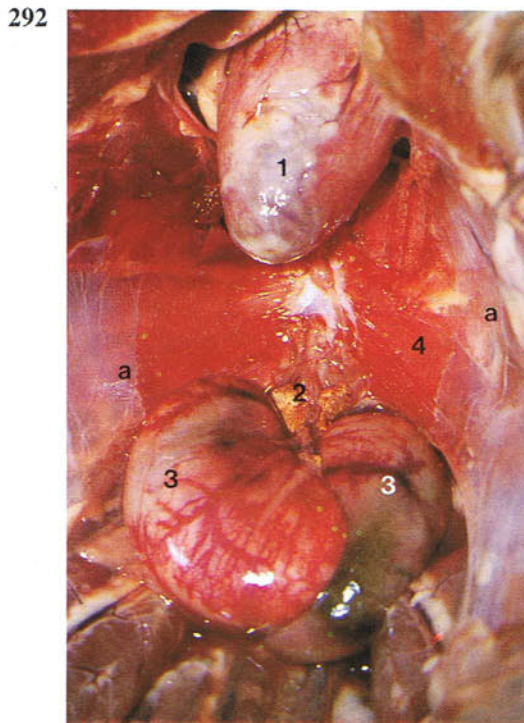


291

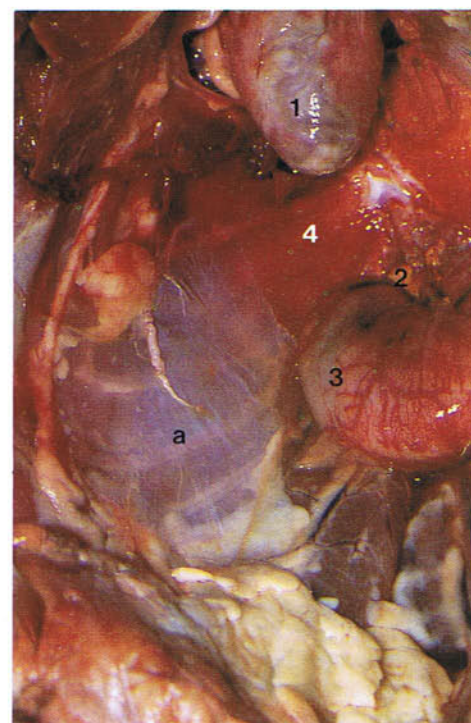
292-296 Oblique and horizontal septa. Cranial and caudal thoracic air sacs. The thoracic air sacs lie essentially ventral to the lungs. During embryonic development the double-layered pulmonary fold separating the pleural and peritoneal cavities is split by ingrowths of bronchi which eventually form the cranial and caudal thoracic air sacs. The dorsal layer of the fold becomes the parietal pleura on the ventral surface of the lung and forms the horizontal septum. The septum fuses ventrally with the dorsal walls of the thoracic air sacs. The ventral layer of the pulmonary fold forms the parietal peritoneum and becomes the oblique septum. This septum fuses dorsally with the ventral walls of the air sacs. Figures 292 and 293 are ventral views of the oblique septa (a) from within the peritoneal cavity, 292 of the right and left septa and 293 of the right septum. Each septum extends from the midline close to the heart (1), adrenal glands (2) and testes (3) to the lateral wall of the thorax. The part of the septum closest to the midline contains smooth muscle (4). Immediately below the septa are the cranial and caudal thoracic air sacs, which are visible in 293. Figure 294 is a ventral view of the left septum (a) from within the peritoneal cavity. Through the

septum, and separated from it by the air sacs and horizontal septum, part of the left lung (arrow) can be made out. In 295 the left oblique septum (a) has been cut exposing the cavities of the cranial thoracic (b) and caudal thoracic (c) air sacs. In 296 the oblique septum and the ventral and lateral walls of the air sacs have been removed exposing the cavities of the sacs.

The membrane (d) covering the lungs and extending to the lateral wall of the thorax is therefore fused air sac wall and horizontal septum through which the lung can be seen clearly. The remains of the partition between the cranial and caudal thoracic air sacs are indicated by an arrow. Where the horizontal septum attaches to the ribs are fascicles of striated muscle which form the costoseptal muscle (5). This muscle is known to contract in expiration, and by preventing any narrowing of the ostia it ensures that resistance to air flow is not increased. In the chicken the large cranial thoracic sac can be entered in the live bird between the middle of the third and fourth sternal ribs. The small caudal sac can be entered between the ventral ends of the last two ribs.

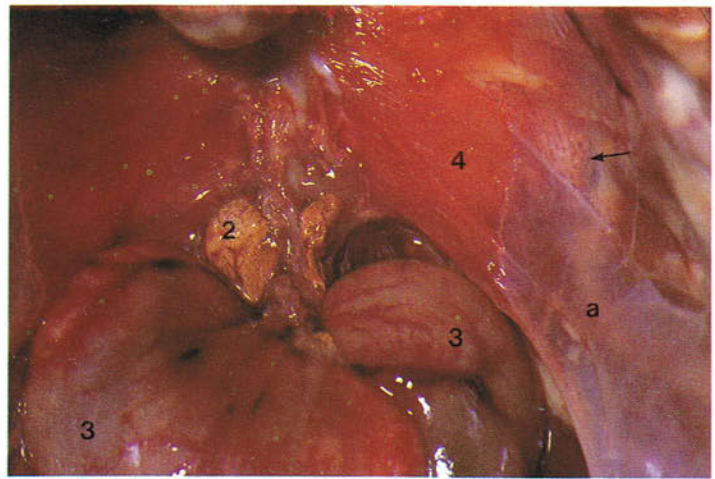


292 Left and right oblique septa of an adult chicken. Ventral view.



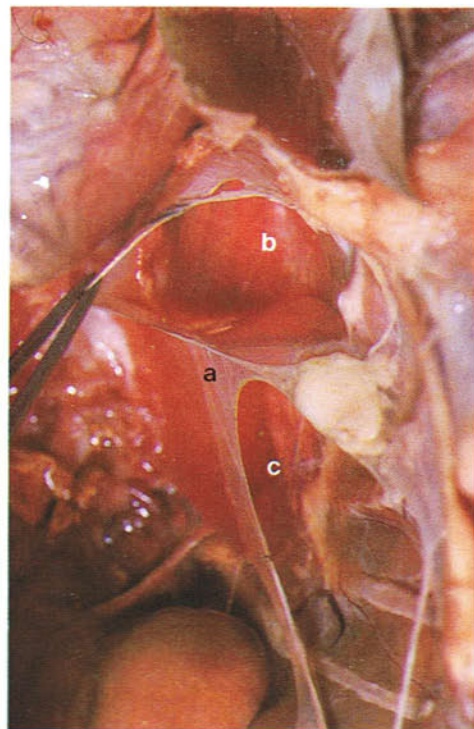
293 Right oblique septum of an adult chicken. Ventral view.

294 Left oblique septum of an adult chicken. Ventral view.



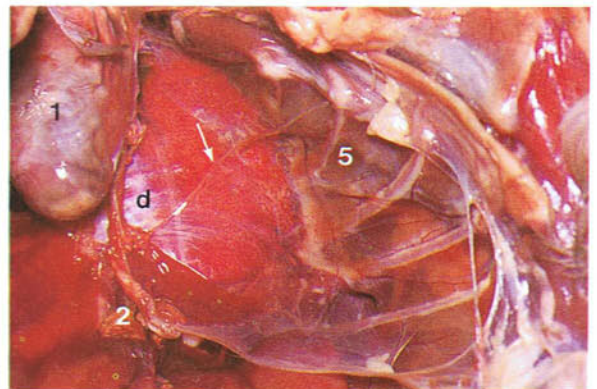
294

295 Left cranial and caudal thoracic air sacs of an adult chicken. Ventral view.

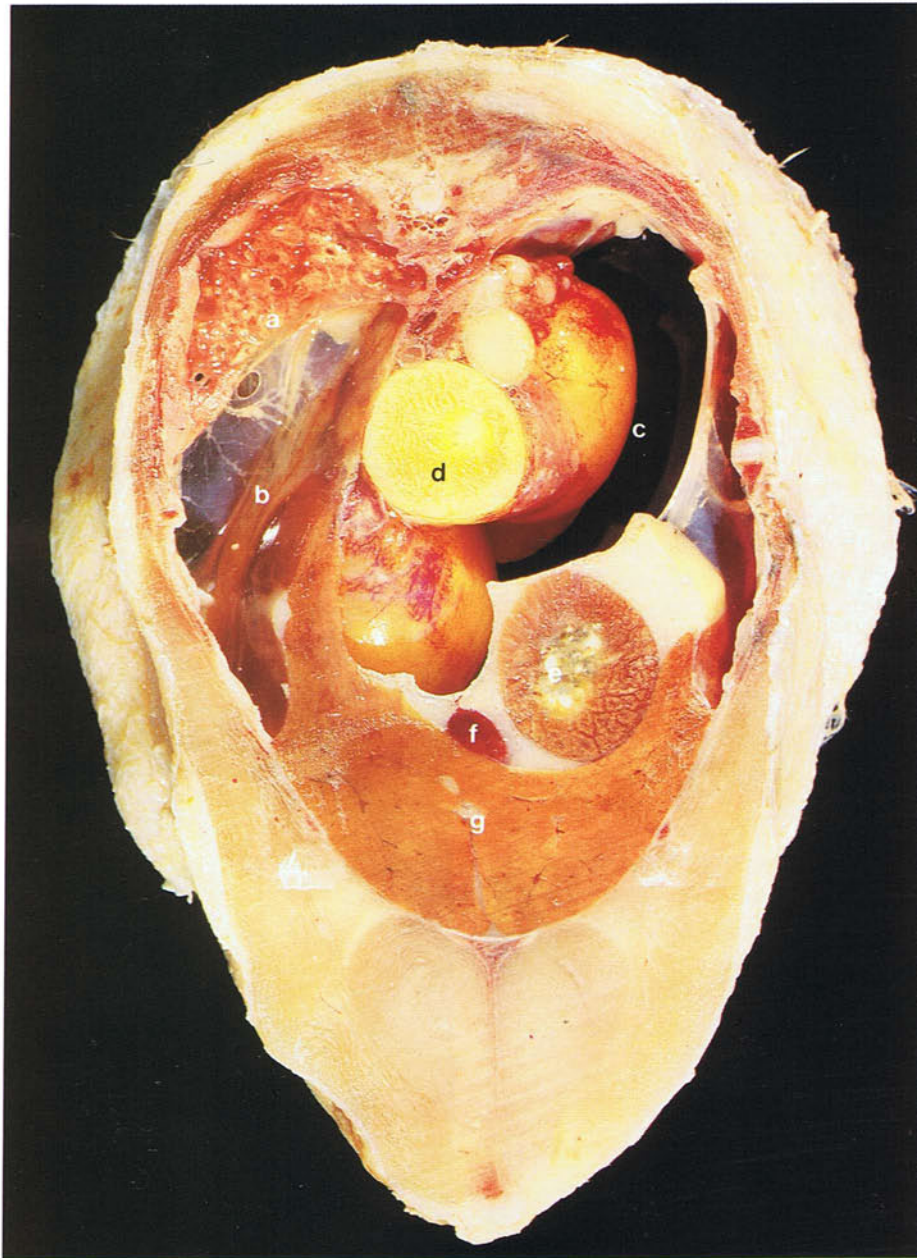


295

296 Left horizontal septum of an adult chicken. Ventral view.



296



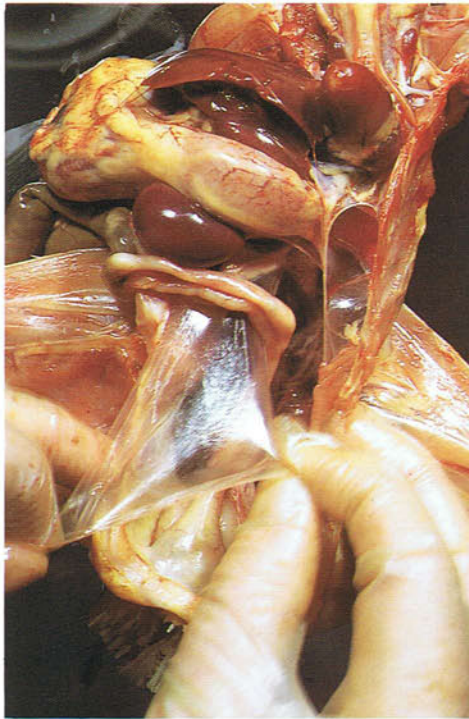297 Transverse section through the thoracoabdominal cavity of an adult chicken to show the position of the cranial and caudal thoracic air sacs in relation to the other viscera. Cranial view. The section

has been cut slightly obliquely so that only the right lung is visible. (a) Right lung; (b) thoracic air sacs; (c) abdominal air sac; (d) ovary; (e) proventriculus; (f) spleen; (g) liver.

298 and 299 Abdominal air sac. The abdominal air sac is always paired and invaginates the intestinal peritoneal cavity to lie between the abdominal viscera. It is the largest air sac, and in the live chicken can be entered between the caudal border of the proximal end of the last rib and the lateral border

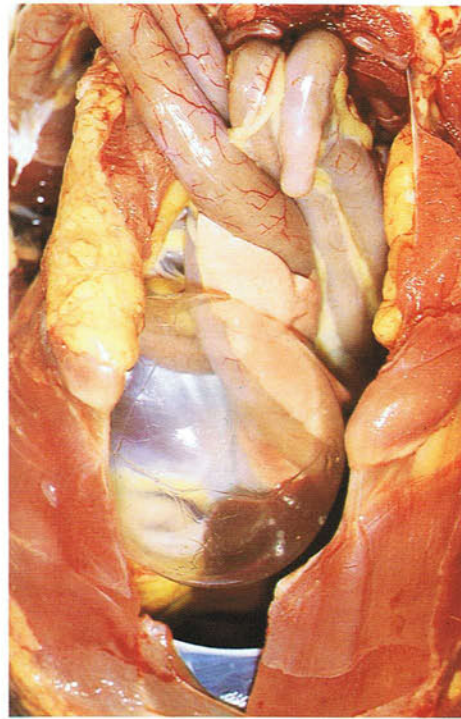
of the ilium. The photographs demonstrate the thin-walled, transparent nature of air sacs and their relative avascularity. Because of the presence of air sacs within the peritoneal cavity, so-called 'intra-peritoneal injections' are most likely to be intrapulmonary because it is difficult to avoid an air sac.

298



298 Abdominal air sac of an adult chicken. Ventral view.

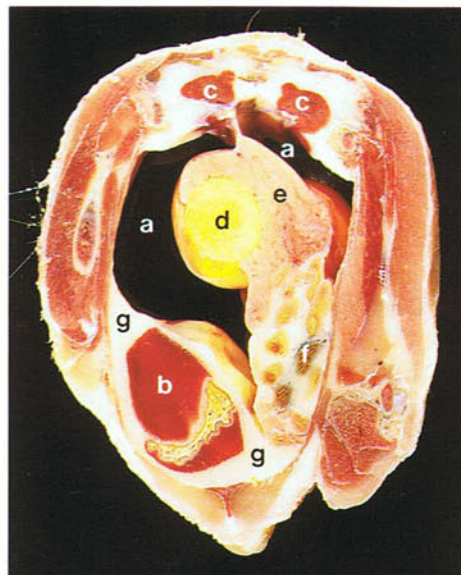
299



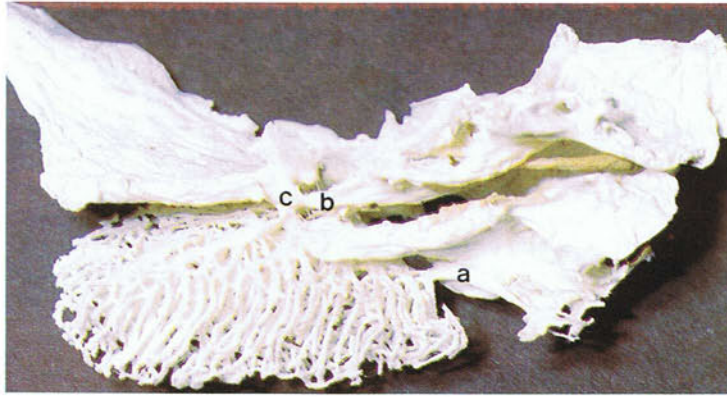
299 Inflated abdominal air sac of a Muscovy Duck (*Cairina moschata*). Ventral view.

300 Transverse section through the abdominal cavity of an adult chicken to show the position of the abdominal air sacs in relation to the other viscera. Caudal view. (a) Inflated abdominal air sacs; (b) gizzard; (c) kidneys; (d) ovary; (e) magnum; (f) intestines; (g) posthepatic septum.

300



301



301 Connections between the right lung and the air sacs of a chicken. Vinylite cast. Dorsal view. Where an air sac attaches to the lung is a collection of small holes which together form an ostium. There are two types of connection between the air sacs and lung. Direct connections are connections of the air sacs to either the primary bronchus or a secondary bronchus. Indirect connections are to parabronchi. The ostia of the sacs have both types of connec-

tions except for the cervical which has no indirect connections. In the photograph the following connections arising from the medioventral secondary bronchi are visible: the direct connection (a) to the cervical sac, the medial direct connection (b) to the clavicular sac, and the direct connection (c) to the cranial thoracic sac. The direct connections shown here to the clavicular and cranial thoracic sacs are by means of a shared canal.

302



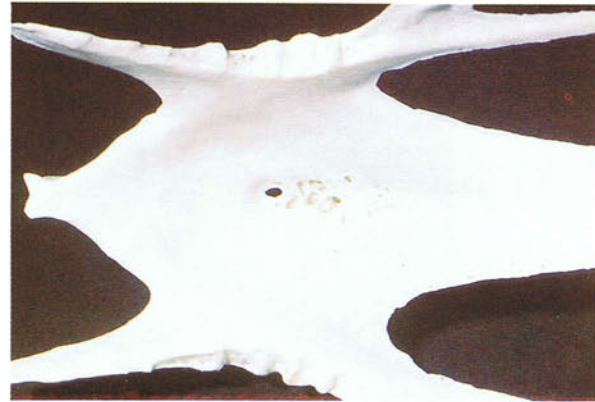302 Scanning electron micrograph of the internal surface of the abdominal air sac of a 12-week-old chicken. The epithelium consists of squamous cells.

However, close to the junction of the air sacs and lungs are groups of ciliated cuboidal and columnar cells. $\times 1140$.

303-305 Pneumatization of the skeleton. Extensions of the air sacs invade the medullary cavities of some of the bones of the skeleton. Usually the sacs enter the skeleton via small holes but in the sternum and humerus the foramina are quite distinct. The bones which are aerated vary between species and include the cervical and thoracic vertebrae, the synsacrum,

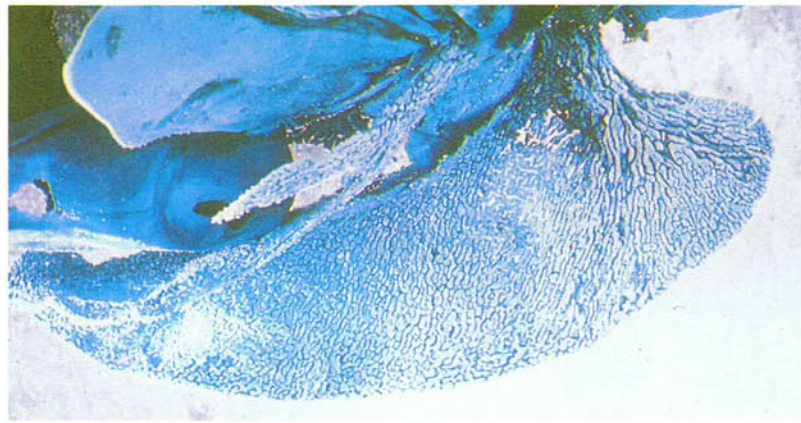
ribs, sternum (303 and 304), scapula, coracoid, humerus (305), femur and pelvis. Because of pneumatization, osteomyelitis associated with fracture of the bones can result in infection of the air sacs. Conversely, infection of the air sacs may also extend into the bones.

303 Sternum of a chicken. Dorsal view.

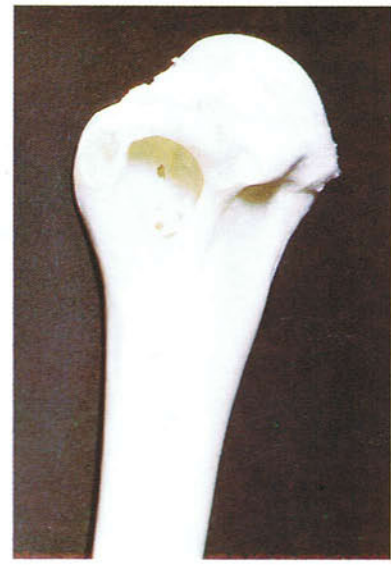

303

14



304 Pneumatization of the sternum of a pigeon. Latex cast. Lateral view.

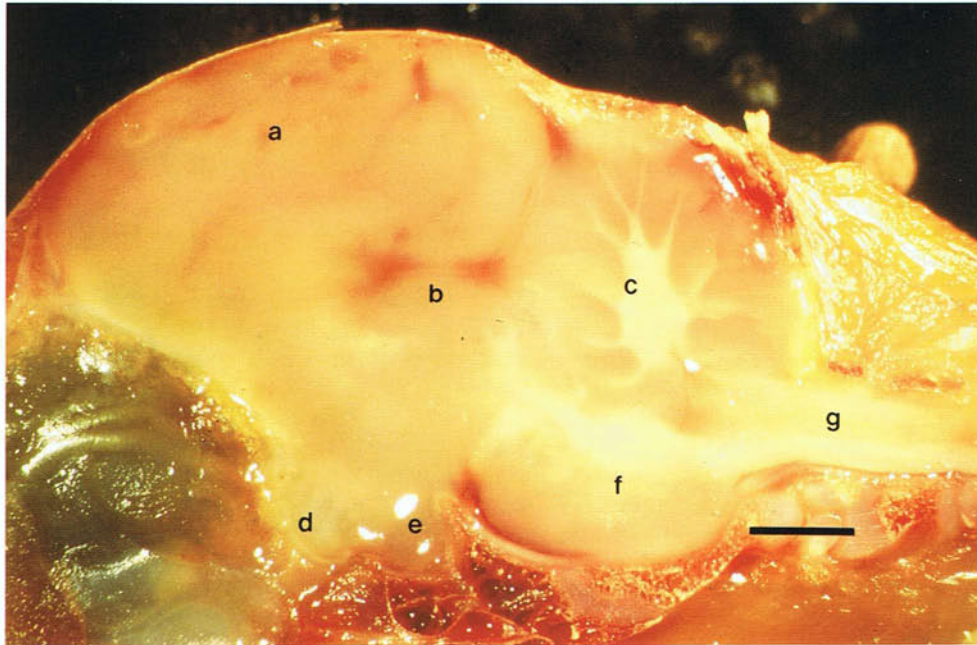


305

305 Proximal part of the humerus of a chicken.

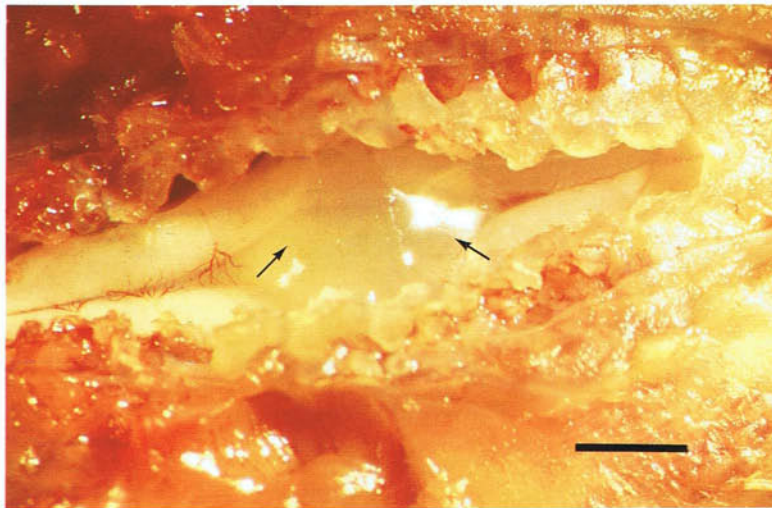
Central nervous system

306



306 Median section of the brain of a day-old chicken: (a) telencephalon; (b) optic tectum; (c) cerebellum; (d) optic chiasma; (e) pituitary; (f), pons; (g) medulla oblongata. (Scale, 2 mm)

307

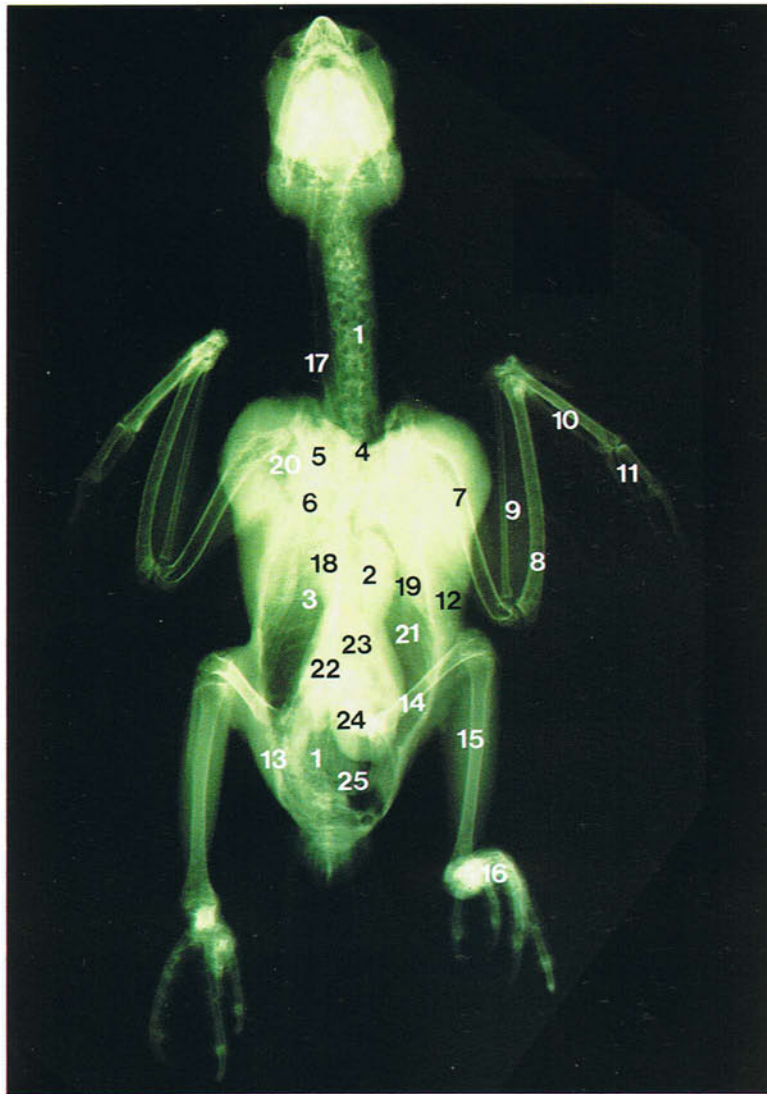


307 Lumbosacral enlargement of the spinal cord of a day-old-chicken. Dorsal view. Associated with the brachial and lumbosacral nerve plexuses are the cervical and lumbosacral enlargements of the spinal cord. In the dorsal midline of the lumbosacral enlargement is a cleft in which the gelatinous

body (arrows) lies. The gelatinous body encloses the central canal and consists of glial cells containing numerous glycogen granules. It is innervated by unmyelinated nerve fibres. Its function is unknown. (Scale, 2 mm)

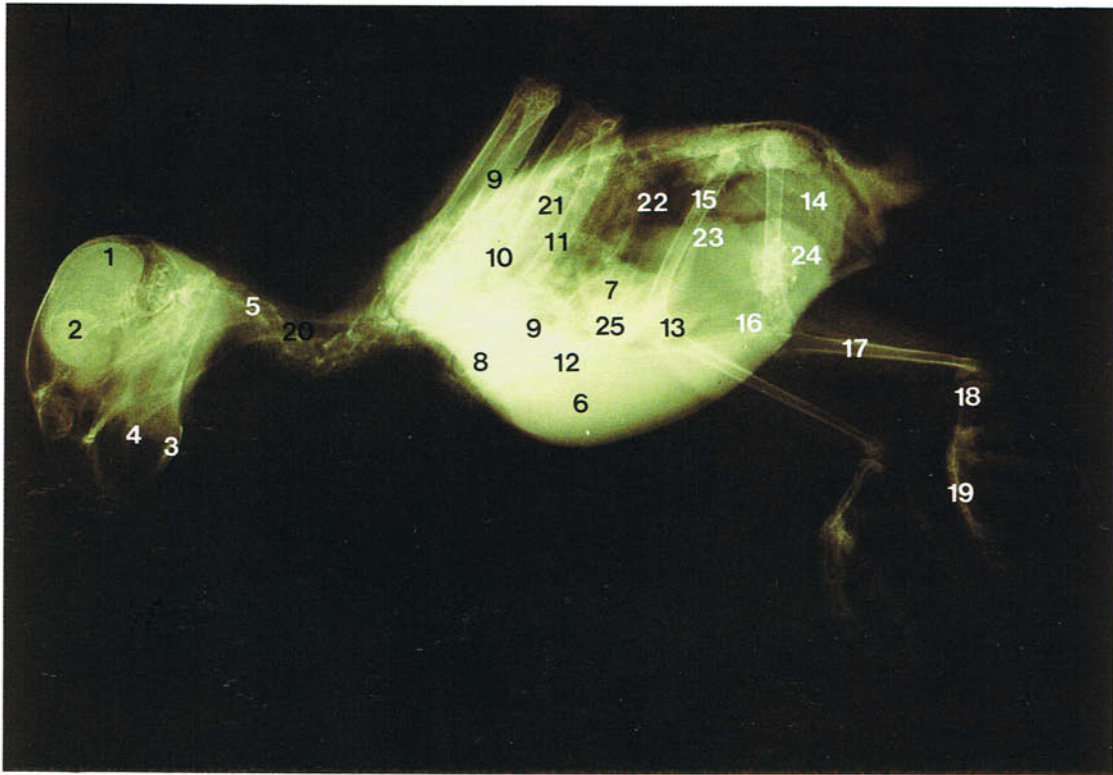
Radiographic anatomy

308



308 Ventrodorsal radiograph of a Gray Parrot (*Psittacus erithacus*): (1) vertebral column; (2) sternum; (3) rib; (4) furcula; (5) coracoid bone; (6) scapula; (7) humerus; (8) ulna; (9) radius; (10) carpometa-carpus; (11) digits; (12) breast muscles; (13) pelvis;

(14) femur; (15) tibiotarsus; (16) digits; (17) trachea; (18) heart; (19) lung; (20) clavicular air sac; (21) thoracic air sacs; (22) liver; (23) proventriculus; (24) gizzard; (25) intestines.



309 Lateral radiograph of a Gray Parrot (*Psittacus erithacus*): (1) cranial vault; (2) orbit; (3) mandible; (4) tongue; (5) vertebral column; (6) breast muscles; (7) ribs; (8) clavicle; (9) coracoid bone; (10) humerus; (11) ulna; (12) carpometacarpus; (13) digits;

(14) pubic bone; (15) femur; (16) patella; (17) tibio-tarsus; (18) tarsometatarsus; (19) digits; (20) trachea; (21) lung; (22) air sacs; (23) proventriculus; (24) gizzard; (25) heart and liver.

Further reading

Coles, B.H. (1985). *Avian Medicine and Surgery*. Blackwell, Oxford.

Dyce, K.M., Sack, W.O. and Wensing, C.J.G. (1987). *Textbook of Veterinary Anatomy*. Saunders, Philadelphia.

Evans, H.E. (1969). 'Anatomy of the budgerigar'. In: *Diseases of Cage and Aviary Birds* (M.L. Petrak, Ed.). Lea and Febiger, Philadelphia.

King, A.S. and McLelland, J. (Eds.) (1979-1989). *Form and Function in Birds*, Vols 1-4. Academic Press, London.

King, A.S. and McLelland, J. (1984). *Birds: Their Structure and Function*. Baillière Tindall, London.

Lowenstine, L.J. (1983). Avian anatomy and its relation to disease processes. In: Proceedings 1983 Annual Meeting of the Association of Avian Veterinarians, San Diego, pp.1-9.

McKibben, J.S. and Harrison, G.J. (1986). Clinical anatomy with emphasis on the Amazon Parrot. In *Clinical Avian Medicine and Surgery, including Aviculture* (G.J. Harrison and L.R. Harrison, Eds.). Saunders, Philadelphia.

Nickel, R., Schummer, A. and Seiferle, E. (1977). *Anatomy of the Domestic Birds* (Translation by W.G. Siller and P.A.L. Wight). Paul Parey, Berlin and Hamburg.

Index

Figures refer to page numbers

A

Abdominal cavity, 117
Adrenal glands, 73
Afterfeather, 27
Aggregated lymphoid nodule, 62
Air
– capillaries, 111
– sacculitis, 113
Air sacs, 113–114, 116–118
– abdominal, 117, 118
Albumen, 70, 71
Alula, 23
Alular digit, 42
Alveolar glands, 109
Antitrochanteric process, 36
Aorta, 91
Apteria, 21, 22, 25
Artificial insemination, 82
Arytenoid cartilage, 97
Atlanto-occipital joint, 35, 36
Atlas, 36
Atrioventricular valve, 105

B

B lymphocytes, 84
Barbs, 19, 21, 24, 25
Barbules, 19, 21, 24
Bastard wing, 42
– *see also* Alula
Beaks, 10, 12–13
– cutting in turkeys, 16
Bile duct, 59
Bills, 10–11
Bit, 17
Body temperature, 19
Bone formation, 45
Brachial plexus, 92
Brain, 120
Breast muscles, 40–41, 105
Breast region, 17
– pterylosis, 21
Breeding age, 67
Bristles, 30
Bronchi, 107–109
Brooding, 17
Budgerigar
– abdominal cavity, 62
– alula, 23
– beak, 12
– crop, 52
– feather colour, 28
– foot, 13
– moulting, 28
– oesophagus, 52
– oropharynx, 49

– prokinesis, 34
– uropygial gland, 18
– wing feathers, 28
Buoyancy, 19, 25
Bursa of Fabricicus *see* Cloacal bursa

C

C-cells, 93
Caecum, 63, 64
Cairina moschata, 117
Calamus, 19, 20
Calcium, 41, 70
Canary
– beak, 12
– caecum, 64
– clavicular sac, 113
– crop, 52
– duodenal loop, 58
– foot, 13
– kidneys, 75
– ovary, 67
– sexing, 80
– syrxinx, 102
Cannibalism, 16, 17
Carpal joint, 41
Carpometacarpus, 42
Caudal tibial vein, 46
Caudolateral process, 38
Central nervous system, 120
Cere, 12
Cervical spinal nerves, 93
Chalaza, 70, 71
Chicken
– beak, 10
– bone formation, 45
– breast muscles, 40
– breast region, 17
– bristle, 26
– central nervous system, 120
– cloacal bursa, 84, 94
– digestive system, 47, 48, 50–51, 53–55, 58–61, 64–65
– digits, 42
– egg tooth, 13
– feathers, 19–21, 25, 26, 27
– femur, 43
– foot, 14, 46
– heart, 90
– ischiadic nerve, 43
– leading edge of wing, 23
– moulting, 28
– ornamental appendages on head, 15
– pecten of eye, 32

– peritoneum and peritoneal cavities, 85–88
– prokinesis, 34
– pterylosis, 21, 22
– reproductive system, 66–67, 68, 72–75, 80–81
– respiratory system, 96, 98–101, 105–106, 109–113, 115–119
– skeleton, 33, 36–37, 38, 39, 41, 42, 46
– sternocoracoclavicular membrane, 39, 40
– subcutaneous injection site, 17
– thoracic inlet, 91, 92, 93
– thoracoabdominal cavity, 53
– thymus, 94
– urinary system, 75–79, 80–81
– uropygial gland papilla, 18
– yolk sac, 60
Choana, 47, 49, 96
Claws, 46
– clipping, 13
Cleidohyoid muscles, 100
Cleidotracheal muscle, 104
Cloaca, 80, 81, 83, 84
Cloacal
– bursa, 84, 94
– plexus, 77
Columella, 29
Comb, 15
Concha, 95
Coprodeum, 80, 83
Coprourodeal fold, 80
Coracoid, 38
Coronary groove, 89
Cranial
– cnemial crest, 44
– kinesis, 34
Cricoid cartilage, 97
Crop, 50–52
Crural bones, 44
Cuticle of gizzard, 55, 56, 57
Cygnus cygnus, 38
Cygnus olor, 57

D

Deep pectoral myopathy *see* Oregon muscle disease
Dewlap, 16
Diastema, 22
Digestive system, 47–65
– bile duct, 59
– crop, 50–52
– duodenum, 58, 59, 60

- gizzard, 56–57
- hyoid apparatus, 48
- ileum, 60, 62, 63
- jejunum, 60, 62
- large intestine, 63
- liver, 58–60
- neck, 50
- oesophagus, 50, 51, 52
- oral cavity, 47
- oropharynx, 47, 49
- palate, 47
- pancreas, 58, 59
- pancreatic duct, 59
- peritoneal ligaments, 65
- pharynx, 47
- small intestine, 61, 62
- spleen, 57
- stomach, 53–55
- Digits, 42, 46
- Diverticulum, 50
- Drinking, 47
- Drumstick *see* Crural bones
- Duck
 - aggregated lymphoid nodule, 62
 - bills, 10–11
 - choana, 96
 - cloaca, 83
 - crop, 52
 - foot, 13
 - lacrimal gland, 31
 - larynx, 97
 - lung, 105
 - moulting, 28
 - nasal gland, 30
 - nictitating membrane gland, 31
 - oesophagus, 52
 - phallus, 83
 - prokinesis, 34
 - respiratory system, 106–108
 - skull, 33, 34, 35
 - small intestine, 61
 - syrinx, 102, 103, 104
 - thoracic inlet, 89
 - tongue, 48–49
 - uropygial gland, 18
 - wing feathers, 22
- Ductus deferens, 72, 74, 81
- Duodeno-caecal ligament, 65
- Duodenohepatic ligament, 65
- Duodenum, 58, 59, 60

E

- Ear, 29
 - converts, 29
- Egg
 - candling, 71
 - laying, 71
 - pigmentation, 71
 - shell, 41
 - structure, 71
 - tooth, 13
- Ejaculation, 82
- Elbow joint, 41, 42

- Endoscope, 74
- Epididymis, 72, 73
- Extensor carpi radialis tendon, 23
- External features, 9–32
 - adult male duck, 10
 - beaks, 10, 12–13
 - bony orbit, 31
 - breast region, 17
 - ear, 29
 - eye, 30
 - feathers, 19–28
 - feet, 13–14
 - lacrimal gland, 30
 - nasal gland, 30
 - nictitating membrane gland, 31
 - ornamental appendages on head, 15–16
 - pecten of eye, 32
 - regions of body, 9
 - scleral ossicles, 30, 31
 - uropygial gland, 18
- Extramedullary myelopoiesis, 61
- Eye pecten, 32
- Eye-lashes, 26
- Eyeball, 30
- Eyelids, 30

F

- Feather follicle, 20
- Feathers, 19–28
 - afterfeather, 27
 - bristle, 26
 - colour, 28
 - contour, 19, 29
 - down, 25
 - filoplumes, 26
 - flight, 19, 20, 21, 24
 - insulation, 19, 24
 - musculature, 20
 - primary, 2
 - secondary, 22
 - tail, 24
 - trimming, 22
 - wing, 22–23, 28
- Feet, 13–14
 - chicken, 46
- Femur, 43
- Filoplumes, 26
- Finger test, 42
- Follicle, 66, 67
- Frontal bone, 35
- Furcula, 38

G

- Gall bladder, 58, 59
- Gape, 47
- Gas exchange, 111–112
- Gastric glands, 54
- Gastroduodenal ligament, 65
- Germ cells, 73
- Germinal disc, 70, 71
- Gizzard, 51, 53, 55, 105
 - contents, 57

- cuticle, 55–56, 57
- histology, 56
- Glottis, 96, 97
- Goblet cells, 109
- Gray Parrot, 121, 122
- Grit, 57

H

- Hardbills, 12
- Head, 9
 - ornamental appendages, 15, 16
- Heart, 89, 90, 105
- Hepatic
 - ligament, 85, 88
 - peritoneal cavity, 85
 - portal vein, 79
- Herbst corpuscles, 26
- Hock *see* Tarsal region
- Horizontal septa, 114, 115
- Humerus, 39, 119
- Hyoid apparatus, 48

I

- Ileocaecal ligament, 65
- Ileocaecorectal junction, 63
- Ileum, 60, 62, 63
- Incubation, 71
 - patches, 17
- Infraorbital sinus, 96
- Insulation, 24, 27
- Integument, 9–32
- Intercostal nerves, 106
- Internal carotid arteries, 91
- Interstitial cells, 73
- Intestinal
 - nerve, 79
 - peritoneal cavity, 85
- Intestines, 105
- Intramuscular injection, 43
- Intravenous injection, 23, 46
- Ischiadic nerve, 43, 77
- Isthmus, 53

J

- Jejunum, 60, 62
- Jugular veins, 92

K

- Keel, 38, 105
- Kidneys, 75–76, 105
 - blood supply, 78
 - excretion, 76
- Knee joint, 43
- Koilin layer, 55, 56

L

- Lacrimal gland, 31
- Large intestine, 63
- Laryngeal mound, 96
- Larynx, 97, 98
- Laying, 71
- Lead weights, 57
- Leg, 9

Liver, 58–60, 105
Lobes, 15
Long bone anatomy, 41
Lungs, 105, 106–118
Lymph nodes, 94

M

Magnum, 68, 69, 70
Manus, 42
Marek's disease, 43
Meckel's diverticulum *see* Vitelline diverticulum
Median nasal septum, 96
Medullary bone, 41, 70
Mesenteric veins, 79
Moulting, 28
– ovary during, 68
Multicellular gland of oviduct, 69
Muscovy duck, 117
Mute Swan, 57
Myoglobin, 40, 55

N

Narial bristles, 26
Nasal
– cavity, 95–96
– concha, 95, 96
– gland, 30
– mucosa, 96
– septum, 96
Natal down feathers, 25
Neck, 50, 89–94
Neopulmo, 111
Nephron, 78
Nictitating membrane, 30
–gland, 31
Nostril, 95
Notarium, 36

O

Oblique septum, 85, 88, 114, 115
Occipital condyle, 35, 36
Oesophageal tonsil, 52
Oesophagus, 50, 51, 52, 105
Oocyte, 66, 67
Operculum, 95
Oral cavity, 47
Orbit, bony, 31
Oregon muscle disease, 40
Ornamental appendages on head
– chicken, 15
– turkey, 16
Oropharynx, 47, 49, 96
Ossification of tendons, 45
Osteomyelitis, 119
Ovary, 66–68, 70
– juvenile, 75
Oviduct, 66, 68–70, 80
– right, 72
– ventral ligament, 70
Ovulation, 66
Ovum formation, 68, 70

P

Palaeopulmo, 111
Palate, 47
Pancreas, 59
Pancreatic duct, 59
Parabronchi, 108, 110, 112, 118
Parakeet, 34
Parrot
– bill tip organ, 11
– foot, 13
– prokinesis, 34
– sexing, 74
Pecten of eye, 32
Pectoral
– crest, 39
– muscle, 40
Pelvic girdle, 42
Peritoneal
– cavities, 85–88
– ligaments, 65
Peritoneum, 85–88
Pessulus, 100, 103
Phallus, 81, 82, 83
Pharyngo-tympanic tube, 29
Pharynx, 47
Pheasant
– artificial insemination, 82
– prevention of cannibalism, 17
Pigeon
– beak, 12
– breast muscles, 41
– caecum, 64
– caudolateral process, 38
– crop, 52
– flight feathers of tail, 24
– liver, 59
– moulting, 28
– rhynchokinesis, 34
– small intestine, 62
– syrinx, 102
Pleural cavity, 106
Pneumatization of skeleton, 35, 41, 119
Posthepatic septum, 85, 86–88
Powder down feathers, 25
Preen gland *see* Uropygial gland
Proctodeum, 80, 83
Prokinesis, 34
Propatagium, 23
Proventriculus, 53, 54, 105
Psittacus erithacus, 121, 122
Pterylosis, 21–22
Pudendal nerve plexus, 77
Pulmonary trunk, 91
Pygostyle, 37

Q

Quail eggs, 71
Quill *see* Calamus

R

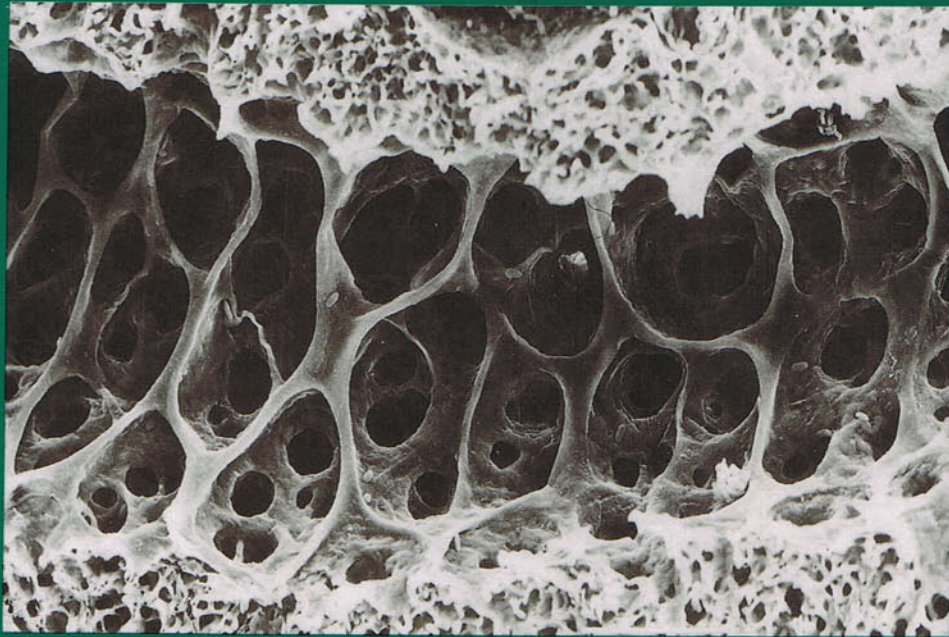
Rachis, 19, 20, 21, 24, 25

Radiography, 121–122
Rectum, 63
Red jungle fowl, 110
Remak's nerve, 79
Remiges, 22
– budgerigar, 28
Renal portal system, 78
Respiratory system, 95–119
– bronchi, 108–109
– larynx, 97, 98
– lung 106–118
– nasal cavity, 95–96
– trachea, 98–99
Retrices, 24
Rhamphotheca, 10
Rhynchokinesis, 34
Ribs, 37
Ricti, 15
Ringed Turtle Dove, 109

S

Sacral nerve plexus, 77
Salivary glands, 47
Scapula, 38
Scleral ossicles, 30, 31
Sebum, 18
Semibristle, 26
Seminiferous tubules, 72, 73
Semiplume, 24
Septa of air sacs, 114
Sexing, 42, 80, 81
– by endoscopy, 74
Shell, 70
Skeleton, 33–46
– breast muscles, 40–41
– crural bones, 44
– feet, 46
– femur, 43
– forearm, 41
– humerus, 39
– long bone anatomy, 41
– manus, 42
– pelvic girdle, 42
– sternocoracoclavicular membrane, 39
– sternum, 38
– tarsal region, 44, 45
– thoracic girdle, 38
– tibial cartilage, 45
– triosseal canal, 39
– vertebral column, 36–37
Skin
– and crop, 50
– incubation patch, 7
– vascularity in chickens, 17
Skull
– duck, 33, 34, 35
– Parakeet, 34
– pneumatization, 35
Small intestine, 61, 62
Snood, 16
Softbills, 12

- Sound production, 100
 - Spermatic fossulae, 82
 - Spermatozoa, 74, 82
 - Spleen, 57
 - Spur, 14
 - Sternocoracoclavicular membrane, 39, 40
 - Sternotracheal muscles, 99
 - Sternum, 38, 105
 - pneumatization, 119
 - Stomach, 53–55
 - Sterptopelia risoria*, 109
 - Supracoracoid muscle, 40
 - Supraduodenal loop, 62
 - Swallowing, 47
 - Synsacrum, 36
 - kidney position, 75
 - Syringeal
 - bulla, 102, 103
 - cartilage, 100
 - muscles, 100, 102
 - Syrinx, 99, 100–104
 - clavicular air sac, 113
- T**
- T lymphocytes, 94
 - Tarsal region, 44, 45
 - Tarsometatarsal articular surfaces, 45
 - Tendon ossification, 45
 - Testes, 72–73, 105
 - Thoracic
 - cage, 37
 - girdle, 38
 - Thoracic inlet, 89, 92, 93
 - arteries, 91
 - blood vessels, nerves and endocrine glands, 93
 - lymph nodes, 94
 - Thoracoabdominal
 - cavity, 116
 - viscera, 105
 - Thorax, 89–94, 105
 - Thymus, 94
 - Thyroid gland, 92, 93
 - Tibial cartilage, 45
 - Tongue, 47, 48–49
 - Trachea, 98, 100
 - Tracheal
 - cartilage, 99
 - muscles, 104
 - Tracheolateral muscle, 99, 100, 102
 - Triosseal canal, 39, 40
 - Trunk skeleton, 37
 - Tumescence, 81, 82, 83
 - Tunica albuginea, 73
 - Turkey
 - air sacs, 113
 - artificial insemination, 82
 - beak cutting, 16
 - ornamental appendages on head, 16
 - Tympanic membrane, 29
 - Tympaniform membrane, 100, 102
 - Tympanum, 100, 103, 104
- U**
- Unicellular glands of oviduct, 69
 - Ureter, 76, 81
 - Urine, 81
 - Urodeum, 80, 81, 83
 - Urogenital ducts, 81
 - Urogenital system, 66–84
 - cloaca, 80
 - ductus deferens, 74, 81
 - kidneys, 75–76, 78
 - ovary, 66–68
 - oviduct, 66, 68–70, 72, 80
 - phallus, 81, 83
 - sacral nerve plexus, 77
 - testes, 72–73
 - ureters, 76
 - urogenital ducts, 81
 - Uroproctodeal fold, 80
 - Uropygial gland, 18, 105
 - Uterus, 69, 70
- V**
- Vagina, 69
 - Vane, 19, 21, 25
 - Vent, 80, 81, 83
 - Ventral mesentery, 85, 86
 - Ventricles, 90
 - Vertebral column, 36–37
 - Vestibular window, 29
 - Vitelline diverticulum, 61
- W**
- Water
 - conservation, 81
 - reabsorption, 63
 - Wattles, 15
 - Waxing, 25
 - Whooper Swan, 38
 - Wing, 9
 - Wishbone *see* Furcula
 - Wrist joint, 42
- Y**
- Yolk sac, 60



Interest in avian structure and function has grown with the increasing importance of birds as food producers, models in biological research, and as pets. **A Colour Atlas of Avian Anatomy** provides an introduction to the subject which will meet the needs of veterinarians, meat inspectors and research workers, as well as those of ornithologists.

A pictorial review of the organ systems includes material from each of the major domesticated species – domestic fowl, turkey and duck, together with quail and pigeon – as well as aviary species, such as the canary and budgerigar.

All of the illustrations are of fresh, unfixed material, and many are photographs taken through a dissecting microscope, and are of such clarity and detail that they will be instructive both to the beginner and to the experienced anatomist.

ISBN 0-7234-1575-7



9 780723 415756